

A Rare Case of Spontaneous Heterotopic Pregnancy at 12 weeks of Gestation Following Natural Conception With Literature Review

Fei Wang^{1,*}, Yuting Xu^{1,*}, Xin Dong², Pei Jiang³, Qing-Qing Yu⁴ 

¹Department of Gynecology, Jining No.1 People's Hospital, Jining, People's Republic of China; ²Department of Ultrasonography, Jining No.1 People's Hospital, Jining, People's Republic of China; ³Translational Pharmaceutical Laboratory, Jining NO.1 People's Hospital Jining, People's Republic of China; ⁴Clinical Research Center, Jining NO.1 People's Hospital, Jining, People's Republic of China

*These authors contributed equally to this work

Correspondence: Qing-Qing Yu, Clinical Research Center, Jining No.1 People's Hospital, Jining, People's Republic of China, 272011, Email yuqingqing_lucky@163.com; Pei Jiang, Translational Pharmaceutical Laboratory, Jining No.1 People's Hospital, Jining, 272011, People's Republic of China, Email jiangpeicsu@sina.com

Background: Spontaneous heterotopic pregnancy is an uncommon and possibly serious problem characterized by maternities at unique implantation sites, with only one occurring in the intrauterine cavity. Its incidence is approximately 1 in 30,000 natural pregnancies, posing significant threats to maternal health. The complexity of clinical and laboratory findings complicates its diagnosis, necessitating a high index of suspicion for prompt intervention.

Case Presentation: We reported the case of a 36-year-old woman diagnosed with heterotopic pregnancy at 12 weeks of gestation following spontaneous conception, who presented with severe abdominal pain. Initial beta-human chorionic gonadotropin (β -hCG) levels were 57,278.00 mIU/mL. Transvaginal ultrasound (TVUS) revealed a single live fetus in the uterus, estimated at 12 weeks and six days, alongside a thick-walled cystic structure in the right ovary and an irregular hypoechoic mass inferior to the right ovary. An urgent laparoscopic salpingectomy was performed under general anesthesia, revealing a distended right fallopian tube (3.5 cm) with a thickened appearance, bluish-purple discoloration, and a 2 mm rupture with active bleeding surrounded by clots. Histopathological examination confirmed ectopic pregnancy. Postoperative β -HCG levels were 49,213 mIU/mL and 57,577 mIU/mL on the second and third days, respectively.

Conclusion: Clinicians should maintain vigilance for heterotopic pregnancy, especially in the absence of infertility treatments or known risk factors. Lower quadrant abdominal or pelvic pain should prompt consideration of heterotopic pregnancy, as the presence of an intrauterine pregnancy does not exclude a concurrent ectopic pregnancy.

Keywords: ectopic pregnancy, heterotopic pregnancy, laparoscopy, spontaneous pregnancy

Introduction

Heterotopic pregnancy is a rare condition characterized by the simultaneous occurrence of an intrauterine pregnancy and an ectopic pregnancy.¹ The underlying factor for this phenomenon may be attributed to an ovulatory dysfunction or a variation in the migration rates of the two embryos. This could occur as a result of a delay in the fertilized egg being captured by the fallopian tube. This pathological condition is estimated to occur in approximately 1 in 30,000 pregnancies.² However, with the increasing use of assisted reproductive technologies and ovulation-stimulating medications, the incidence of heterotopic pregnancy has risen to about 1 in 3,900 pregnancies.^{3,4} The risk factors associated with heterotopic pregnancy closely resemble those seen in ectopic pregnancies. These include smoking, a past occurrence of ectopic pregnancy, history of inflammatory pelvic disease, sexually transmitted infections (notably Chlamydia), surgical procedures involving the fallopian tubes, previous abdominal surgeries, endometriosis, infertility treatments, and certain contraceptive methods.⁵ Patients with heterotopic pregnancy often present with symptoms such as a history of

amenorrhea, abdominal pain, the presence of an abdominal mass, and vaginal bleeding. Due to the rarity of this condition, there are currently no universally accepted guidelines for its management. Currently, transvaginal ultrasound (TVUS) and 2D/3D ultrasound imaging play crucial roles in the initial assessment and diagnosis of heterotopic pregnancy.^{6,7} TVUS is particularly advantageous in early pregnancy evaluation due to its higher resolution and ability to provide clearer images of pelvic structures compared to transabdominal ultrasound. Meanwhile, 2D and 3D ultrasound techniques enhance the visualization of the anatomical features of both intrauterine and ectopic pregnancies. However, the low sensitivity of these imaging modalities can still lead to challenges in early detection, resulting in missed or misdiagnosed cases.⁸ Surgical intervention is typically required to manage heterotopic pregnancy, with the primary goal of removing the ectopic pregnancy while preserving the intrauterine pregnancy.^{9,10} This case report presented a unique instance of spontaneous intrauterine pregnancy complicated by the rupture of a right fallopian tube ectopic pregnancy at 12 weeks of gestation, along with a comprehensive review of the relevant literature.

Case Presentation

A 36-year-old woman presented for her first antenatal visit at a local primary care hospital at 7 weeks and 4 days of gestation, according to her own timeline. An ultrasound examination revealed an intrauterine pregnancy with no abnormalities in the bilateral adnexa. The pregnancy was a result of natural conception, and she had no previous risk factors for ectopic pregnancy. Ten years prior, she had a healthy vaginal delivery, and her previous pregnancies were uneventful. She reported a history of irregular menstruation, with cycles ranging from 25 to 45 days. She denied any significant medical history, previous surgeries, and did not smoke or drink alcohol. There was no notable family history of pelvic disease.

Throughout her pregnancy, serial TVUS consistently indicated an intrauterine pregnancy. However, at 12 weeks of gestation, the patient was admitted due to sudden severe abdominal pain. Prior to admission, she experienced mild abdominal discomfort, which she initially attributed to normal pregnancy symptoms. She was advised to monitor her condition and seek medical attention only if her symptoms worsened. Unfortunately, as her condition progressed to severe abdominal pain, she presented to the hospital. On admission, her temperature was 36.5°C, heart rate was 76 beats per minute, and blood pressure was 93/70 mmHg. Physical examination revealed the patient was alert but pale, and her abdomen was rigid with signs of peritoneal irritation. A gynecological examination showed a smooth external genitalia and vaginal mucosa, with a clean cervix and uterus consistent with a 12-week size pregnancy; however, there was marked tenderness in the bilateral adnexa. An emergency ultrasound conducted at Jining No.1 People's Hospital revealed a viable intrauterine pregnancy with a fetal heart rate of 166 beats per minute and a crown-rump length of 6.6 cm, corresponding to a gestational age of 12 weeks and 6 days (Figure 1). An accumulation of free fluid measuring 8.7 cm × 7.5 cm × 5.4 cm, corresponding to an estimated volume of approximately 352 cm³, was noted in the rectouterine pouch. A thick-walled cystic structure in the right ovary measured 2.3 cm × 2.0 cm × 1.9 cm, with an estimated volume of about

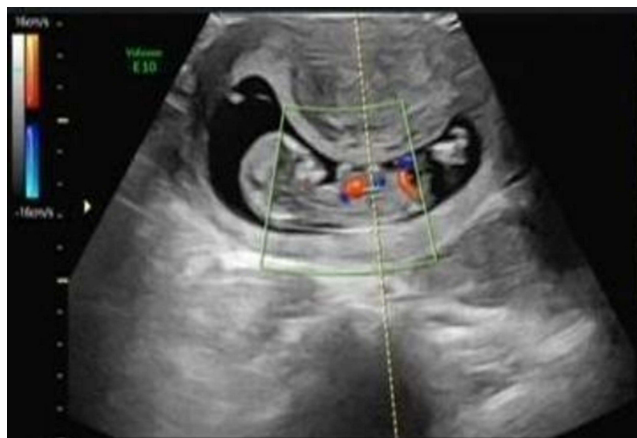


Figure 1 Ultrasonography image of the uterus showing an intrauterine gestation.

8.7 cm³. Additionally, an irregular hypoechoic area beneath the right ovary measured 4.3 cm × 3.2 cm × 2.8 cm, corresponding to an estimated volume of approximately 38.5 cm³ (Figure 2). Additionally, fluid collections were noted in both the right and left pelvic cavities as well as in the hepatorenal recess, suggesting a possible corpus luteum cyst or hematoma. Laboratory tests revealed a white blood cell count of $19.5 \times 10^9/L$, hemoglobin of 113 g/L, hematocrit of 33.2%, and a beta-human chorionic gonadotropin (β -hCG) level of 57,278.00 mIU/mL.

Given the suspicion of pelvic and abdominal bleeding, the hospital quickly activated a green channel for admission. The surgical team decided to proceed with an urgent diagnostic laparoscopy. Preoperative assessments were within normal limits. After being informed of the risks, the patient signed the consent form for surgery and was taken to the operating room. During the procedure, approximately 1200 cubic centimeter of non-echoic fluid was found in the rectouterine pouch, and the uterus was consistent with a 12-week pregnancy. The right fallopian tube was significantly dilated, measuring 3.5 cm in length, with thickened walls measuring $4.0 \times 3.0 \times 3.0$ cm and an estimated volume of approximately 36.0 cm³. It exhibited a bluish-purple appearance with a 2 mm rupture site and active bleeding. The diagnosis was a ruptured right ectopic pregnancy causing hemorrhagic shock at an early stage of pregnancy. A right salpingectomy was performed, and the excised tissue was sent for pathological examination. The surgical procedure was completed without complications.

Pathological analysis of the excised fallopian tube revealed structures consistent with an embryo. Postoperative β -hCG levels on the second and third days were 49,213 mIU/mL and 57,577 mIU/mL, respectively. On the second postoperative day, laboratory results showed a white blood cell (WBC) count of $7.85 \times 10^9/L$, red blood cell (RBC) count of 3.02 million/ μ L, and hemoglobin of 95 g/L. The patient received blood transfusions and progesterone support (200 mg/day intravaginally) to support fetal health, and her postoperative course remained stable.

She was discharged on the fourth postoperative day without any complications. During follow-up, she chose to undergo an elective termination of pregnancy at 14 weeks gestation for personal reasons.

Discussion

Heterotopic pregnancy refers to the simultaneous presence of a pregnancy within the uterus and another pregnancy outside the uterus.¹¹ The condition results from the simultaneous implantation of multiple embryos, which are released from the ovaries and mature in the uterus. While heterotopic pregnancy is a rare and potentially life-threatening complication, it occurs in approximately 1 in 30,000 natural conceptions.¹² The risk factors for heterotopic pregnancy are similar to those of ectopic pregnancy and include adhesions, intrauterine devices, pelvic inflammatory illness, history of ectopic pregnancy, assisted reproductive technologies, and ovarian hyperstimulation syndrome.⁵ However, as demonstrated in the case we reported, heterotopic pregnancy can also occur spontaneously, without the presence of these risk

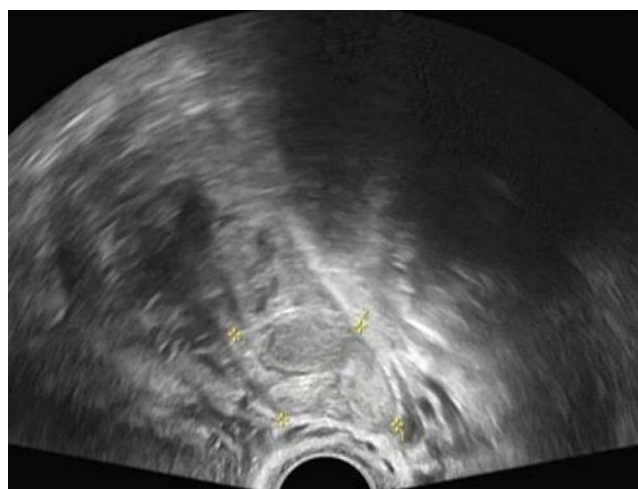


Figure 2 An uneven hypo echo with a range of 4.3×3.2×2.8cm below the right ovary.

factors, making it an exceptionally rare and difficult condition to diagnose. In our case, menstrual irregularities were noted, which may be linked to underlying endocrine disturbances contributing to abnormal ovulation.

A review of the literature on heterotopic pregnancies, involving the coexistence of an ectopic pregnancy and a viable intrauterine pregnancy, was conducted. The method was referred according to a previous study.¹³ Using the search terms “spontaneous heterotopic pregnancy”, “outcomes” “diagnosis” ‘management’ in PubMed, Medline, and Google Scholar from 2020–2024, a total of 141 results were generated. After carefully analyzing all titles and abstracts, only studies in English, describing cases of heterotopic pregnancies with a coexisting viable intrauterine pregnancy, were included. A total of 25 papers reporting heterotopic pregnancy with intrauterine fetus were identified.^{4,10,14–36} Detailed information, such as the demographics, clinical presentation, diagnostic methods, management strategies, and outcomes, was presented in Table 1. The main presenting symptoms were abdominal or pelvic pain in 24 cases and vaginal bleeding in 10 cases, only one case presented no symptoms at all, which illustrated the diverse presentations of heterotopic pregnancy. This finding was consistent with our own case, where the patient presented with severe abdominal pain at 12 weeks of gestation. The variability in symptom presentation emphasized the diagnostic challenge of heterotopic pregnancy, especially when symptoms overlap with other pregnancy-related complications such as threatened miscarriage or ruptured corpus luteum cysts.

Table 1 Included Articles in the Literature Review

Authors and References	Publish Year	Ages (Years)	Parity	GA at Diagnosis (Weeks+Days)	Pregnancy Complications	Treatment	Outcome
Černiauskaitė M et al ¹⁴	2020	28	G1P0	7	Weakness, pain in lower abdomen and spotting bleeding	LS	Vaginal
Maharjan S et al ¹⁵	2021	28	G1P0	8	Lower abdomen pain	LS	C/S
Momtahan M et al ¹⁶	2021	31	G1P0	36+4	Labor pain, severe bleeding	C/S +skin incision extended to T shape	C/S
Ouafidi B et al ¹⁷	2021	32	G3P3	9+2	Acute pelvic pain	Laparotomy	Vaginal
Lober R et al ¹⁸	2024	36		6	Severe acute lower abdominal pain	Laparoscopy	Vaginal
Valencia V et al ⁴	2024	37	G3P1	7	Vaginal bleeding and lower abdominal pain	LS	(-)
Khoulood M et al ¹⁹	2024	36	G5P3	12	Persistent pelvic pain and abnormal vaginal bleeding	Laparotomy	Induced abortion
Abdelmonem AH et al ²⁰	2021	38	G5P4	9+5	Lower abdominal pain	LS	(-)
Kathopoulos N et al ²¹	2023	26	G2P1	17	Lower abdominal pain	Laparotomy	C/S
Maree G et al ²²	2022	37	G7P6	12	Lower abdomen and intermittent Vaginal bleeding	Laparotomy	Induced abortion
Aziz M et al ²³	2020	28	G2P1	7	Abdominal, back and pelvic pain, dyspnea, chest pressure, chills, sweats, cough, rhinorrhea	LS	Induced abortion
Tariq A et al ²⁴	2024	34	G4P3	6+2	Delayed period	Conservative treatment	C/S
Soecki G et al ²⁵	2024	26	G2P1	9+6	Nausea and abdominal pain	Drug therapy	Death due to misdiagnose
Dubbewar A et al ²⁶	2020	40	(-)	12	Abdominal pain	Salpingectomy	Induced abortion
Murewanhema G et al ²⁷	2020	34	G3P2	12	Bleeding vaginally, mild backache, abdominal pain	Laparotomy	(-)
Maduako KT et al ²⁸	2022	25	G4P2	6	Acute abdominal pain, vomiting	LS	C/S
Kajdy A et al ²⁹	2021	24		26	Upper abdominal pain	Salpingectomy	C/S
Julien A et al ³⁰	2023	34	G3P2	8+1 & 5+4	Abdominal pain	Laparoscopy	(-)
Bouab M et al ¹⁰	2024	28	G1P0	8	Acute pelvic pain, vaginal bleeding	Laparotomy	(-)
Ntounis T et al ³¹	2021	43	G4P3	7	Abdominal pain and sudden-onset Vaginal bleeding	Laparotomy	C/S

(Continued)

Table 1 (Continued).

Authors and References	Publish Year	Ages (Years)	Parity	GA at Diagnosis (Weeks+Days)	Pregnancy Complications	Treatment	Outcome
Dipanda AN et al ³²	2021	22	G3P1	8	Pelvic + abdominal + shoulder pain	Salpingectomy	Spontaneous abortion
Fomukong NH et al ³³	2021	32	G3P2	7	Acute abdominal pain	LS	(-)
Nkurunziza C et al ³⁴	2020	34	G6P2	18	Abdominal pain, distended abdomen	Subtotal hysterectomy	Induced abortion
Cucinella G et al ³⁵	2021	25	G2P0	5+4	Abdominopelvic pain and vaginal bleeding	Salpingectomy	C/S
Nguyen KP et al ³⁶	2022	27	G4P1	5	Acute abdominal pain and vaginal bleeding	LS	Abortion

Abbreviation: LS, laparoscopic salpingectomy; C/S, cesarean section; GA, gestational age; (-), missing.

The diagnosis of heterotopic pregnancy was often delayed, as it was difficult to distinguish from other conditions, such as early miscarriage or uncomplicated intrauterine pregnancies.³⁷ In the 25 cases reviewed, only 14 cases (56.00%) were diagnosed during the period of five to eight weeks of pregnancy, 3 cases (12.00%) were diagnosed between nine and ten weeks, and 8 cases (32.00%) were diagnosed after the eleventh week. The delayed diagnosis of heterotopic pregnancy, especially in spontaneous cases, highlighted a critical challenge in clinical practice. Imaging studies, particularly TVUS, were critical in identifying both the intrauterine pregnancy and the ectopic mass in these cases. However, TVUS has limitations in diagnosing heterotopic pregnancy, particularly when the intrauterine pregnancy is well visualized, potentially obscuring the ectopic pregnancy. It has been reported that TVUS has a sensitivity of 92.4% and a specificity of 100%.³⁸ According to a comprehensive assessment of the literature conducted between 2005 and 2010, up to 33% of heterotopic cases had previously had a routine sonography, which resulted in misplaced confidence and a misdiagnosis.² This highlighted the need for heightened clinical awareness and the use of advanced imaging techniques, such as 2D/3D ultrasound, which can offer clearer delineation of both the intrauterine and ectopic pregnancies. In addition to imaging, monitoring the patient's serum β -hCG levels may provide helpful diagnostic clues. However, while elevated β -hCG levels are often associated with an intrauterine pregnancy, they can also be elevated in ectopic pregnancies, making the interpretation of β -hCG levels alone insufficient for a definitive diagnosis of heterotopic pregnancy. In our case, the patient had a β -hCG level of 57,278 mIU/mL at the time of presentation, which was consistent with the intrauterine pregnancy, but it also indicated the possibility of an ectopic pregnancy. As such, while β -hCG testing can support the diagnosis, it is not a standalone tool, and the use of TVUS or 2D/3D ultrasound remains paramount in clinical practice.

The management approaches for heterotopic pregnancy varied widely across the studies, with several different approaches employed depending on the patient's clinical condition, the stage of pregnancy, and the location of the ectopic pregnancy.³⁶ Surgical management is the most common intervention, with a variety of procedures utilized to treat the ectopic pregnancy and preserve the intrauterine pregnancy. In some cases, a salpingectomy was performed to remove the ectopic pregnancy, while others chose salpingostomy in an attempt to preserve the fallopian tube and the possibility of future fertility. The decision to terminate the intrauterine pregnancy was generally based on maternal health concerns, the size of the ectopic pregnancy, and the risks associated with carrying both pregnancies to term. Certainly, if there are no symptoms of abdominal bleeding, a conservative approach can be safely adopted, and the patient can be closely monitored.¹ In our study, given the diagnosis of a ruptured ectopic pregnancy with active bleeding and the presence of a viable intrauterine pregnancy, an urgent surgical intervention was necessary. We opted for laparoscopic salpingectomy under general anesthesia, which required the complete removal of the affected tube to ensure the patient's safety and effectively control the hemorrhage. Following the surgical procedure, the patient was closely monitored and received progesterone support (200 mg/day intravaginally) to support fetal health. Meanwhile, pathological examination and serial measurement of β -hCG levels were performed, confirming the resolution of the ectopic pregnancy while the intrauterine pregnancy continued to progress normally. The patient's recovery was uneventful, and no major complications, such as

infection or excessive bleeding, were observed. Postoperatively, the patient was advised to continue regular follow-up visits to ensure the ongoing viability of the intrauterine pregnancy.

Conclusion

This case of heterotopic pregnancy is notable not only because it involves a viable intrauterine pregnancy but also due to the absence of typical risk factors associated with ectopic implantation. When a pregnant woman presents with acute abdominal pain, a comprehensive evaluation is essential. We emphasize that all pregnant patients with clinical signs such as abdominal pain, free fluid in the Douglas pouch, hypovolemic shock, or those classified as high-risk should undergo a thorough assessment of the adnexa. A diagnosis of ectopic pregnancy must be strongly considered, even in the presence of a confirmed intrauterine pregnancy. It is crucial to understand that confirmation of an intrauterine pregnancy through clinical evaluation or ultrasound does not rule out the possibility of a concurrent ectopic pregnancy. Timely surgical intervention is critical for the effective management of heterotopic pregnancies and can significantly improve outcomes for both the mother and the newborn.

Ethical Approval

This study was approved by the ethics committee of Jining No.1 People's Hospital and we have obtained institutional approval from the hospital to publish this case in the journal.

Declaration of Patient Consent

Written informed consent was obtained from the patient for publication of this case report and any accompanying images. The patient signed an informed consent statement.

Disclosure

None of the authors declare any conflict of interest for this work.

References

- Młodawski J, Kardas-Jarząbek A, Młodawska M, Świercz G. Conservative management of heterotopic pregnancy: a case report and review of literature. *Am J Case Rep.* 2023;24:e940111. doi:10.12659/AJCR.940111
- Talbot K, Simpson R, Price N, Jackson SR. Heterotopic pregnancy. *J Obstet Gynaecol.* 2011;31(1):7–12. doi:10.3109/01443615.2010.522749
- Ljuca D, Hudić I, Hadzimehmedović A. Heterotopic pregnancy in natural conception – our initial experience: case report. *Acta Clin Croat.* 2011;50(2):249–252.
- Valencia V, Worcester RM, Abedi AS, Majewski E, Pham V, Eliz N. Spontaneous heterotopic pregnancy: a case report of a potentially life-threatening condition. *Cureus.* 2024;16(8):e67488. doi:10.7759/cureus.67488
- Oancea M, Ciortea R, Diculescu D, et al. Spontaneous heterotopic pregnancy with unaffected intrauterine pregnancy: systematic review of clinical outcomes. *Medicina.* 2020;56(12). doi:10.3390/medicina56120665
- Avitabile NC, Kaban NL, Siadecki SD, Lewiss RE, Saul T. Two cases of heterotopic pregnancy: review of the literature and sonographic diagnosis in the emergency department. *J Ultrasound Med.* 2015;34(3):527–530. doi:10.7863/ultra.34.3.527
- Le DN, Nguyen PN. Successful management of interstitial heterotopic pregnancy by fetal reduction using ultrasound-guided laparoscopy. *J Minim Invasive Gynecol.* 2023;30(8):606–608. doi:10.1016/j.jmig.2023.03.021
- Karkee R, Sharma A, Dangal B. Heterotopic Pregnancy: a Challenge in Early Diagnosis. *J Nepal Health Res Counc.* 2019;17(3):413–415. doi:10.33314/jnhrc.v17i3.1983
- Esterle J, Schieda J. Hemorrhagic heterotopic pregnancy in a setting of prior tubal ligation and re-anastomosis. *J Radiol Case Rep.* 2015;9(7):38–46. doi:10.3941/jrcr.v9i7.2386
- Bouab M, Wajih O, Gotni A, Assal A, Jalal M, Lamrissi A. Spontaneous heterotopic pregnancy: diagnosis and surgical management. *Int J Surg Case Rep.* 2024;118:109582. doi:10.1016/j.ijscr.2024.109582
- Sgayer I, Sharon A, Wolf M, Lowenstein L, Odeh M. Interstitial heterotopic pregnancy after bilateral total salpingectomy in IVF patients: a case report and literature review. *Ginekol Pol.* 2024;95(8):650–656. doi:10.5603/gpl.93808
- Michał M, Marian M, Marek M, Ewa WO. Heterotopic pregnancy in the absence of risk factors—diagnostics difficulties. *Ginekol Pol.* 2011;82(11):866–868.
- Libretti A, Longo D, Faiola S, De Pedrini A, Troia L, Remorgida V. A twin pregnancy with partial hydatidiform mole and a coexisting normal fetus delivered at term: a case report and literature review. *Case Rep Women's Health.* 2023;39(e00544). doi:10.1016/j.crwh.2023.e00544
- Černiauskaitė M, Vaigauskaitė B, Ramašauskaitė D, Šilkūnas M. Spontaneous heterotopic pregnancy: case report and literature review. *Medicina.* 2020;56(8):365. doi:10.3390/medicina56080365
- Maharjan S, Malla R, Chaudhary B, Shrestha P, Lama LD. Spontaneous Heterotopic Pregnancy: a Case Report. *JNMA J Nepal Med Assoc.* 2023;61(268):958–960. doi:10.31729/jnma.8374

16. Momtahan M, Kasraeean M, Faraji A, Moradi-Alamdarloo S, Moosaie M. Term spontaneous heterotopic pregnancy (abdominal and intrauterine): a case report. *Bull Emerg Trauma*. 2021;9(4):201–203. doi:10.30476/beat.2021.86588.1153
17. Ouafidi B, Kiram H, Benaguida H, Lamrissi A, Fichtali K, Bouhya S. Diagnosis and management of a spontaneous heterotopic pregnancy: rare case report. *Int J Surg Case Rep*. 2021;84:106184. doi:10.1016/j.ijscr.2021.106184
18. Lober R, Zafarnia M, Kupec T, Wittenborn J, Stickeler E, Najjari L. Spontaneous heterotopic pregnancy with ovarian localization: case report. *Z Geburtshilfe Neonatol*. 2024;228(3):286–289. doi:10.1055/a-2233-6452
19. Khouloud M, Maroua O, Montacer H, Salma S, Safa S, Haifa B. Early abdominal pregnancy in a spontaneous heterotopic pregnancy: case report. *Int J Surg Case Rep Apr*. 2024;117:109498. doi:10.1016/j.ijscr.2024.109498
20. Abdelmonem AH, Sayed G, Abugazia AE, Kohla S, Youssef R. Heterotopic pregnancy after a spontaneous conception a case report with a review of clinical, laboratory and imaging findings. *Clin Case Rep*. 2021;9(8):e04649. doi:10.1002/ccr3.4649
21. Kathopoulos N, Diakosavvas M, Kypriotis K, Chatzipapas I, Domali E, Protopapas A. Laparoscopic management of a second trimester ruptured spontaneous heterotopic tubal pregnancy mimicking ovarian tumour, a case report. *Facts Views Vis Obgyn*. 2023;15(2):157–160. doi:10.52054/fvvo.15.2.069
22. Maree G, Mohammad S, Moualla Z, Alshoumary L, Makhos R, Alfarrar A. Spontaneous ovarian and intrauterine non-viable heterotopic pregnancy at 12 weeks of gestation: a case report. *Case Rep Women's Health*. 2022;35:e00423. doi:10.1016/j.crwh.2022.e00423
23. Aziz M, Arronte J. A case of spontaneous heterotopic pregnancy in natural conception complicated with hemoperitoneum. *Heliyon*. 2020;6(2):e03373. doi:10.1016/j.heliyon.2020.e03373
24. Tariq Ahmed Alabsi M, Sunder A, AlSada A. Heterotopic cesarean scar pregnancy: a case report. *Cureus*. 2024;16(3):e55943. doi:10.7759/cureus.55943
25. Soecki G, Hlatchuk EC, Raymundo CT, et al. Heterotopic pregnancy and amniotic embolism: a case report. *BMC Pregnancy Childbirth*. 2024;24(1):752. doi:10.1186/s12884-024-06969-z
26. Dubbawar A, Srivastava A, Hiremath RN, Ghodke S, Chourey N, Sreenivas A. A rare case of spontaneous heterotopic pregnancy with intrauterine gestational trophoblastic neoplasia and tubal ectopic pregnancy at a remote secondary care hospital. *J Family Med Prim Care*. 2022;11(7):3996–3998. doi:10.4103/jfmpc.jfmpc_2448_21
27. Murewanhema G, Madombi S, Hlathswayo L, Simango N. Concurrent ruptured spontaneous heterotopic pregnancy and ruptured appendix with delayed presentation in the first trimester: a case report. *Pan Afr Med J*. 2020;37:222. doi:10.11604/pamj.2020.37.222.26182
28. Maduako KT, Onoh V. Term delivery of a heterotopic pregnancy coexisting with ruptured tubal ectopic pregnancy: a case report. *Afr J Reprod Health Apr*. 2022;26(4):110–113. doi:10.29063/ajrh2022/v26i4.12
29. Kajdy A, Muzyka-Placzyńska K, Filipecka-Tyczka D, Modzelewski J, Stańczyk M, Rabijewski M. A unique case of diagnosis of a heterotopic pregnancy at 26 weeks - case report and literature review. *BMC Pregnancy Childbirth*. 2021;21(1):61. doi:10.1186/s12884-020-03465-y
30. Julien A, Gremeau AS, Campagne-Loiseau S, et al. Case Report of an exceptional spontaneous abdominal heterotopic pregnancy with superfetation: diagnosis and treatment: heterotopic pregnancy with superfetation (8+1 WG & 5+4 WG). *J Gynecol Obstet Hum Reprod*. 2024;53(1):102701. doi:10.1016/j.jogoh.2023.102701
31. Ntounis T, Fasoulakis Z, Koutras A, et al. Heterotopic tubal pregnancy with a naturally conceived live twin intrauterine pregnancy in a patient with systemic lupus erythematosus: a case report. *Case Rep Women's Health*. 2021;32:e00348. doi:10.1016/j.crwh.2021.e00348
32. Dipanda AN, Fouogue JT, Mve VK, Kenfack B, Kemfang JDN. Pitfalls in diagnosing heterotopic pregnancy in Sub-Saharan Africa: a case report at the Yaounde University teaching hospital (Cameroon). *Case Rep Obstet Gynecol*. 2021;2021:7970646. doi:10.1155/2021/7970646
33. Fomukong NH, Ngouagna E, Edgar MML, et al. A case report of ruptured ectopic pregnancy plus massive hemoperitoneum on a heterotrophic pregnancy in a resource-poor setting, Mbengwi, Cameroon. *Pan Afr Med J*. 2021;39:52. doi:10.11604/pamj.2021.39.52.18513
34. Nkurunziza C, Rurangwa T, Ngendahimana V, Magriples U. Second trimester heterotopic triplet pregnancy with intrauterine twin pregnancy and ruptured interstitial pregnancy: a maternal near-miss case report. *Case Rep Obstet Gynecol*. 2020;2020:5240848. doi:10.1155/2020/5240848
35. Cucinella G, Gullo G, Etrusco A, Dolce E, Culmone S, Buzzaccarini G. Early diagnosis and surgical management of heterotopic pregnancy allows us to save the intrauterine pregnancy. *Prz Menopauzalny*. 2021;20(4):222–225. doi:10.5114/pm.2021.111277
36. Nguyen KP, Hudspeth M, Milestone H. Spontaneous heterotopic pregnancy: diagnosis and Management. *Case Rep Obstet Gynecol*. 2022;2022:2994808. doi:10.1155/2022/2994808
37. Elsayed S, Farah N, Anglim M. Heterotopic Pregnancy: Case Series and Review of Diagnosis and Management. *Case Rep Obstet Gynecol*. 2023; (5):2124191. doi:10.1155/2023/2124191
38. Li XH, Ouyang Y, Lu GX. Value of transvaginal sonography in diagnosing heterotopic pregnancy after in-vitro fertilization with embryo transfer. *Ultrasound Obstet Gynecol*. 2013;41(5):563–569. doi:10.1002/uog.12341

International Journal of Women's Health

Publish your work in this journal

The International Journal of Women's Health is an international, peer-reviewed open-access journal publishing original research, reports, editorials, reviews and commentaries on all aspects of women's healthcare including gynecology, obstetrics, and breast cancer. The manuscript management system is completely online and includes a very quick and fair peer-review system, which is all easy to use. Visit <http://www.dovepress.com/testimonials.php> to read real quotes from published authors.

Submit your manuscript here: <https://www.dovepress.com/international-journal-of-womens-health-journal>

Dovepress
Taylor & Francis Group