

Fish-tail resection for treating congenital entropion in Asians

Kazuaki Nakauchi
Osamu Mimura

Ophthalmology, Hyogo College
of Medicine, Hyogo, Japan

Preface: The Asian race has a high prevalence of congenital entropion. It was reported that over 20% of Japanese children have congenital entropion at the age of 1 year. One of the structural causes of this condition is the development of epiblepharon, which attaches the lower eyelid to the upper eyelid, and is also common among Asians. However, designing a procedure for modifying an epicanthus flap is relatively difficult, and epicanthoplasty is not a popular procedure in Japan. In the present study, we developed an easy method of designing the surgery, and we describe both the surgical procedure and the outcome.

Cases: Between January 2010 and August 2011, one surgeon performed surgery to correct congenital entropion in 28 patients. We analyzed this series of 28 cases retrospectively. The patients consisted of 17 females and eleven males with an average age of 7.6 years. Ten patients with a thick epicanthal fold required epicanthoplasties in addition to lower lid procedures, and 18 patients with a thin epicanthal fold required only lower lid procedures.

Surgical method: On the epicanthus, a small, triangular “fish-tail” flap that was 2 mm wide was designed and was located adjacent to a “fish-body” marking on the subciliary lower eyelid. After fish-tail resection, the residual medial edge was sutured to the corner of the epicanthus. A C-shaped epicanthus was changed into an L-shape by means of this procedure.

Result: The fish-tail resection diminished the tension of the orbicularis in the superior direction. After a minimum of 6 months, the shape of the medial canthus remained L-shaped, and the cilia had stable orientations.

Conclusion: This plasty is easy to design in conjunction with a Hotz procedure, and it is an effective means of correcting Asian congenital entropion. Recognizing the shape of a congenital entropion that is accompanied by epiblepharon is important for its radical treatment.

Keywords: epiblepharon, congenital entropion, asian, modified Hotz, fish tail

Introduction

Congenital entropion is a disease of the eyelid that is highly prevalent among oriental populations. It has been reported that the prevalence of this condition has a rate of over 20% among 1-year-old children and that the prevalence of this condition decreases to 2% in 12-year-old children.¹ It is thought that one of the causes of congenital entropion is excessive growth of the orbicularis muscle, which inverts the cilia toward the cornea. Development of an epicanthal fold also causes traction of the inner canthus area of the eyelid.^{2,3} In oriental eyelids, remarkable epicanthal folds are highly visible in single eyelids. The prevalence of an epicanthal fold is reportedly 70%–80% in Asian countries.^{4,5}

Correspondence: Kazuaki Nakauchi
1-1, Mukogawa-cho, Nishinomiya-city,
Hyogo-prefecture, Japan 663-8501
Tel +81 79 845 6462
Fax +81 79 845 6464
Email nakauchi@hyo-med.ac.jp

Epicanthoplasty of the superior eyelid has recently become a popular procedure in Asian plastic surgery.⁶⁻⁸ However, epicanthoplasty of the lower eyelid is not common because the procedures that are used to treat congenital entropion (ie, suturing procedures) are often performed by ophthalmologists, while epicanthoplasty, including designing, is a rather complicated procedure. Another reason that the procedure is not common is related to a desire to avoid scar formation and changes in the appearance of the patient.

Therefore, we developed an easy method of preparatory designing and a surgical method that can be performed in conjunction with a modified Hotz procedure. A triangle flap that is designed on the epicanthal fold resembles the shape of the tail of a fish, so we named this resection the “fish-tail” resection. This article describes this method and its clinical results.

Cases

Between January 2010 and August 2011, one surgeon performed congenital entropion surgery on 28 cases in the Ophthalmology Department of the Hospital of Hyogo College of Medicine, Hyogo, Japan. The indication for surgery was the presence of marked superficial punctate keratitis that had been determined by fluorescein staining. These keratitis sometimes occur in the amblyopia in younger patients. We analyzed this series of 28 cases retrospectively. In total, 17 of the patients were females, and eleven were males. The average age of the patients was 7.6 years. Ten patients with a thick epicanthal fold required epicanthoplasties that were accompanied by Hotz procedures, and 18 patients with a thin epicanthal fold required only Hotz procedures. The faces of the patients were photographed at consultations before and after surgery. The degree to which an epicanthoplasty was necessary was determined on the basis of whether a patient developed an epicanthal fold, and the effectiveness of each surgery was evaluated after the operation had been performed.

Method

Patients who were under the age of 15 years underwent surgeries that were performed under general anesthesia. Designing is the most important part of this surgery, and the surgical procedure is described in the following paragraphs.

An initial marking for a modified Hotz procedure was drawn on the summit of the lower eyelid. Marks were made approximately 2 mm below the cilia where the transverse

fiber of the orbicularis is prominent under the skin. About an 18 mm-long sharp spindle-shaped marking was made that began at the inner corner of the lower eyelid and extended to the middle part of the eyelid. Second, a 2 mm-wide triangle that was adjacent to the spindle body was marked on the epicanthus. One side of the triangle was aligned along the curvature of the epicanthus (Figure 1).

The shape of the complete marking resembled the body (spindle) and tail (triangle) of a fish. After designing, anesthesia was administered using 1% xylocaine with 0.001% epinephrine with the aim of avoiding bleeding. Five minutes after applying the anesthetic, an eyelid pincher was used, and an initial incision was made. The resection of the fish “body” was simple, but the resection of the fish “tail” required rather precise cutting skills using a sharp knife or blade (eg, a No 11 blade). Surgeons must take care to cut through all of the layers of the dermis (Figure 2).

After cutting through the skin and the dermis, a developed orbicularis was observed. Superficial layers of the orbicularis were carefully excised. Pretarsal portions of the transverse orbicularis were observed directly above the tarsus, and approximately two-thirds of these were excised. Once the tarsus had been exposed, mattress sutures that connected the tarsus to the dermis were made using 7-0 Vicryl sutures. In most cases, four or five stitches were required to convert the inverted cilia to a correct position.

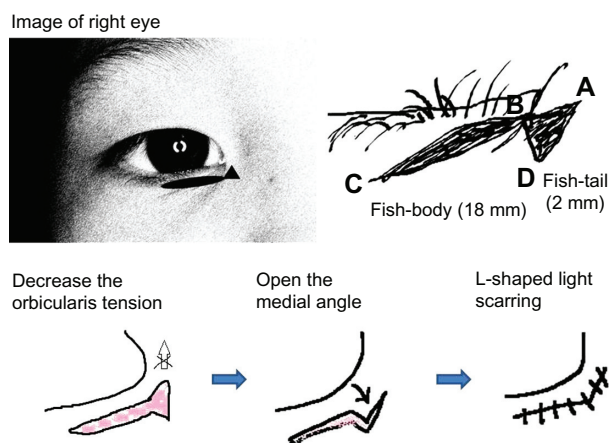


Figure 1 Schematic fish-tail resection.

Notes: This figure shows the front side of the right eye and explains the direction of insertion. Flap B is moved toward corner D, which results in widening of the angles between both A–D and B–D compared with these angles prior to operation. The traction of the orbicularis (in the A–C direction) is decreased, and the crescent form of the epicanthus is diminished. The angle of the medial canthus is widened. An inverted L-shape is obtained from the A–D and D–C sides at the conclusion of the procedure. Hotz mattress sutures are needed between B (D) and C, after which the A–D and D–C incisions are closed with end-to-end skin sutures.

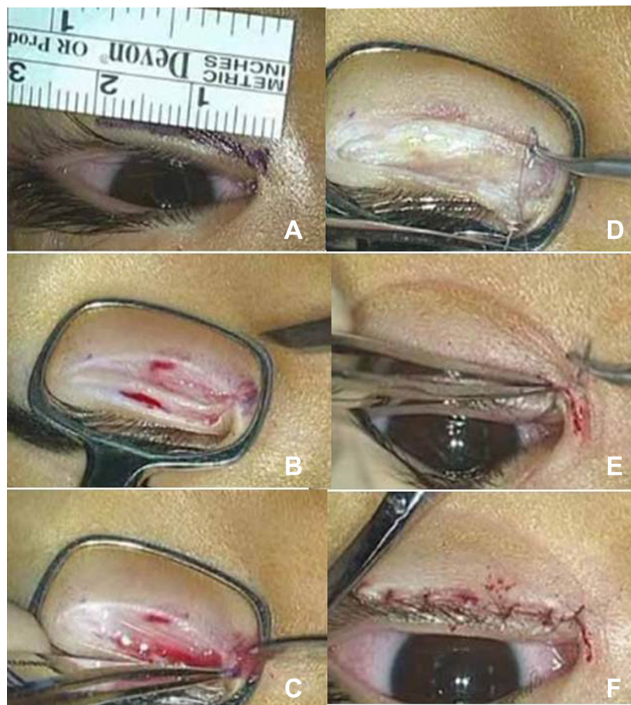


Figure 2 The sequential intraoperative photographs. (A) Marking design: the fish body is designed along the lower eyelid 2 mm beneath the cilia. Its width is about 1 mm and length is 18 mm. The fish tail is a 2 mm triangle, which is designed on the epicanthus fold along the curvature. (B) Fish-body cutting: an eyelid pincher is used to avoid bleeding and to extend the skin. A sharp knife is needed to cut the skin precisely, taking care to cut all the dermis layer along the marking. Just under the skin, orbicularis appear. (C) Fish-tail cutting: at the moment that the triangular fish-tail flap is cut, the tension of orbicularis along the epicanthus disappears. The narrow medial epicanthus angle is released. (D) Hotz mattress suture: mattress sutures are used to connect the tarsus to the dermis. In most cases, four or five stitches are tied to reposition the cilia from an inverted position to a correct orientation. (E) Medial key suture: finally, the residual medial edge is sutured to the corner of the edge of the epicanthus. This one suture opens the medial angle. (F) Appearance just after surgery: after all the skin sutures are done, an L-shaped suture line appears.

After the mattress sutures and reconfirmation of hemostasis had been completed, the eyelid pinch was removed. First, we sutured the residual edge that was nearest the cilia to the corner of the epicanthus to inlay the skin precisely. This one suture could open the angle of the medial canthus. We then closed the skin edge end to end along the fish-body incision using 7-0 Vicryl sutures. If the patient is old enough to endure the subsequent removal of stitches, 7-0 nylon sutures can be used instead. At the conclusion of the surgery, an antibiotic ointment was applied to the wound.

Results

Table 1 shows the results of two groups. The average age of the 28 patients was 7.6 years, and the sample population included eleven boys and 17 girls. All 18 patients (average age 8.3 years) who underwent the Hotz procedures alone had satisfactory results in terms of lower lid ciliary direction.

Table 1 The average age of the 28 cases that are included in this report is 7.6 years, and the group of cases comprises eleven boys and 17 girls

	Hotz alone	Hotz + fish tail
No of cases	18	10
No of eyes	35	20
Male/female	6/12	5/5
Average age (years)	8.3	6.4
Recurrence rate	1/35 (3%)	0/20 (0%)

Notes: In total, 18 patients with mild cases of ciliary inversion (six boys and twelve girls with an average age of 8.3 years; one girl had unilateral ciliary inversion) underwent Hotz procedures without fish-tail resections and had satisfactory results of lower lid ciliary redirection. However, ciliary inversion recurred in one eye (3%) in one of the patients in this group. Surgical outcomes were more successful in the ten patients (five boys and five girls with an average age of 6.4 years) with severe congenital entropion who underwent fish-tail resections that were accompanied by Hotz procedures. No recurrence was observed in any of these cases.

However, one patient (Figure 3) had a recurrence 9 months after surgery. The ten patients (average age 6.4 years) who underwent fish-tail resections in conjunction with Hotz procedures had more successful results. Figure 4 shows the representative case. The eyelashes are everted in this case,

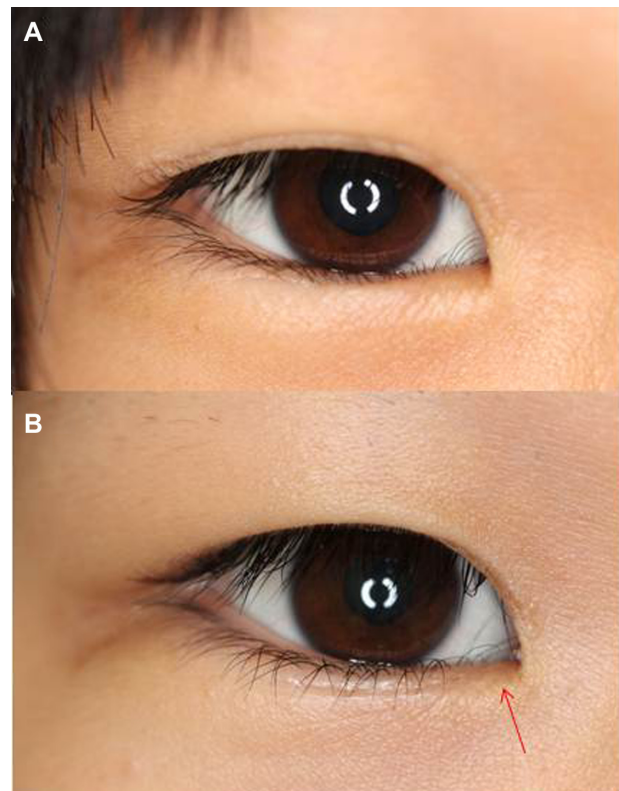


Figure 3 Hotz alone case.

Notes: Before (A) and after (B) photos of a 13-year-old girl who had an excellent epicanthus curve and who underwent only a Hotz procedure. Medial entropion is difficult to be corrected with a Hotz procedure, because of the tarsus location. Nine months later, her medial cilia (arrow) had returned to an inverted orientation, so ciliary electrolysis was performed.

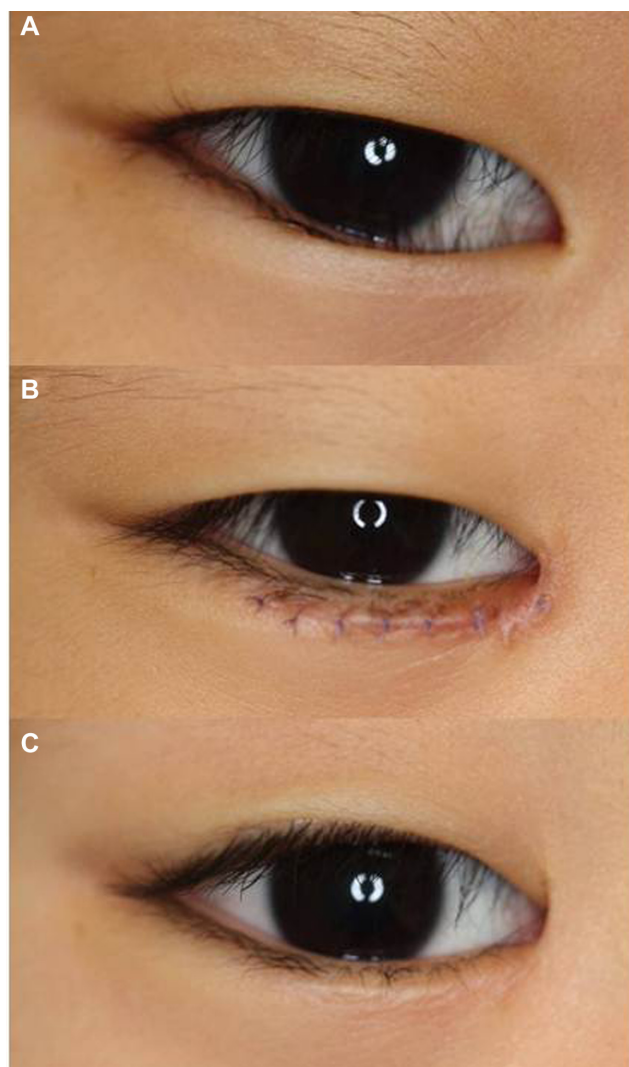


Figure 4 Hotz fishtail case. (A) A 6-year-old boy who had a typical epicanthal fold with inverted cilia (epiblepharon) prior to surgery. (B) He underwent the combined Hotz procedure and fish-tail resection. Two weeks after surgery, the 7-0 Vicryl sutures still remained. An L-shaped incision is recognized by the sutures. His inverted cilia were corrected completely. (C) Six months later his medial canthus angle was still open and the cilia were more everted than in the Hotz alone case.

compared with the Hotz alone procedure. Their medial canthus angles were wider than they had been prior to surgery, and the angles retained their postsurgical forms for a minimum of 6 months after surgery. No incidents of recurrence have been reported among these cases.

Discussion

We first recognized the term “congenital entropion” as referring to a condition in which there is an epicanthal fold with inverted cilia (epiblepharon) or a congenital lower eyelid deformity with trichiasis (true congenital entropion). From a public health standpoint, over 20% of 1-year-old infants in Japan have congenital entropion, but the prevalence of

this condition is only 2% in junior high school students.¹ The prevalence of epiblepharon decreases because of growth-induced mid-face alterations.^{2,9} Although congenital entropion is a rare condition in Western people,^{10,11} the 2% prevalence of it among junior high school-aged children in Japan may represent the rate of true congenital entropion. During our review of a series of 28 cases, only two patients showed prominent lacrimal caruncles, and these two patients might have true congenital entropion. Epicanthal folds usually occur in both eyelids, and the skin around each fold covers the medial canthal area in a crescent formation, but true congenital entropion sometimes occurs unilaterally.^{2,10}

Epicanthoplasty that is performed in conjunction with a lower lid entropion procedure has been an innovative solution for the treatment of congenital entropion in Asians.^{2,3} In 1841, von Ammon first developed surgical procedures for the correction of epicanthal folds, followed by the introduction of Mustarde’s flap.¹² Subsequently, Yoon¹³ developed a modification of that technique that was specific to the needs of Asian patients. Other methods, such as Uchida’s W plasty,¹⁴ the modified Y-V advanced flap procedure,¹⁵ the Z-plasty,⁵ and the modified Z-plasty method,^{6–8} have been used in Asian countries, but these surgical techniques are not popular among ophthalmologists.

One problem in the surgical correction of entropion is the complexity of designing the incision line for epicanthoplasty. Plastic surgeons sometimes recommend using root Z-plasty^{3,6} instead, but that technique requires relatively strong skills in both imaging and marking. Another common problem is the formation of scar tissue following surgery. Essentially, the effectiveness of the flap depends on the size of the flap. The use of a bigger flap resulted in prominent scarring on the medial canthus because of excessive tension. Thus, the balance between the effectiveness of a flap and the size of it is important when designing the flap.

In the present study, we developed an easy method for designing the flap. In accordance with Uchida’s procedure,¹⁴ a W-shaped flap is imaged on the epiblepharon. To minimize scarring, we used only the lower triangle of this W as a flap; the shape of this lower triangle mimics the shape of a fish tail, and it is continuous with a fish-body resection. Using this method, it is easier to determine both the design and the placement of the flap in patients with epiblepharon.

Another common problem with epicanthoplasty is that it changes the appearance of the eyes of the children who undergo this procedure. Some parents complain about this change in appearance, so it is important to obtain informed

consent prior to surgery. However, because of the small flap that was used in the procedure in this study, the appearance changes after the operation were not significant. The scarring was also kept to minimum. In a series of 28 patients, none of the parents had complaints about appearance changes in their children, but the patients often looked 2–3 years older after the surgery.

Cases in which entropion accompanies mild epiblepharon are sometimes complicated. We experienced one case in which entropion recurred (Figure 3); a 13-year-old girl had a beautiful epicanthus curve, so we could not touch her epicanthal fold. However, she had a rather thick fold (ie, a broad development of orbicularis) and, thus, medial ciliary entropion recurred after 9 months, and ciliary electrolysis was needed to treat trichiasis in this patient. If we fulfilled fish-tail resection on her epicanthus, her cilia could be more everted.

Our congenital entropion cases were divided into two groups on the basis of the development of epiblepharon (severe or mild). One difference between these two groups was in average age (6.4 years vs 8.3 years), which suggests that patients with severe entropion cases often need earlier surgery. In addition, the epicanthal fold is generally thicker at earlier ages.

In the series of cases that is discussed in this article, recurrence of ciliary inversion is rare. Previous reports show a recurrence rate of approximately 10% when patients are treated with bracing sutures,^{2,16} and about 9% of patients are undercorrected with a modified Hotz procedure.² The Hotz procedure's weak point is that it could not correct the medial part of cilia because of the tarsus location. In the present study, however, all of the patients who underwent a modified Hotz procedure that either was or was not accompanied by a fish-tail resection had a lower recurrence rate. This result is relevant to the accuracy of the surgeon's technique and the selection of the proper procedure. Because there is no existence of tarsus in the medial eyelid, we selected Hotz plus fish-tail surgery for severe epiblepharon cases. During surgery, it was observed that the epicanthal fold is composed of redundant skin and is directly beneath a developed orbicularis band. At the moment that the triangular fish-tail flap was cut, the traction from the orbicularis disappeared. Moreover, the inlay of the medial edge increased the efficacy of widening the medial angle and correction of the medial part of the cilia. This result demonstrates that orbicularis tension that is related to an epiblepharon is one of the causes of congenital entropion.

In infant cases, the 7-0 Vicryl sutures were very useful; this type of suture is composed of an absorbable material with a tensile strength that was maintained for 6 weeks, and it can be used for both internal and skin sutures. However, it has the disadvantage of causing skin redness that can continue for between 2 months and 6 months. Therefore, in cases in which the child can endure the removal of stitches, 7-0 nylon sutures are a more suitable alternative and contribute to minimizing scarring.

Conclusion

This blepharoplasty approach is easy to design, and it facilitates the performance of the Hotz procedure by removing the main cause of congenital entropion and allowing for effective correction. It is important to determine whether there has been a development of epiblepharon in each case and to select the appropriate procedure.

Disclosures

This study was approved by the Ethics Committee of the Hyogo College of Medicine. The Committee is located at the Hospital of Hyogo College of Medicine, Hyogo, Japan. This study was not supported by any specific grant from any funding agency in the public, commercial, or not-for-profit sectors. The authors have no competing interest to the report. The authors contributed equally to this study.

References

1. Noda S, Hayasaka S, Setogawa T. Epiblepharon with inverted eyelashes in Japanese children. Incidence and symptoms. *Br J Ophthalmol*. 1989;73:126–127.
2. Sundar G, Young SM, Tara S, Tan AM, Amrith S. Epiblepharon in East Asian patients: the Singapore experience. *Ophthalmology*. 2010;117:184–189.
3. Kashima T, Katori N, Yamada T, Imagawa Y, Nakauchi K. Epicanthoplasty simultaneous with epiblepharoplasty in cases of epiblepharon with epicanthus [Japanese]. *Nihon Ganka Gakkai Zasshi*. 2010;114:105–109.
4. Hyakusoku H, Fumiiri M. The square flap method. *Br J Plast Surg*. 1987;40:40–46.
5. Park JI. Z-epicanthoplasty in Asian eyelids. *Plast Reconstr Surg*. 1996;98:602–609.
6. Yoo WM, Park SH, Kwag DR. Root Z-epicanthoplasty in Asian Eyelids. *Plast Reconstr Surg*. 2002;109:2067–2071.
7. Zhang H, Zhuang H, Yu H, et al. A new Z-epicanthoplasty and a concomitant double eyelidplasty in Chinese eyelids. *Plast Reconstr Surg*. 2006;118:900–907.
8. Lu JJ, Yang K, Jin XL, et al. Epicanthoplasty with double eyelidplasty incorporating modified Z-plasty for Chinese patients. *J Plast Reconstr Aesthet Surg*. 2011;64:462–466.
9. Hayasaka Y, Hayasaka S. Epiblepharon with inverted eyelashes and high body mass index in Japanese children. *J Pediatr Ophthalmol Strabismus*. 2005;42:300–303.
10. O'Donnell BA, Collin JR. Congenital lower eyelid deformity with trichiasis (epiblepharon and entropion). *Aust N Z J Ophthalmol*. 1994;22:33–37.

11. Czukrasz I. Congenital entropion due to epiblepharon. *Br J Ophthalmol*. 1950;34:318–319.
12. Mustarde JC. Epicanthus and telecanthus. *Br J Plast Surg*. 1963;16:346–356.
13. Yoon K. Modification of Mustarde technique for correction of epicanthus in Asian patients. *Plast Reconstr Surg*. 1993;92:1182–1186.
14. Uchida J. Triangular flap method in medial and lateral canthotomy [Japanese]. *Keisei Geka*. 1967;10:120–123.
15. Kao YS. Epicanthoplasty with modified Y-V advancement procedure. *Plast Reconstr Surg*. 1998;102:1835–1841.
16. Hayasaka S, Noda S, Setogawa T. Epiblepharon with inverted eyelashes in Japanese children. Surgical repairs. *Br J Ophthalmol*. 1989;73:128–130.

Clinical Ophthalmology

Dovepress

Publish your work in this journal

Clinical Ophthalmology is an international, peer-reviewed journal covering all subspecialties within ophthalmology. Key topics include: Optometry; Visual science; Pharmacology and drug therapy in eye diseases; Basic Sciences; Primary and Secondary eye care; Patient Safety and Quality of Care Improvements. This journal is indexed on

Submit your manuscript here: <http://www.dovepress.com/clinical-ophthalmology-journal>

PubMed Central and CAS, and is the official journal of The Society of Clinical Ophthalmology (SCO). The manuscript management system is completely online and includes a very quick and fair peer-review system, which is all easy to use. Visit <http://www.dovepress.com/testimonials.php> to read real quotes from published authors.