

A Late Diagnosis of Visceral Leishmaniasis Using Tru-Cut Biopsy of the Spleen and Malaria Co-Infection – A Diagnostic Challenge: A Case Report in Somalia

Mohamed Abdulahi Hassan^{1,2}, Abdullahi Abdirahman Omar¹, Ibrahim Abdullahi Mohamed¹, Bashiru Garba^{3,4}, Mohamed Mohamud Ali Fuje⁵, Sagal Omar Salad⁶

¹Department of Internal Medicine and Intensive Care Unit, Dr.Sumait Hospitals Affiliated of SIMAD University, Mogadishu, Somalia; ²Department of Internal Medicine, Faculty of Medicine and Health Sciences, SIMAD University, Mogadishu, Somalia; ³Dr.Sumait Hospital, Faculty of Medicine and Health Sciences, SIMAD University, Mogadishu, Somalia; ⁴Department of Veterinary Public Health and Preventive Medicine, Faculty of Veterinary Medicine, Usmanu Danfodiyo University, Sokoto, Sokoto State, Nigeria; ⁵School of Postgraduate Studies, Benadir University, Mogadishu, Somalia; ⁶Sagal Pathology Center, Mogadishu, Somalia

Correspondence: Mohamed Abdulahi Hassan, Tel +252615987780, Email modhassan@simad.edu.so

Background: Visceral leishmaniasis (VL) is fatal neglected parasitic illness caused by *Leishmania donovani*. The diagnosis remains a challenge due to the non-specific clinical symptoms, especially in areas where infections like malaria and limited access to diagnostic tools coexist. Here, we describe a case of late diagnosis of visceral leishmaniasis using tru-cut biopsy of the spleen and malaria co-infection.

Case Presentation: Here case report, a 24-year-old patient from an endemic region of Somalia presented with fever, headache, abdominal pain, nausea, vomiting, and weight loss for two months. Initially, the patient received symptomatic treatment and a blood transfusion but showed no improvement. Physical examination revealed fever, pallor, and hepatosplenomegaly. Laboratory tests showed pancytopenia and positive rapid diagnostic test for *plasmodium* parasite antigen. Despite three days of anti-malarial treatment, the symptoms persisted, and hepatosplenomegaly worsened. Further investigations, including infectious disease tests, were conducted, ruling out HIV, viral hepatitis, *Brucella*, and *Leishmania* antibodies. Peripheral blood smear showed pancytopenia and bone marrow aspiration revealed no evidence of infection or malignancy. A tru-cut biopsy of the spleen was performed, confirming the diagnosis of visceral leishmaniasis. The patient received a combination therapy of sodium stibogluconate and paromomycin, leading to significant improvement. After completing treatment, the patient was discharged with normal spleen biopsy results.

Conclusion: Visceral leishmaniasis (VL) is a challenging disease to diagnose, especially in areas where it coexists with other infectious diseases, such as malaria. Co-infection with malaria should also be considered in patients with fever and hepatosplenomegaly. A high index of suspicion is necessary for the timely diagnosis of VL, and a tru-cut biopsy of the spleen can be conducted in cases where other investigations are inconclusive in endemic areas. Early diagnosis and prompt treatment of visceral leishmaniasis are crucial to prevent complications and reduce mortality.

Keywords: visceral leishmaniasis, malaria, tru-cut biopsy, co-infection

Introduction

Visceral leishmaniasis (VL), commonly known as kala-azar, is caused by the protozoan parasite *Leishmania donovani* and transmitted by the bite of infected sandflies. Its symptoms include irregular bouts of fever, loss of weight, enlarged liver and spleen, and anemia. Visceral leishmaniasis is mainly endemic in Brazil, India and East Africa and every year, an estimated 50,000 to 90,000 new cases of VL are reported globally. However, only 25–45% of these cases are being reported to the WHO despite the potential of this disease to cause outbreaks and mortalities which could be as high as 95% if not treated in time.¹

The prevalence of leishmaniasis in the East Mediterranean Region (EMR) is a major concern for the public health sector. As per the report by World Health Organization (EMR), 12 countries in the region reported 100,000 new cases of cutaneous leishmaniasis in 2008. Similarly, Sudan and Somalia documented 4108 and 583 cases of anthroponotic visceral leishmaniasis (AVL), respectively.²

Malaria and leishmaniasis can occur in the same geographic locations, resulting from possible co-infection with *Plasmodium spp.* in patients with VL. However, there have only been a few studies reporting on this co-infection and it is still being considered. Undiagnosed co-infection can cause significant delays in leishmaniasis diagnosis and pose a serious health risk.³

Despite being a serious public health concern, VL is often misdiagnosed or undiagnosed due to its nonspecific symptoms and the lack of adequate diagnostic tools in many endemic areas. In addition, co-infections with other diseases such as malaria can further complicate the diagnosis and treatment of VL. Here, we report the diagnostic challenge of a case where a tru-cut biopsy of the spleen was used to confirm the diagnosis of VL in a patient who had initially been diagnosed with malaria.

Case Presentation

A 24-year-old male patient who recently arrived in Burhakaba town of Somalia from Sa'ada in northwest of Yemen, was referred to our hospital with complaint of left upper hypochondrium mass. He was presented with high grade fever; headache and abdominal pain associated with nausea, vomiting, and weight loss for two months. The patient claimed he had experienced a similar clinical condition three months ago. Before reporting to our hospital, he had visited a local hospital in the region, where they administered him local symptomatic treatment of antipyretics, antibiotics and transfused with 2 units of whole blood, after which he felt mild improvement. However, two months later, his clinical signs recur but this time with loss of appetite, weight loss and generalized weakness. In general physical examination on presentation at our hospital, the patient appeared ill, thin, febrile and pale. Abdominal examination revealed splenomegaly. The other system examinations were normal. Following his admission, the vital signs were blood pressure 110/78 mmHg, pulse rate 110 beat/minute, respiratory rate 16 beat/minute, temperature 38.9°C, and blood glucose was 110 mg/dl. The initial laboratory investigation showed white blood cell count $1.03 \times 10^9/L$ (normal $4.00\text{--}10.00 \times 10^9/L$), hemoglobin 6.6 g/dl (normal 12.0–16.0 g/dl), hematocrit 0.203 (normal 0.400–0.540), platelet $70 \times 10^9/L$ (normal $100\text{--}300 \times 10^9/L$), C-reactive protein 45.73 mg/L (normal 2.5–10 mg/L), aspartate transaminase (AST) 104.5 U/I (normal 6–38 U/I), alanine transaminase (ALT) 112.5 U/I (normal 6–40 U/I), serum creatinine 1.4 mg/dl (normal 0.4–1.4 mg/dl), and serum urea 54.3 mg/dl (10–50 mg/dl). In addition, a rapid diagnostic test (RDT) for plasmodium parasite antigen was conducted and was found to be positive. Abdominal ultrasound revealed enlargement of the liver (20cm) and enlargement of the spleen (30cm). The patient was admitted initially for treatment of malaria starting with four doses of intravenous artesunate 120mg, symptomatic treatment of antipyretics of paracetamol, dextrose-normal saline fluids and also transfused one unit whole blood. On the third day of admission after administering antimalarial treatment, no significant improvement was observed. Hence, further investigations including infectious disease tests such as the human immunodeficiency virus, viral hepatitis, and *Brucella* serological tests were conducted and found to be negative. Also, an anti-Leishmania antibody with an enzyme-linked immunosorbent assay (ELISA) was not detected. On the fourth day, peripheral blood smear and bone marrow aspiration were performed, and the peripheral blood smear result showed only pancytopenia and no evidence of malaria parasite seen (Figure 1). The bone marrow aspiration also did not indicate any abnormality. However, a tru-cut biopsy of the spleen was performed and the result of the histopathology examinations of tru-cut biopsy revealed consistent features with visceral leishmaniasis (Figure 2). Following this outcome, an urgent combination therapy of sodium stibogluconate 800mg/day with paromomycin 600mg/day for 17 days was given. After the fourth week of treatment, significant improvement was observed on the patient based on the clinical and the laboratory results. At the end of the fifth week the patient was fully recovered as seen from the clinical signs and lab results (Table 1), hence he was discharged following normal results of another true cut biopsy of spleen (Figure 3).

Discussion

Visceral leishmaniasis (VL) is a disease caused by a parasite that often gets neglected. It is estimated that the incidence of this disease ranges from 202,000 to 400,000 clinical cases which results in 20,000–40,000 deaths each year all over the

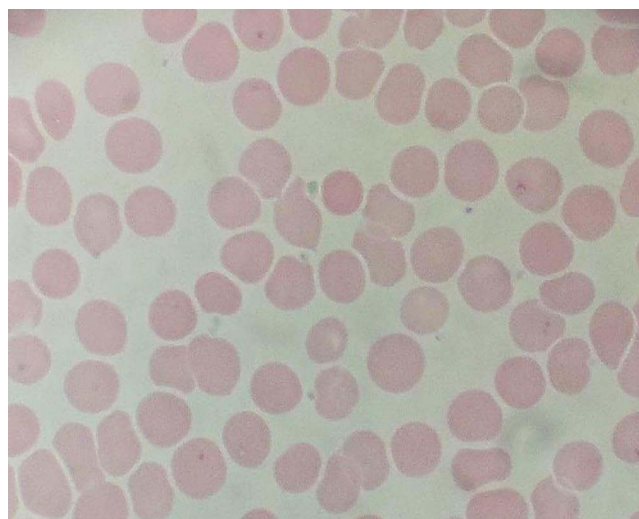


Figure 1 Peripheral blood smear showing pancytopenia.

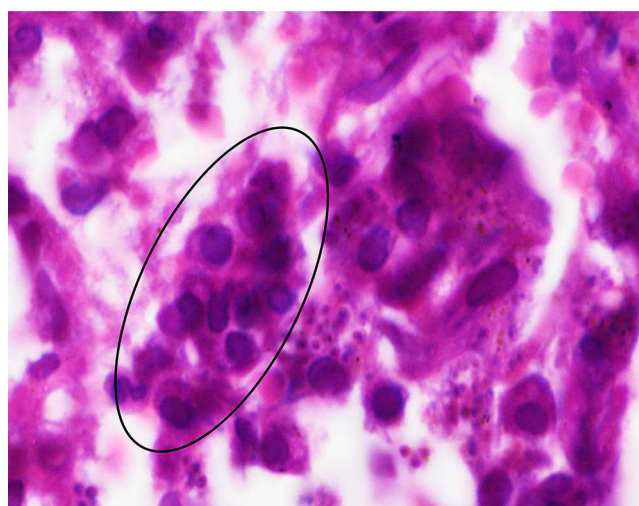

Figure 2 High power microscopic view shows splenic tissue with prominent histiocytic infiltrate. The black circle indicates the numerous leishmania amastigotes.

world. Unfortunately, this number may be even higher since most VL deaths are not identified as being caused by leishmaniasis or are not reported.⁴

The East African region is still severely affected by leishmaniasis, and there is a lack of reporting on its prevalence, distribution, social or risk factors, and transmission. This has made it difficult to manage the disease in most afflicted countries including Somalia.⁵

The weakness of the health systems in disease endemic regions is a major challenge in the clinical management of VL and the existing diagnostics and treatments of VL in East Africa are not as effective and progress has been more fragile.⁶

The World Health Organization (WHO) has reported that Visceral Leishmaniasis (VL) is widespread in Somalia, with an incidence rate of 4.98 per 10,000 in areas where it is endemic.⁷ However, there is a scarcity of epidemiological data available for this disease in Somalia.⁸

The causative species for VL in Somalia is identified as the *L. donovani* complex. Although there is no definitive data confirming the competent vector, *P. martini* is suspected to be a likely candidate in endemic areas based on limited studies.⁹

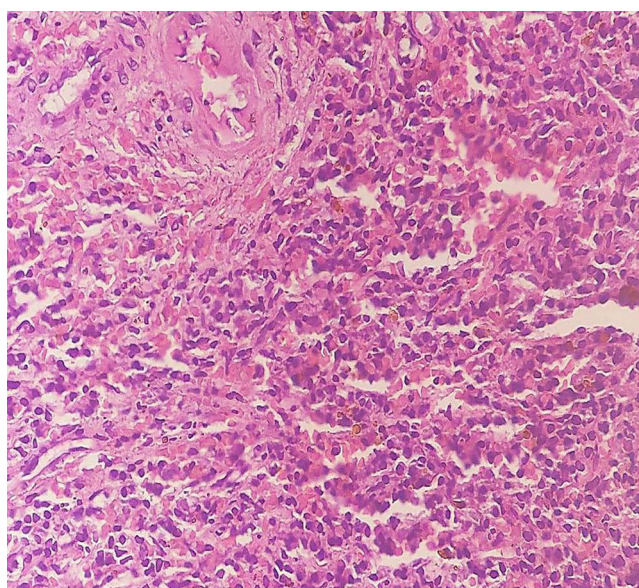
Table 1 Results of the Laboratory Investigation

Variables (Tests)	Reference Range	On Admission	Before Treatment	After Treatment
White cell count (WBC, $\times 10^9$ /L)	4.00–10.00	1.03	2.58	5.99
Hemoglobin (HB, g/dl)	12.0–16.0	6.6	7.6	11.5
Hematocrit (HCT, $\times 100$)	0.400–0.540	0.203	0.289	0.399
Platelet (PLT, $\times 10^9$ /L)	100–300	70	78	227
C-reactive protein (CRP, mg/L)	2.5–10	45.73	37	8
Aspartate transaminase (AST-U/L)	6–38	104.5	90	31
Alanine transaminase (ALT, U/L)	6–40	112.5	102	38
Creatinine (Creatinine, mg/dl)	0.4–1.4	1.4	1.2	1.4
Blood urea (Blood urea, mg/dl)	10–50	54.3	45	49
Prothrombin time (PT, sec)	10–14	19.8	17	14
Activated partial Thromboplastin time (APTT, sec)	11–45	49.7	47	40.2

Note: *Sign of multiplication.

Leishmaniasis is a significant public health issue in Yemen, affecting the entire country, cutaneous leishmaniasis caused by *Leishmania tropica* and *Leishmania major* is widespread, but its true incidence is not well-documented due to limited data. Visceral leishmaniasis (kala-azar) is also endemic in Yemen, often leading to late or missed diagnoses. Central Yemen, particularly Al Bayda governorate, has the highest prevalence of cutaneous leishmaniasis, while visceral leishmaniasis cases are mainly found in southeast and northern Yemen, caused by *L. infantum* and *L. donovani*.¹⁰

Malaria is a significant public health concern in Somalia, with *Plasmodium falciparum* being the dominant species, accounting for over 95% of cases nationwide and there has been an increase in the proportion of *P. vivax* cases reported in the North-west and Northeast regions and previous surveys have indicated lower prevalence in the north and center of the country, while the riverine areas along the Juba and Shabelle rivers in the south have higher prevalence.¹¹ It is worthy of note our inability

**Figure 3** Low power microscopic view shows normal splenic histology.

to confirm both the plasmodium and leishmania to species level are some of the limitations of this report because speciation is not commonly done in clinical practice in the country, in addition to lack of skilled technicians.

Malaria is a significant public health concern in Yemen, with the highest prevalence in the Eastern Mediterranean Region and present in all areas below 2000mASL, mainly caused by *P. falciparum*, with *P. malariae* and *P. vivax* also contributing and some challenges such as insecurity and limited access, reported data on malaria cases and their species may underestimate the actual burden of the disease.¹²

In this case, the patient recently arrived from a town called Burhakaba, located in South western region of Somalia but the patient is originally from Sa'ada in northwest of Yemen. The south western of Somalia and the northwest of Yemen is an endemic area for both Malaria and leishmaniasis.^{8,13} The Bay region, particularly Burhakaba, located near the Shabelle river and Sa'ada also with lakes, experiences endemic malaria due to these geographical factors.

Visceral leishmaniasis and malaria are life threatening parasitic diseases that continue to be a significant public health concern, particularly in endemic regions. VL diagnosis can be complicated by the similarity in clinical features with other febrile and splenomegaly conditions, with malaria being a common misdiagnosis. Although their co-infection has not been well studied, these parasitic diseases have a significant economic, social, and physical impact, and impose a heavy burden on developing countries, including Somalia.⁹ This case has a unique association of symptoms of the two parasitic infections and presented as an example of the diagnostic challenges faced in such endemic regions and also the importance of early diagnosis and treatment of VL to prevent severe complications and reduce mortality rates.

Diagnosis of VL relies on combining clinical signs with parasitological or serological tests, but these methods have limitations, and underreporting of cases is common due to diagnostic challenges and limited resources in endemic areas.¹

ELISA serological test, a widely used diagnostic technique for infectious diseases like leishmaniasis, the test technique necessitates a highly specific antigen as the initial reagent the techniques are extremely sensitive, while specificity relies on antigen to detect antibodies. It exhibits high sensitivity (80% to 100%) and specificity (84% to 95%), which varies based on the chosen antigen. However, caution is necessary as cross-reactions have been observed with patients suffering from malaria, trypanosomiasis, tuberculosis, and toxoplasmosis.¹⁴ In this study, we used antigen of a crude soluble antigen (CSA), which we were obtained by freezing and thawing promastigote suspension in phosphate-buffered saline. The resulting supernatant was then used to coat ELISA plates after estimating the protein content (100–5000ng/mL). This process involves cold centrifugation at 10,000–20,000g. In this case also the anti-leishmania ELISA antibody was accessible and carried out initially for diagnosing and showed no antibodies detected, it may be false negativity due to the cross reaction of malaria or it may be the antibody titers according diseases activity. However, its practical application in field conditions has been limited due to the need for advanced laboratory equipment and well-trained personnel.

The confirmation of visceral leishmaniasis on parasitological diagnosis involves examining the intracellular amastigote form of the parasite, also known as 'LD bodies'. These can be observed in monocytes or macrophages when examining Giemsa-stained blood or samples from lymph nodes, bone marrow, or spleen under a microscope. Due to its high specificity, parasitological diagnosis continues to be remaining the most gold standard for diagnosing VL.¹⁵

The sensitivity of direct microscopic examination can vary, with the lowest sensitivity observed in peripheral blood smears due to the low parasitaemia in immunocompetent individuals with VL.¹⁴

The reported sensitivity of examining lymph node aspirates directly under a microscope ranges from 52% to 58%, while for bone marrow aspirates it ranges from 52% to 85%, enlarged lymph nodes are commonly observed in VL patients in Sudan but are rare in patients from other countries.¹⁴ Among the different aspirate assays, spleen aspiration has been shown to be the most sensitive, with a sensitivity ranging from 93.1% to 98.7%, nevertheless around 0.1% cases of fatality can occur.¹⁶ Tru-cut biopsy (spleen aspiration) is a very accurate method used to obtain representative tissue samples for histopathology with a high diagnostic accuracy of 98.2%.¹⁷ Splenic aspiration or biopsy is not recommended to use as initial diagnostic method at the first health care line. It is also not feasible for non-cooperative children, challenging for individuals without a palpable spleen, and should not be performed in individuals with active bleeding, thrombocytopenia, severe anemia or jaundice, those in a critical condition, non-cooperative individuals, and pregnant women.¹⁴

According study conducted in a specialized diagnosis and treatment center in India over the past two decade found that out of 9612 cases of splenic aspiration, there were only two cases of life-threatening hemorrhages developed.¹⁸ In Kenya, one fatality was recorded among 671 cases of splenic aspiration, while in India, three deaths were reported among 3000 of cases performed.¹⁹

A study conducted in Medicine Unit-I of Mymensingh Medical College Hospital compared splenic and bone marrow aspiration in 50 adult kala-azar patients. Splenic aspiration was more sensitive, with 90% of spleen aspirates containing LD bodies compared to 72% in bone marrow aspirates. Patients preferred splenic aspiration due to lower pain. Both procedures were safe, with mild pain and a few cases of epistaxis reported. Physicians preferred splenic aspiration/biopsy for its ease and reliability.²⁰

Bone marrow or splenic aspiration is a technique that is both painful and risky. It requires a technician with skilled and experienced hands to perform the procedure. Serious bleeding is rare but can occur, so it is typically only carried out in referral research centers and hospitals, while bone marrow aspiration is a highly reliable method that is safer than splenic aspiration and liver biopsy, but it is less likely to demonstrate parasite in the stained film.¹⁵

In this case, splenic aspiration/True-cut biopsy performed cautiously by an experienced interventional radiologist in the hospital under ultrasound guidance after all other tests were not detected. The splenic tissue was immersed in 10% buffered formalin for fixation after processing and embedding, it was cut into 5mm thickness by a microtome. A routine hematoxylin and eosin were used for staining. The bone marrow aspiration of this patient was performed on the posterior iliac crest by pathologist. The smear was Wright-Giemsa stained and then histologic section was stained with hematoxylin-eosin.

Visceral Leishmaniasis, commonly known as VL, is treated with a combination of sodium stibogluconate and paromomycin in Somalia and East Africa. This treatment has been demonstrated to be both effective and safe for individuals who have a strong immune system.²¹

Finally, this case is calling for increased awareness and improved access to diagnostic tools and treatment options for VL, particularly in endemic areas of resource-limited settings.

Conclusion

We present a case of a patient who was diagnosed with VL using a Tru-cut biopsy of the spleen and had a co-infection with plasmodium parasite, which highlights the challenges of diagnosing and treatment of VL in endemic areas, particularly in the context of co-infection with other diseases such as malaria. It emphasizes the urgent need for better diagnostic tools and treatment access for VL in such areas. This case study underscores the importance of high suspicion for co-infection when an individual hailing from or having a history of travel to endemic countries presents with prolonged fever and splenomegaly.

Abbreviations

VL, visceral leishmaniasis; EMR, east Mediterranean region; WHO, world health organization; ELISA, enzyme-linked immunosorbent assay.

Ethics and Consent

Informed consent: A Written consent form was attained from the patient for publication of this case report and the attaching images. In our institution, ethical approval is not required for case reports.

Acknowledgments

We would like to express our sincere gratitude and deep appreciation to Dr. Omar H. Badawi for his guidance and recommendations in this case report.

Disclosure

The authors report no conflicts of interest in this work.

References

1. Leishmaniasis (2023) World Health Organization. Available from: <https://www.who.int/news-room/fact-sheets/detail/leishmaniasis>. Accessed March 19, 2023.
2. Postigo JA. Leishmaniasis in the World Health Organization Eastern Mediterranean Region. *Int J Antimicrob Agents*. 2010;36(Suppl 1):S62–S65. doi:10.1016/j.ijantimicag.2010.06.023
3. Wilairatana P, Channol W, Rattaprasert P, et al. Prevalence and characteristics of malaria co-infection among individuals with visceral leishmaniasis in Africa and Asia: a systematic review and meta-analysis. *Parasit Vectors*. 2021;14(1). doi:10.1186/s13071-021-05045-1
4. Alvar J, Vélez ID, Bern C, et al. Leishmaniasis Worldwide and Global Estimates of Its Incidence. *PLoS One*. 2012;7(5):e35671. doi:10.1371/journal.pone.0035671
5. Malaria Consortium C. Leishmaniasis Control in Eastern Africa: past and Present Efforts and Future Needs. Situation Gap Analysis; 2010. Available from: https://www.malariaconsortium.org/userfiles/file/NTD%20Resources/VL%20EA%20Situation%20Analysis%20Fina_Janl.pdf. Accessed March 21, 2023.
6. Singh OP, Sundar S. Developments in Diagnosis of Visceral Leishmaniasis in the Elimination Era. *J Parasitol Res*. 2015;2015:239469. doi:10.1155/2015/239469
7. World Health Organization. WHO Leishmaniasis Country Profile- Somalia 2015; 2015. Available from: https://www.who.int/leishmaniasis/burden/Somalia_2015-hl.pdf?ua=1. Accessed March 12, 2023.
8. Sunyoto T, Potet J, Boelaert M. Visceral leishmaniasis in Somalia: a review of epidemiology and access to care. *PLoS Negl Trop Dis*. 2017;11(3):e0005231. doi:10.1371/journal.pntd.0005231
9. Jones CM, Welburn SC. Leishmaniasis Beyond East Africa. *Front Veterinary Sci*. 2021;8. doi:10.3389/fvets.2021.618766
10. Al-Kamel MA. Leishmaniasis in Yemen: a clinicoepidemiological study of leishmaniasis in central Yemen. *Int J Dermatol*. 2016;55(8):849–855. doi:10.1111/ijd.13041
11. Guidelines for the Diagnosis and Treatment of Malaria in Somalia 2016. Available from: https://www.humanitarianresponse.info/sites/www.humanitarianresponse.info/files/documents/files/malaria_diagnosis_and_treatment_guidelines_180316.pdf. Accessed August 30, 2023.
12. Malaria In Yemen: needs Assessment 2017. Available from: https://publications.iom.int/system/files/pdf/yemen_malaria_report.pdf. Accessed August 30, 2023).
13. Ornellas-Garcia U, Cuervo P, Lima Ribeiro-Gomes F. Malaria and leishmaniasis: updates on co-infection. *Front Immunol*. 2023;14. doi:10.3389/fimmu.2023.1122411
14. Boelaert M, Bhattacharya S, Chappuis F, et al. Evaluation of rapid diagnostic tests: visceral leishmaniasis. *Nat Rev Microbiol*. 2007;5(S11):S31–S39. doi:10.1038/nrmicro1766
15. Kumar A, Pandey SC, Samant M. A spotlight on the diagnostic methods of a fatal disease Visceral Leishmaniasis. *Parasite Immunol*. 2020;42(10):e12727. doi:10.1111/pim.12727
16. van Griensven J, Diro E. Visceral leishmaniasis. *Infect Dis Clin North Am*. 2012;26(2):309–322. doi:10.1016/j.idc.2012.03.005
17. Rikabi A, Hussain S. Diagnostic usefulness of tru-cut biopsy in the diagnosis of breast lesions. *Oman Med J*. 2013;28(2):125–127. doi:10.5001/omj.2013.32
18. Sundar S, Rai M. Laboratory diagnosis of visceral leishmaniasis. *Clin Diagn Lab Immunol*. 2002;9(5):951–958. doi:10.1128/cdli.9.5.951-958.2002
19. Boelaert M, Rijal S, Regmi S, et al. A comparative study of the effectiveness of diagnostic tests for visceral leishmaniasis. *Am J Trop Med Hyg*. 2004;70(1):72–77. doi:10.4269/ajtmh.2004.70.72
20. Sarker CB, Alam KS, Jamal MF, et al. Sensitivity of splenic and bone marrow aspirate study for diagnosis of kala-azar. *Mymensingh Med J*. 2004;13(2):130–133.
21. Abdulrashid M, Ahmed B. Acute kidney injury as initial presentation of visceral leishmaniasis in a young patient- A case report. *Ann Med Surgery*. 2022;78. doi:10.1016/j.amsu.2022.103821

Infection and Drug Resistance

Dovepress

Publish your work in this journal

Infection and Drug Resistance is an international, peer-reviewed open-access journal that focuses on the optimal treatment of infection (bacterial, fungal and viral) and the development and institution of preventive strategies to minimize the development and spread of resistance. The journal is specifically concerned with the epidemiology of antibiotic resistance and the mechanisms of resistance development and diffusion in both hospitals and the community. The manuscript management system is completely online and includes a very quick and fair peer-review system, which is all easy to use. Visit <http://www.dovepress.com/testimonials.php> to read real quotes from published authors.

Submit your manuscript here: <https://www.dovepress.com/infection-and-drug-resistance-journal>