

Keloids After Herpes Zoster: Report of Wolf's Isotopic Phenomenon and Literature Review

Jian Wang, Huiliang Shen 

Department of Dermatology, Zhejiang Province Dermatology Hospital, Huzhou City, Zhejiang Province, 313200, People's Republic of China

Correspondence: Huiliang Shen, Department of Dermatology, Zhejiang Province Dermatology Hospital, No. 61, Wuyuan Street, Wukang Town, Deqing County, Huzhou City, Zhejiang Province, 313200, People's Republic of China, Email shl.1168@163.com

Abstract: Wolf's isotopic response (WIR) refers to the appearance of a new skin disorder at the exact site of an unrelated skin disorder that had previously been cured. The most common primary skin disease in which WIR occurs is herpes zoster. Despite numerous theories being put forward to explain this occurrence, including viral, vascular, immunological, and neurological hypotheses, the pathogenesis of WIR after herpes zoster remains unclear. We report the case of a 76-year-old patient who presented with keloids at the site of the original herpes zoster. Based on this observation and a review of the literature, The clinical characteristics and possible theoretical reasons for keloids after herpes zoster will be discussed.

Keywords: Wolf's isotopic response, herpes zoster, keloids

Introduction

Herpes zoster is an infectious skin disease caused by the reactivation of varicella zoster virus (VZV), which spreads along sensory nerves to the dermatomes and manifests clinically as multiple blistering rashes with pain in a dermatomal pattern. Wolf's post-herpetic isotopic response refers to the appearance of another disease, unrelated to herpes zoster, in the same area as herpes zoster, based on the healing of herpes zoster or subtle changes (scarring, pigmentation).

Common case reports of this phenomenon currently include granuloma, psoriasis, lichen planus, and skin tumors.¹ Keloids are the result of fibroblast proliferation and excessive collagen deposition, which usually occur at the site of trauma or surgical injury.² In addition, keloid after herpes zoster is a very rare condition. In the present study, we reported a case of keloids after herpes zoster with a lesion in the same location as the previous herpes zoster. We supposed this was a typical example of WIR.

Case Report

A 76-year-old man had a history of progressively expanding and pruritic keloids on the right trunk and arm for 3 years. He was diagnosed with "herpes zoster" 3 years ago at another hospital due to erythema and blisters with pain on the right side of his trunk and arm. Erythema was distributed on the right side of the chest and back, and arm, which is locally fused into bands with a cluster of blisters on it. Erythema unilaterally occurred, with local ulceration and conscious paroxysmal pain. He was treated with vaxilovir for 2 weeks. The patient refused to conduct the histopathological examination. One month later, keloid-like lesions appeared after the erythema and blisters regressed. In the follow-up, he noticed that his scar became prominent, expanded, and gradually began to show keloid features. The patient denied having any serious skin infection at that time, and tried topical asiaticoside ointment. However, he did not experience disease relief, and the keloids progressively increased in size, even beyond the edges of the original lesion. He also had localized itching and pain around the keloids and the entire dermatome, and his breathing was affected, leading to poor sleep. For the last 3 months, the patient received topical injections of the compound betamethasone in the scar, once a month for 3 times. The effect of these injections was little and resulted in localized burst of the scar, crusting and hyperpigmentation. The patient had no previous history of keloids or family history and was HIV-negative. Physical examination: multiple plaques in the right trunk and arm, corresponding to dermatomes T2–T3 and T7, with the largest located in the right chest

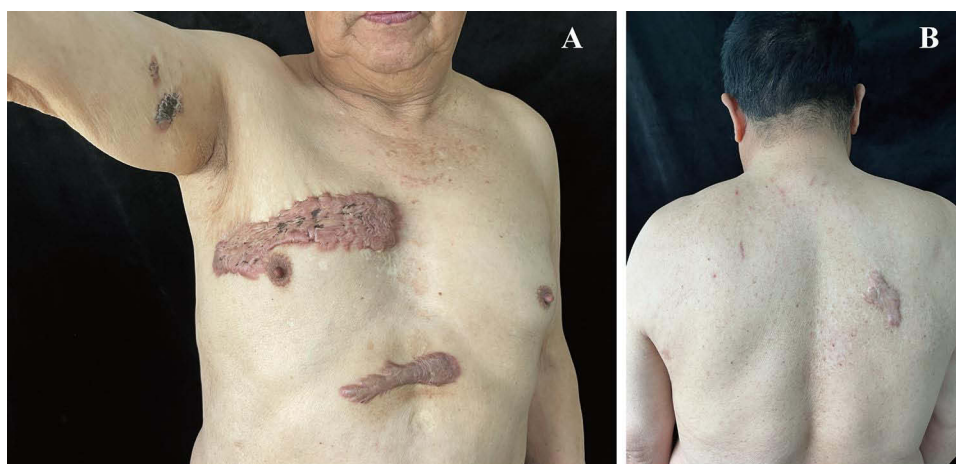

Figure 1 Dermatomal distribution of keloids at the site of healed herpes zoster. **(A)** The patient had multiple plaques in the right trunk and arm, corresponding to dermatomes T2–T3 and T7, with the largest located in the right chest T2–T3 dermatome, measuring 19 cm (L) × 5 cm (W); **(B)** The patient had a right dorsal plaque, not beyond the midline.

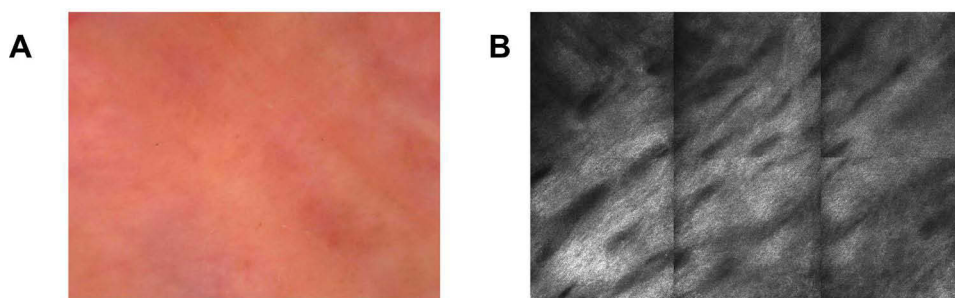


Figure 2 Polarizing dermoscopy and reflectance confocal microscopy examination. **(A)** Polarizing dermoscopy (PD) examination showed that this lesion had erythematous background with white streaks scattered across the blood vessels, indicating the features of fibrosis; **(B)** reflectance confocal microscopy (RCM) results revealed that dermal collagen fibers were arranged in dense bundles.

T2–T3 dermatome, measuring 19 cm (L) × 5 cm (W), with a firm texture and irregular boundaries, together with a small amount of hyperpigmentation, and painful to touch (Figure 1A and B). Further polarizing dermoscopy (PD) examination showed that this lesion had erythematous background with white streaks scattered across the blood vessels, indicating the features of fibrosis. Reflectance confocal microscopy (RCM) results revealed that dermal collagen fibers were arranged in dense bundles (Figure 2A and B). Given the large size of the lesion and the poor results of local steroid injections, local radiation therapy after surgical excision was recommended for this patient. However, he did not accept this treatment scheme.

Discussion

Wolf's isotopic response (WIR), first described in 1955, refers to a new dermatosis occurring in the same location as another healed and unrelated dermatosis. In 1995, Wolf et al recognized this dermatologic phenomenon and provided a precise definition of WIR.³ In 2017, Wolf et al⁴ expanded this criterion of WIR, and argued that scars, pigment changes, and other subtle changes that occur in the secondary dermatosis due to the first should also be included. Keloids, an abnormal proliferation of scar tissue formed after a skin injury, are characterized by fibroblast proliferation and excessive collagen deposition. It is commonly seen on the sternum, shoulders, back of the neck, and earlobes. Many factors, such as trauma, infection, skin tension, darker skin ethnicity, and genetic predisposition, play a crucial role in the development of keloid scars. They are not only aesthetically unpleasant but also accompanied by symptoms of pain, itching, and functional impairments that can significantly affect the patient's quality of life.⁵

Keloids after herpes zoster were rarely reported. According to the current report, we evaluated a total of 8 cases diagnosed with it; the specific clinical features, the time interval after herpes zoster infection, and the immunity are shown in Table 1. It is exhibited that four of these cases were patients combined with HIV. Patients with secondary

Table 1 Characteristics of Reported Cases with Keloids at the Site of the Original Herpes Zoster

Source	Gender	Ethnicity	Age (Years)	Interval	Lesional Area	Immunosuppression
Maamouri 2023 ¹⁰	Female	White	26	4 Months	Forehead	No
Verma 2013 ¹¹	Female	Indian	28	4 Weeks	Trunk	No
Bellavista 2012 ¹²	Male	Black	38	3 Months	Neck	HIV
Komolafe 2011 ¹³	Male	Black	52	8 Weeks	Forehead	No
Koley 2009 ⁸	Male	Indian	31	6 Months	Trunk	HIV
Castro 2009 ¹⁴	Male	Black	65	1 Week	Trunk	HIV
Goel 2002 ¹⁵	Female	Indian	34	2 Months	Trunk	HIV
Our case	Male	China	76	1 Month	Trunk and arm	No

disease of keloids were more inclined to have underlying diseases that lead to immune deficiency. Five cases occurred in the trunk area, commonly in dark skin and Asian skin, but dark skin has a predisposition to congenital keloid formation. This finding is similar with the previous studies demonstrating that keloid scar formation is more commonly seen in individuals of African, Asian, and, to a lesser extent, Latin American or Mediterranean descent, which associates with the darker pigmentation factor.^{6,7} Currently, some case reports about keloids after herpes zoster in patients with immune deficiency, mainly HIV patients. Koley et al⁸ described a rare case of recurrent herpes zoster in an HIV-positive male where the lesions healed with the formation of keloids in both episodes. Another case series reported on herpes zoster infections triggered by HIV infection in four seropositive HIV patients and one patient with recurrent carcinoma after radiotherapy.⁹ However, few case reports have demonstrated keloids after herpes zoster in Chinese patients without immune deficiency. Here, the isotopic response of herpes zoster was manifested by typical keloid manifestation in this patient.

Although case reports of WIR have increased in recent years, due to the lack of large population-based studies of post herpes zoster isotopic response, there is little known about the exact incidence and specific mechanism of it in the literature. Considering that herpes zoster is the most common initial disease, it is suspected that there is a viral association.¹⁶ Herpes zoster is caused by the reactivation of VZV, which is more commonly seen in individuals older than 50 years and immunocompromised patients due to T-cell-mediated immune decline. It usually begins as an erythematous papule in a single or successive dermatomal pattern, spanning multiple areas, usually not exceeding the midline. VZV infection can cause local anatomic changes such as scar formation, microcirculation change, collagen rearrangement, and impaired local immune defense. During the course of herpes zoster, VZV is activated in the dorsal root ganglion, travels through the intraepidermal nerve endings to the basal keratinocytes, and makes massive VZV replication, breaking through the basement membrane to infect dermal dendritic cells, which play an important role in skin healing. VZV can affect the normal function of dendritic cells, leading to the tendency of scarring. In addition, darker skin has more dermal dendritic cells, which possibly explains their greater tendency to scarring.¹⁷ In the present case, the patient with typical clinical manifestations including painful erythema and blisters was first manifested as “herpes zoster” 3 years ago, only after 1 month, keloid-like lesions appeared after the erythema and blisters regressed, indicating the potential relationship between herpes zoster lesions and keloids due to close time course. Of note, this patient exhibited breathing difficulty due to progressively increased keloids. It is important to elucidate that the size of the keloid alone is not the only factor that determines whether it will cause breathing difficulty, the location of the keloid and the extent of skin involvement are also important factors to consider.^{18,19} For instance, severe keloids on the face and neck may cause difficulties in swallowing and breathing.

Multiple theories and evidence also suggest that not only viral factors but also more complex host factors (eg, vascular, immune, or neurological factors) are involved in the development of WIR. Possible mechanisms include the hypothesis of immunocompromised skin,²⁰ in which locoregional skin immune dysregulation occurs after a prior injury event, thereby increasing the risk of subsequent skin lesions, and different pathways can lead to impaired local skin function, such as trauma, infection, or vascular dysfunction. Regardless of the cause, over time the immunocompromised skin area may become a vulnerable site for opportunistic infection, inflammation, tumor, and abnormal immune response,

usually confined to the area itself. Ruocco et al²⁰ explained the neural hypothesis, and it is so far the most favored one, that herpes zoster virus can cause A δ and C nerve destruction in the middle and lower dermis, leading to the release of neuropeptides that regulate local immune and angiogenic responses. Multiple interactions between cutaneous nerves, the neuroendocrine axis and immune system influence the mechanism of new diseases. Mahajan et al²¹ studied these theories in detail and proposed a complex theory of isotopic response occurrence. However, none of the above hypotheses can singularly explain the pathogenesis of isotopic response. One or more, or all the factors, play a role in the causation of a new disease along the “locus minoris resistentiae”.

Conclusion

Herpes zoster is a common infectious disease, and the risk of isotopic reactions may be underestimated. Further studies are needed to understand the exact pathogenesis and epidemiology of this response. We speculated that immunological changes, namely increased sensitivity to the tissue antigens of primary varicella-zoster virus infection, and superficial trauma to the lesion area in the early stage due to herpes zoster, might play an important role in the development of keloids in our patient.

Consent Statements

Written informed consent was provided by the patient to have the case details and any accompanying images published. The case publication was allowed by the Zhejiang Province Dermatology Hospital.

Acknowledgments

The authors are grateful to the patient.

Funding

Research reported in this publication was supported by Huzhou Science and Technology Plan: 2020GY51.

Disclosure

The authors have no conflicts of interest to declare for this work.

References

1. Wang T, Zhang M, Zhang Y, et al. Wolf's isotopic response after herpes zoster infection: a study of 24 new cases and literature review. *Acta Derm Venereol*. 2019;99(11):953–959. doi:10.2340/00015555-3269
2. Ogawa R. Keloid and hypertrophic scars are the result of chronic inflammation in the reticular dermis. *Int J Mol Sci*. 2017;18(3):606. doi:10.3390/ijms18030606
3. Wolf R, Brenner S, Ruocco V, Filioli FG. Isotopic response. *Int J Dermatol*. 1995;34(5):341–348. doi:10.1111/j.1365-4362.1995.tb03616.x
4. Wolf R, Wolf D. “Wolf's isotopic response”: the originators speak their mind and set the record straight. *Clin Dermatol*. 2017;35(4):416–418. doi:10.1016/j.clindermatol.2017.02.003
5. Naik P. Novel targets and therapies for keloid. *Clin Exp Dermatol*. 2022;47(3):507–515. doi:10.1111/ced.14920
6. Chike-Obi CJ, Cole PD, Brissett AE. Keloids: pathogenesis, clinical features, and management. *Semin Plast Surg*. 2009;23(3):178–184. doi:10.1055/s-0029-1224797
7. Kelly AP. Update on the management of keloids. *Semin Cutan Med Surg*. 2009;28(2):71–76. doi:10.1016/j.sder.2009.04.002
8. Koley S, Saoji V, Salodkar A. Unusual formation of keloids after each episode of recurrent herpes zoster in an HIV positive patient. *Indian J Sexually Trans Dis AIDS*. 2009;30(2):109–111. doi:10.4103/0253-7184.62769
9. Muthu Pannarselvam A, Kulanthaivelu J, Rajaram Mohan K, Gopinath A, Caroline ML. Herpes zoster in four HIV seropositive patients and one patient with recurrent carcinoma after radiotherapy. *Cureus*. 2022;14(2):e21922. doi:10.7759/cureus.21922
10. Maamouri R, Zaouak A, Ali A, Frioui R, Cheour M. Keloid scar after herpes zoster ophthalmicus. *J Cosmet Dermatol*. 2023;22(5):1704–1705. doi:10.1111/jocd.15636
11. Verma SB, Wollina U. Herpes zoster in pregnancy leading to keloids and post herpetic neuralgia: a double whammy? *Indian Dermatol Online J*. 2013;4(2):158–159. doi:10.4103/2229-5178.110646
12. Bellavista S, D'Antuono A, Gaspari V, Banzola N, Patrizi A. Acne keloidalis nuchae on herpes zoster scar in an HIV patient: isotopic response or not? *Giornale Italiano di Dermatologia e Venereologia*. 2012;147(2):223–226.
13. Komolafe O, Ogunleye O, Fasina O, Komolafe O. African traditional medication and keloid formation in herpes zoster ophthalmicus. *Niger J Clin Pract*. 2011;14(4):479–481. doi:10.4103/1119-3077.91761
14. Castro JG, Espinoza L. Keloid after herpes zoster in an HIV-infected person. *AIDS Reader*. 2009;19:187.
15. Goel SK, Kuruvila M. Rare sequelae of herpes zoster in HIV positive patient. *Indian J Dermatol Venereol Leprol*. 2002;68:295.

16. Ha Yoon J, Ji Jang Y, Joo Park E, Joong Kim K, Ho Kim K. A Case of herpes zoster granulomatous dermatitis: report of Wolf's isotopic response. *Ann Dermatol*. 2021;33(2):186. doi:10.5021/ad.2021.33.2.186
17. El Hayderi L, Nikkels-Tassoudji N, Nikkels AF. Incidence of and risk factors for cutaneous scarring after herpes zoster. *Am J Clin Dermatol*. 2018;19:893–897. doi:10.1007/s40257-018-0385-2
18. Tirgan MH. Neck keloids: evaluation of risk factors and recommendation for keloid staging system. *F1000Research*. 2016;5:1528. doi:10.12688/f1000research.9086.1
19. Bagger-Sjöbäck D, Takumida M. Geometrical array of the vestibular sensory hair bundle. *Acta Otolaryngol*. 1988;106(5–6):393–403. doi:10.3109/00016488809122262
20. Prieto-Torres L, Bernárdez C, Hernández-Ostiz S, Pastushenko I, Ara-Martin M, Requena L. Necrobiosis lipoidica developing within a surgical scar in a non-diabetic patient: type III Koebner phenomenon (isomorphic response), Wolf's isotopic response or Ruocco's immunocompromised cutaneous district? *Indian J Dermatol Venereol Leprol*. 2017;83:233. doi:10.4103/0378-6323.197389
21. Mahajan R, De D, Saikia UN. Wolf's isotopic response: report of a case and review of literature. *Indian J Dermatol*. 2014;59(3):275. doi:10.4103/0019-5154.131401

Clinical, Cosmetic and Investigational Dermatology

Dovepress

Publish your work in this journal

Clinical, Cosmetic and Investigational Dermatology is an international, peer-reviewed, open access, online journal that focuses on the latest clinical and experimental research in all aspects of skin disease and cosmetic interventions. This journal is indexed on CAS. The manuscript management system is completely online and includes a very quick and fair peer-review system, which is all easy to use. Visit <http://www.dovepress.com/testimonials.php> to read real quotes from published authors.

Submit your manuscript here: <https://www.dovepress.com/clinical-cosmetic-and-investigational-dermatology-journal>