


# Effect of High-Intensity Macro-Focused Ultrasound on a Case of Morbihan Disease

Min Li, Meng Tao, Yue Zhang, Ruoxin Pan, Duoduo Gu , Yang Xu

Department of Dermatology, the First Affiliated Hospital of Nanjing Medical University (Jiangsu Province Hospital), Nanjing, 210029, People's Republic of China

Correspondence: Yang Xu, Department of Dermatology, the First Affiliated Hospital of Nanjing Medical University (Jiangsu Province Hospital), 300 Guangzhou Road, Nanjing, 210029, People's Republic of China, Tel/Fax +86-13851856794, Email yangxu@njmu.edu.cn

**Abstract:** Morbihan disease is a rare entity involving the upper two-thirds of the face and characterized by chronic erythematous edema, which is recalcitrant to the traditional therapy of rosacea. We report a case of Morbihan disease effectively treated with macro-focused high-intensity focus ultrasound (MF-HIFU). After MF-HIFU treatment, an obvious reduction in swelling was observed with decreased erythema and hyperalgesia. In addition, in-vitro experiments were conducted to measure the actual temperature of the skin tissue under the epidermis. The results of the in-vitro experiments showed that the temperature plateau in the skin sample was reached at approximately 42°C after 5-min treatment or longer. MF-HIFU might be a promising energy-based therapy for Morbihan disease.

**Keywords:** erythema, edema, rosacea, energy-based treatment

## Introduction

Morbihan disease, also referred to as rosacea lymphedema, is a rare entity involving the upper two-thirds of the face and characterized by chronic erythematous edema, which is recalcitrant to the traditional therapy of rosacea. Oral drugs (isotretinoin, thalidomide, clofazimine, ketotifen, etc.) and surgical intervention have been used alone or in combination with each other to treat Morbihan disease.<sup>1</sup> Obstruction of lymphatic vessels is considered one of the potential mechanisms of Morbihan disease, so it seems that improvement of lymphatic drainage would be an effective adjunctive therapy which has been proved in patients with breast cancer-related lymphedema only showing increased lymphatic contraction frequency after hyperthermia therapy.<sup>2-4</sup> We therefore hypothesized that proper heating of the subepidermal tissue to approximately 40°C might be a potential therapy for Morbihan disease.

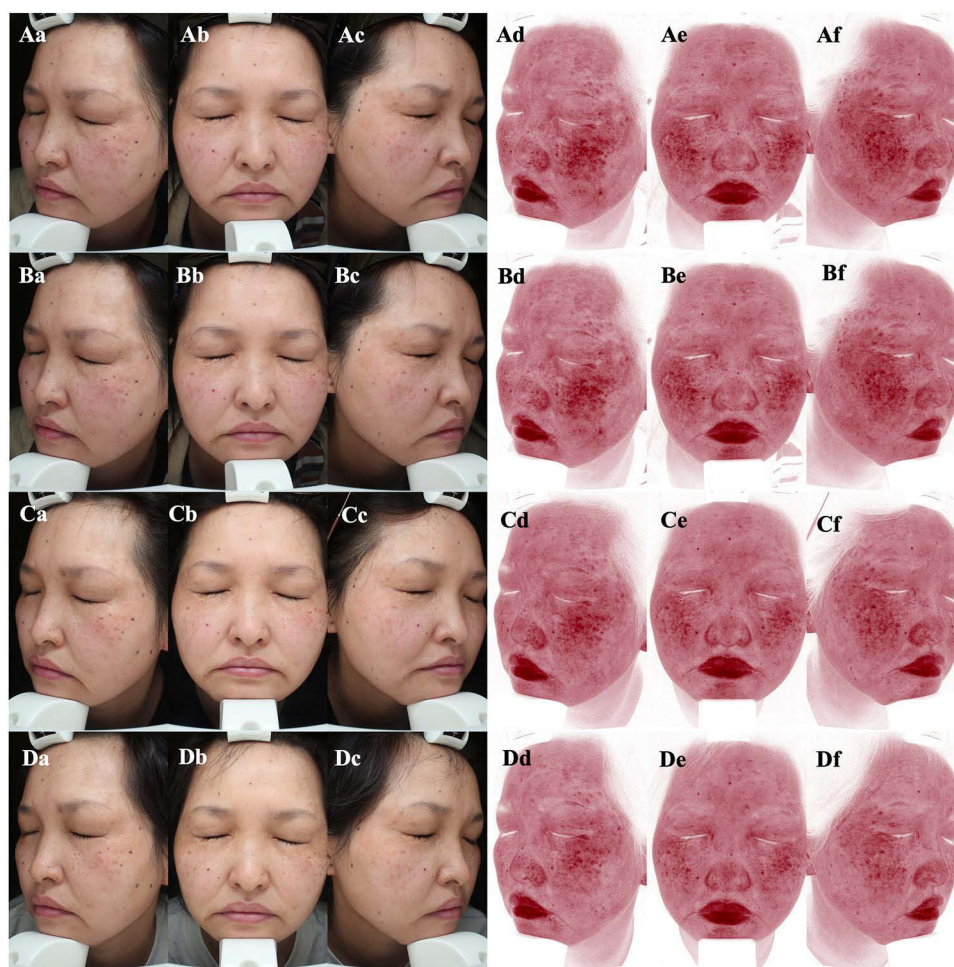
Here, we present a case of Morbihan disease recalcitrant to traditional therapy that was effectively treated with macro-focused high-intensity focus ultrasound (MF-HIFU), considering that lymph obstruction might be improved by proper heating of the tissue under the epidermis. We also conducted an in vitro study to investigate the potential mechanism of the treatment and reviewed the current literature.

## Materials and Methods

### Case Report

A 56-year-old female patient presented to the Dermatology Department of our hospital with complaints of erythema and edema of the cheeks with discomfort, including swelling and hyperalgesia, for 10 years. She had been diagnosed with rosacea and treated intermittently with hydroxychloroquine and minocycline. Facial erythema improved, while the swelling of the cheeks and hyperalgesia did not. Oral antidepressants, such with a fixed-dose combination tablet of melitracen/flupentixol were also used for approximately 6 months, with no improvement. Exposure to hot and cold weather, sunlight, and cosmetics increased the discomfort.

Physical examination revealed firm swelling and erythema of the cheeks and forehead without any obvious scaling, papules, or pustules (Figure 1Aa–Ac). In the red area images taken by the VISIA® Complexion Analysis System (Canfield

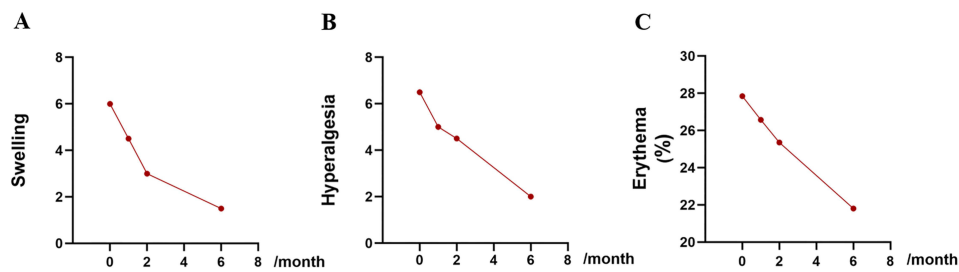


**Figure 1** Clinical and erythema area images of the patient taken by the VISIA® Complexion Analysis System. (A) Before MF-HIFU treatment (Aa–Ac: Clinical manifestation images; Ad–Af: Red area images). (B) One month after the first treatment (Ba–Bc: Clinical manifestation images; Bd–Bf: Red area images). (C) One month after the second treatment (Ca–Cc: Clinical manifestation images; Cd–Cf: Red area images). (D) Six-month follow-up (Da–Dc: Clinical manifestation images; Dd–Df: Red area images). **Abbreviation:** MF-HIFU, macro-focused high-intensity focus ultrasound.

Scientific, NJ, USA), the erythema was more obvious (Figure 1Ad–Af). Sense of swelling and hyperalgesia were measured using a visual analog scale (VAS) and were 6.0 and 6.5 on a 10-point scale, respectively. The patient underwent routine blood examination, antinuclear antibodies, thyroid function test, full blood count, and CT scan of the lungs. The results were normal. Skin biopsy demonstrated a non-specific inflammatory reaction in the dermis, consistent with rosacea, and Morbihan disease was diagnosed. The patient refused further oral medications including isotretinoin, for possible side effects and personal reasons. Therefore, all systemic medications were discontinued, and a trial treatment using micro- and macro-focused high-intensity ultrasound (Peninsula Med, Shenzhen, China) therapy was initiated. An MF-HIFU tip was used (4 MHz, 3-mm focal depth, and intensity of 3.76 W) for 5 min on both cheeks. Hydrogel was applied evenly on both sides of the cheeks with a thickness of 2 mm, and the tip was in continuous smooth motion on the cheek without overheating one site. All areas, except the periorbital region, were treated. Maintenance treatment was administered for a further 2 months, every 4 weeks, and then discontinued due to improvement in clinical manifestations without relapse at 6 months follow-up (Figure 1Ba–Bc, Ca–Cc, and Da–Dc) and a reduction in erythema intensity (Figure 1Bd–Bf, Cd–Cf, and Dd–Df). At the 6-month follow-up, an obvious reduction in swelling was observed with decreased erythema and hyperalgesia (Figure 2).

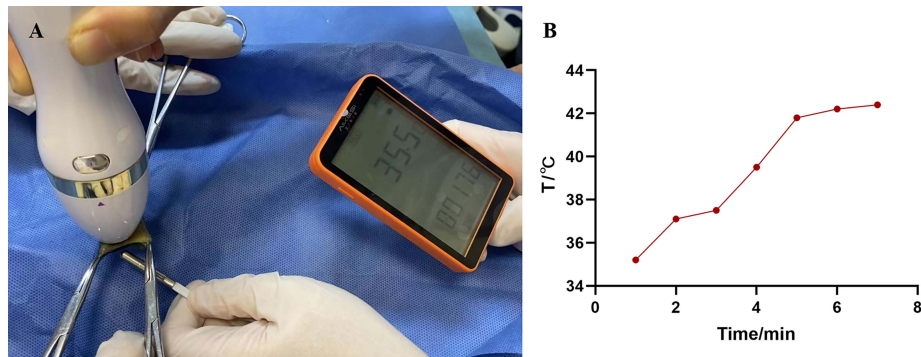
## In-Vitro Experiments

Further in-vitro experiments were conducted to measure the actual temperature of the skin tissue under the epidermis. Surplus skin tissue from mastectomy were used with informed consent from the patients. The skin tissue was cut into



**Figure 2** (A) VAS score for swelling at the 6-month follow-up. (B) VAS score for hyperalgesia at the 6-month follow-up. (C) Facial erythema extent at the 6-month follow-up.

**Abbreviation:** VAS, visual analog scale.



**Figure 3** (A) Skin tissue treated with MF-HIFU and the temperature measuring device. (B) Temperature in the skin tissue beneath the epidermis.

**Abbreviation:** MF-HIFU, macro-focused high-intensity focus ultrasound.

blocks of approximately  $3 \times 2 \times 1$  cm and treated with MF-HIFU under the same conditions as those used for the Morbihan patients (4 MHz, 3-mm focal depth, 3.76 W intensity, Figure 3A). Temperature changes were recorded using an electric thermometer (Aikesi Electronic Technology, Changzhou, China), and the time-temperature curve was recorded (Figure 3B). After 5-min treatment, the temperature in the skin sample was 41.8°C; with more treatment time, a temperature plateau was reached at approximately 42°C.

## Literature Review

Although the pathogenesis of Morbihan disease is not fully understood, it is characterized by erythema and solid edema of the upper two-thirds of the face, probably caused by bivascular dysregulation, fibrosis, and obstruction of lymphatic vessels.<sup>2</sup> Differential diagnosis includes sarcoidosis, systemic lupus erythematosus, cutaneous leishmaniasis, foreign body granuloma, and Melkersson–Rosenthal syndrome.

A review of the literature was undertaken by searching PubMed using the keywords “Morbihan disease”, “high-intensity ultrasound”, “micro-focused ultrasound”, and “macro-focused ultrasound”, and revealed several Morbihan disease cases that were effectively treated with systemic therapy and surgical excision from 2004 to 2022 (Table 1), while no energy-based treatment has been reported to be effective.<sup>4–17</sup>

## Discussion

Ultrasound has mechanical, cavitation, and thermal effects. High-intensity micro-focused ultrasound was first used for noninvasive skin rejuvenation by White et al in 2007.<sup>18</sup> It accurately focuses the heat in the dermal area and superficial musculoaponeurotic system, with minimal damage to surrounding structures. The wound-healing cascade activates fibroblast differentiation and collagen synthesis, together with skin tightening. HIFU has also been approved for dermatological and aesthetic usage in China, and has two handle pieces, micro- and macro-focused. The former is similar to the instrument approved by the FDA, while the latter has a more diffuse focus area, that is, a larger heated area

**Table 1** Clinical Characteristics of Previously Reported Cases of Morbihan Disease

Source	Age/Race/Sex	Unilateral/ Bilateral	Clinical Manifestation	Treatment	Report/ Series
Bechara et al <sup>6</sup>	67-year-old Caucasian male	Unilateral	Right lower and upper eyelid swelling and erythema	CO <sub>2</sub> laser blepharoplasty	Report
Nagasaka et al <sup>4</sup>	70-year-old Japanese man	Bilateral	Non-pitting oedema on the periorbital areas and telangiectasia with red papules on the cheeks and the nose	Oral minocycline 100 mg twice daily and oral tranilast 100 mg three times daily, with additional oral prednisolone 10 mg twice daily	Report
Rebellato et al <sup>7</sup>	38-year-old Caucasian male	Bilateral	Periorbital indurated edema	Isotretinoin 20 mg/day for 6 months, ketotifen 1 mg/day for the first 2 months	Report
Vasconcelos et al <sup>8</sup>	39-year-old Caucasian male	Bilateral	Swelling of the upper eyelids	Not mentioned	Report
Kim et al <sup>9</sup>	Six Koreans, aged 42–73 years	All bilateral	Persistent, extensive eyelid oedema	Surgical excision	Series
Weeraman et al <sup>10</sup>	46-year-old Caucasian male	Unilateral	Right infra-orbital cheek swelling	Surgical excision and intralesional injection of 40 mg triamcinolone	Report
Yvon et al <sup>11</sup>	10 Caucasians (male=8, female=2), ages 48–88 years	6 unilateral, 4 bilateral	Gradual progressive lid swelling	Oral isotretinoin, intralesional triamcinolone injections, and debulking surgery	Series
Kafi et al <sup>12</sup>	56-year-old Caucasian female	Bilateral	Persistent and prominent erythematous oedema of the face	Omalizumab 450 mg subcutaneously	Report
Welsch et al <sup>5</sup>	4 White patients, mean age 63 years	Bilateral	Solid edema and erythema in the two upper thirds of the face	10 mg of isotretinoin and 5 mg of desloratadine for 14 months 16 months	Report
Çınar et al <sup>13</sup>	18-year-old White male	Bilateral	Periorbital edema	Complete decongestive therapy	Report
Donthi et al <sup>14</sup>	2 Caucasian males, aged 67 and 50 years	Bilateral	Periorbital edema	100 mg doxycycline twice daily, brimonidine 0.33% topical gel, 2.5% hydrocortisone cream	Report
Macca et al <sup>15</sup>	45-year-old Caucasian male	Unilateral	Right eyelid elastic swelling	Oral isotretinoin 0.3 mg/kg/day	Report
Zhou et al <sup>16</sup>	55-year-old Chinese female	Bilateral	Non-pitting edema and erythema of the upper two thirds of the face	Total glucosides of paeony capsules for 2 months	Report
Suzuki et al <sup>17</sup>	70-year-old Japanese patient	Bilateral	Upper eyelid swelling	Oral tetracycline	Report

which produces a smaller increase in temperature in the dermal and subcutaneous layers, with a maximum temperature of less than 42.4°C, in a time-dependent manner, as revealed by our in-vitro experiment.

The most common histological findings of Morbihan disease were dermal edema, sebaceous hyperplasia, perivascular lymphocytes and histiocytes, and granulomatous reaction.<sup>19</sup> Previous research reported that complete decongestive therapy (CDT) can be considered as an effective therapeutic tool for the treatment of Morbihan disease, which consists of manual lymphatic drainage, compression therapy, skin care, exercise, and self-care.<sup>1</sup> Apart from pressurization, it has



been reported that heat can increase lymphatic drainage. Besides, it was demonstrated that compared to other temperatures, such as 24°C and 30°C, a temperature of 40°C significantly increased the transportation of lymph.<sup>20,21</sup> Local hyperthermia can significantly increase lymphatic contraction frequency in those patients with breast cancer-related lymphedema patients while without lymphatic complications.<sup>6</sup> Elevated skin temperature increases the dilatation of capillaries, thereby improving blood and lymph circulation and alleviating swelling. Another study found that assessment by electromagnetic diathermy heat could accelerate venous return, which might be the mechanism for treating lymph edema.<sup>22</sup> The improvement in swelling and discomfort after MF-HIFU treatment confirmed our hypothesis that the proper heating of the subepidermal tissue to approximately 40°C might be a potential therapy for Morbihan disease.

## Conclusion

In conclusion, MF-HIFU might be a promising energy-based therapy for Morbihan disease. However, this study had some limitations. First, the generalizability of the effect of MF-HIFU on Morbihan disease is limited as this is the only case reported in the literature. Second, we failed to measure the dermis and epidermis temperatures both independently and simultaneously due to the constraints of the measuring conditions.

## Ethics Approval and Informed Consent

The patient reported in this manuscript gave written informed consent to participate in this study, and for the details of her case and accompanying photographs to be published. Institutional approval is not required to publish the case details in accordance with local legislation and institutional requirements.

## Acknowledgments

The authors wish to thank the patient, all participating investigators, and the study team involved in the conduct of this study.

## Disclosure

The authors report no conflicts of interest in this work.

## References

1. Kutlay S, Ozdemir EC, Pala Z, et al. Complete decongestive therapy is an option for the treatment of rosacea lymphedema (Morbihan Disease): two cases. *Phys Ther.* 2019;99(4):406–410. doi:10.1093/ptj/pzy155
2. Mayur O, Martinez R, McNichol MC, et al. Clinical and histological features and treatment outcomes of patients with Morbihan disease: a systematic review. *Arch Dermatol Res.* 2023. doi:10.1007/s00403-023-02621-6
3. Johannessen AL, Alstrup M, Hjortdal VE, et al. Lymphatic function decreases over time in the arms of breast cancer patients following treatment. *Plast Reconstr Surg Glob Open.* 2022;10(9):e4507. doi:10.1097/GOX.0000000000004507
4. Nagasaka T, Koyama T, Matsumura K, et al. Persistent lymphoedema in Morbihan disease: formation of perilymphatic epithelioid cell granulomas as a possible pathogenesis. *Clin Exp Dermatol.* 2008;33(6):764–767. doi:10.1111/j.1365-2230.2008.02892.x
5. Welsch K, Schaller M. Combination of ultra-low-dose isotretinoin and antihistamines in treating Morbihan disease - A new long-term approach with excellent results and a minimum of side effects. *J Dermatolog Treat.* 2021;32(8):941–944. doi:10.1080/09546634.2020.1721417
6. Bechara FG, Jansen T, Losch R, et al. Morbihan's disease: treatment with CO2 laser blepharoplasty. *J Dermatol.* 2004;31(2):113–115. doi:10.1111/j.1346-8138.2004.tb00518.x
7. Rebellato PR, Rezende CM, Battaglin ER, et al. Syndrome in question. *An Bras Dermatol.* 2015;90(6):909–911. doi:10.1590/abd1806-4841.20153818
8. Vasconcelos RC, Eid NT, Eid RT, et al. Morbihan syndrome: a case report and literature review. *An Bras Dermatol.* 2016;91(5 suppl 1):157–159. doi:10.1590/abd1806-4841.20164291
9. Kim JE, Sim CY, Park AY, et al. Case series of Morbihan disease (Extreme Eyelid Oedema Associated with Rosacea): diagnostic and therapeutic approaches. *Ann Dermatol.* 2019;31(2):196–200. doi:10.5021/ad.2019.31.2.196
10. Weeraman S, Birnie A. Rosacea causing unilateral Morbihan syndrome. *BMJ Case Rep.* 2019;12:e231074.
11. Yvon C, Mudhar HS, Fayers T, et al. Morbihan syndrome, a UK case series. *Ophthalmic Plast Reconstr Surg.* 2020;36(5):438–443. doi:10.1097/IOP.0000000000001589
12. Kafi P, Edén I, Swartling C. Morbihan syndrome successfully treated with omalizumab. *Acta Derm Venereol.* 2019;99(7):677–678. doi:10.2340/00015555-3168
13. Çınar GN, Özgül S, Nakip G, et al. Complex decongestive therapy in the physical therapist management of rosacea-related edema (Morbihan Syndrome): a case report with a new approach. *Phys Ther.* 2021;101:zab133. doi:10.1093/ptj/pzab133
14. Donthi D, Nenow J, Samia A, et al. Morbihan disease: a diagnostic dilemma: two cases with successful resolution. *SAGE Open Med Case Rep.* 2021;9:2050313x211023655. doi:10.1177/2050313X211023655

15. Macca L, Li Pomi F, Motolese A, et al. Unilateral Morbihan syndrome. *Dermatol Rep*. 2022;14(2):9270. doi:10.4081/dr.2021.9270
16. Zhou LF, Lu R. Successful treatment of Morbihan disease with total glucosides of paeony: a case report. *World J Clin Cases*. 2022;10(19):6688–6694. doi:10.12998/wjcc.v10.i19.6688
17. Suzuki M, Watari T. Morbihan syndrome. *J Gen Intern Med*. 2023;38(1):233. doi:10.1007/s11606-022-07858-x
18. Hu SW, Robinson M, Meehan SA, et al. Morbihan disease. *Dermatol Online J*. 2012;18(12):27. doi:10.5070/D37RC0M3KS
19. White WM, Makin IRS, Barthe PG, et al. Selective creation of thermal injury zones in the superficial musculoaponeurotic system using intense ultrasound therapy: a new target for noninvasive facial rejuvenation. *Arch Facial Plast Surg*. 2007;9(1):22–29. doi:10.1001/archfaci.9.1.22
20. Olszewski W, Engeset A, Jaeger PM, et al. Flow and composition of leg lymph in normal men during venous stasis, muscular activity and local hyperthermia. *Acta Physiol Scand*. 1977;99(2):149–155. doi:10.1111/j.1748-1716.1977.tb10365.x
21. Yasuda A, Ohshima N. In situ observations of spontaneous contractions of the peripheral lymphatic vessels in the rat mesentery: effects of temperature. *Experientia*. 1984;40(4):342–343. doi:10.1007/BF01952541
22. van der Veen P, Kempnaers F, Vermijlen S, et al. Electromagnetic diathermia: a lymphoscintigraphic and light reflection rheographic study of leg lymphatic and venous dynamics in healthy subjects. *Lymphology*. 2000;33(1):12–18.

## Clinical, Cosmetic and Investigational Dermatology

Dovepress

### Publish your work in this journal

Clinical, Cosmetic and Investigational Dermatology is an international, peer-reviewed, open access, online journal that focuses on the latest clinical and experimental research in all aspects of skin disease and cosmetic interventions. This journal is indexed on CAS. The manuscript management system is completely online and includes a very quick and fair peer-review system, which is all easy to use. Visit <http://www.dovepress.com/testimonials.php> to read real quotes from published authors.

Submit your manuscript here: <https://www.dovepress.com/clinical-cosmetic-and-investigational-dermatology-journal>