

Burkholderia cepacia Induced Occipital Subcutaneous Abscess and Fracture in a Brain-Dead Woman

Wu Yang^{1,*}, Tingting Liu^{1,*}, Chun Zhan², Hui Jiang¹, Wang Zhang³, Qing Yang⁴, Xia Zheng¹

¹Department of Critical Care Medicine, The First Affiliated Hospital, Zhejiang University School of Medicine, Hangzhou, Zhejiang, 310000, People's Republic of China; ²Department of Critical Care Medicine, Hang Zhou Integrative Medicine Hospital, Hangzhou, Zhejiang, 310000, People's Republic of China; ³Department of Infectious Diseases, Sir Run Run Shaw Hospital, Zhejiang University School of Medicine, Hangzhou, Zhejiang, 310000, People's Republic of China; ⁴Department of Laboratory Medicine, The First Affiliated Hospital, Zhejiang University School of Medicine, Hangzhou, Zhejiang, 310000, People's Republic of China

*These authors contributed equally to this work

Correspondence: Xia Zheng, Department of Critical Care Medicine, The First Affiliated Hospital, Zhejiang University School of Medicine, No. 79, Qingchun Road, Shangcheng District, Hangzhou, Zhejiang, People's Republic of China, Tel +86-13958174689, Fax +86-571-87236838, Email zxicu@zju.edu.cn

Abstract: *Burkholderia cepacia* is an aerobic opportunistic Gram-negative pathogen that mainly infects immunodeficiency patients. However, soft tissue infections with fractures due to *Burkholderia cepacia* are rare with no cases reported. Here, we report a rare case of 3 years of brain death in a 43-year-old woman with *Burkholderia cepacia* resulting in an occipital subcutaneous abscess and fracture. Through the second-generation sequencing of the whole genome of this strain, it was found that there were no high virulence genes and virulence factors. The patient received targeted antibiotic therapy and showed improvement in clinical symptoms and radiological signs. Bone destruction because of *Burkholderia cepacia* is easily overlooked due to the lack of characteristic symptoms and limited clinical examination. This case reminds us that *Burkholderia cepacia* without major virulence factors could damage the bone in immune-compromised patients.

Keywords: brain death, *Burkholderia cepacia*, subcutaneous abscess, generation sequencing, case report

Introduction

Burkholderia cepacia (*B. cepacia*), a Gram-negative aerobic bacillus, is a well-known opportunistic pathogen of immune-compromised patients including cystic fibrosis, chronic granulomatous disease, and lung transplantation patients.¹ Several cases report that *B. cepacia* could induce extrapulmonary-tissue abscesses, such as brain, bilateral psoas, chest intra-abdominal, and deep neck.²⁻⁸ However, soft tissue infections with fractures caused by *B. cepacia* are extremely rare with no instances reported. We report a middle-aged female with a medical history of 3-year brain dead who developed a subcutaneous abscess with a bone fracture in her right occipital region.

Case Report

A 40-year-old female was diagnosed with viral encephalitis-induced secondary brain death on September 11, 2019, based on the American Academy of Neurology (AAN) criteria for the determination of brain death in adults.² Her clinical manifestations presented as comatose, lack of brainstem reflexes, and cannot breathe spontaneously. The head CT showed diffuse edema of brain tissue and gray matter with white matter structure blurred (Figure 1A). The electroencephalogram (EEG) indicated resting-state brain electrical activity. Her family finally decided to transfer to the Hang Zhou Integrative Medicine Hospital. She received mechanical ventilation and rehabilitation exercise during hospitalization lasting for almost 3 years. The patient had a high fever on September 12, 2022. Physical examination revealed intense swelling of her right occipital region and the abscess was approximately four centimeters in diameter. The brain computed tomography (CT) imaging showed the right temporoparietal cerebral hemorrhage and occipital defect with a subcutaneous abscess in Figure 1B, and laboratory workup

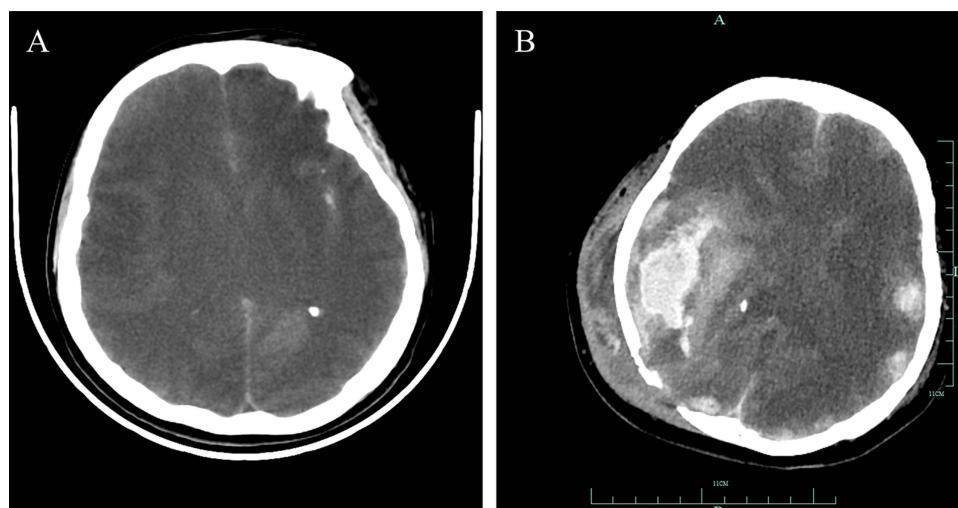


Figure 1 Brain CT images of the patient. **(A)** Brain CT imaging on October 15, 2019. The head CT imaging was showed diffuse edema of brain tissue, gray matter and white matter structure blurred. **(B)** Brain CT on September 14, 2022. The brain CT imaging was showed the right temporo-parietal cerebral hemorrhage and occipital defect with subcutaneous abscess.

showed white blood cell, $9.0 \times 10^9/L$; neutrophils, 87.8%; lymphocytes, 9.1%; red blood cell, $2.84 \times 10^{12}/L$; hemoglobin, 86 g/L; platelet, $183 \times 10^9/L$; C-reactive protein, 100.2 mg/L; procalcitonin, <0.25 ug/L. The sampling of abscess fluid was conducted, and bloody pus was obtained (Figure 2). The pus's direct smear examination and culture showed *B. cepacia*. The colony was susceptible to cefoperazone-sulbactam, meropenem, ceftazidime, minocycline, and TMP-SMX (Table 1). To confirm the result, we further conducted metagenomic next-generation sequencing (NGS) of the abscess aspiration and revealed *B. cepacia* (Table 2). We analyzed its virulence genes and the major virulence factors focusing on the function of motility, such as *fliM*, *flhA*, *motA*, *fliA*, *flgG*, and *flgI*. We further found that the drug-resistant genes of this strain were *mphL*, *satA_Ba*, *BcII*, and *blaI* via the second-generation sequencing of the whole genome.³

The cerebrospinal fluid examination (CSF) was performed to rule out intracranial infection, and no positive results were seen in the CSF, including CSF routine, culture, *Cryptococcus neoformans*, *Mycobacterium tuberculosis* and NGS. She was




Figure 2 The sampling of bloody pus.

Table 1 *Burkholderia cepacia* Susceptibility Results by the MIC Test

Antibiotic	MIC (ug/mL)	Interpretation	Antibiotic	MIC (ug/mL)	Interpretation
Cefoperazone-sulbactam	16	S	Ceftazidime	2	S
Imipenem	≥16	R	Aztreonam	16	R
Meropenem	2	S	Tobramycin	≥16	R
Doxycycline	8	I	Ciprofloxacin	≥4	R
Tigecycline	≥8	R	Levofloxacin	≥8	R
Amikacin	≥64	R	Minocycline	4	S
Ticarclillin	≥128	R	TMP-SMX	≤20	S
Piperacillin-tazobactam	≥128	R	Cefepime	≥32	R

Abbreviations: S, susceptible; I, intermediate; R, resistance; MIC, minimal inhibitory concentration; TMP-SMX, trimethoprim-sulfamethoxazole.

Table 2 Pathogenic Microorganisms Identified in a Subcutaneous Abscess Sample

Genus			Species		
Name	Relative Abundance	Sequence Number	Name	Identify Confidence	Sequence Number
<i>Burkholderia</i>	43.7%	1824	<i>Burkholderia cepacia</i>	99%	858

then treated with Cefoperazone-sulbactam 2.0g q8h for 5 days depending on the result of the antimicrobial susceptibility testing for *B. cepacia*. By this series of treatments, she had no fever, and the inflammation presented white blood cells, $5.5 \times 10^9/L$; neutrophils, 79.6%; lymphocytes, 17.4%; red blood cells, $3.0 \times 10^{12}/L$; hemoglobin, 89 g/L; platelet, $135 \times 10^9/L$; C-reactive protein, 40 mg/L; procalcitonin, <0.25 ug/L. The inflammatory markers were significantly lower than before with no apparent swollen sign of the right occipital area in several days. Worth mentioning is that the patient neither reviewed for the CT nor got enough treatment courses to objectively evaluate the therapeutic effect of the soft tissue abscess with a bone fracture because family members decided to abandon treatments.

Discussion

Extrapulmonary infection caused by *B. cepacia* is a rare, life-threatening disease usually found in immunocompromised patients.^{1,3} *B. cepacia*-induced infections are difficult to treat because the pathogen is resistant to multiple antibiotics inherently.³

Several cases report that *B. cepacia* could cause abscesses in the brain, bilateral primary psoas, chest intra-abdominal, and even deep neck.^{3–8} One report of a case of septic arthritis of the knee caused by *B. cepacia* complex in a patient and his X-ray showed soft tissue swelling but no discrete fracture.⁹ However, the histopathological examination of the tissue from another case of *B. cepacia* causing frontal mucopyocele with anterior cranial fossa extension showed the surrounding bone destruction despite brain images with no bone fracture.¹⁰ We encountered an uncommon case of subcutaneous abscess in the right occipital region of a brain-dead woman due to a *B. cepacia* infection with no special virulence factors. We originally suspected a secondary subcutaneous abscess following an intracranial infection, yet a couple of rounds of CSF examinations showed negative, we then finally confirmed that the abscess with bony destruction was directly caused by *B. cepacia*. This case demonstrates that *B. cepacia* without major virulence factors could cause bone injury in immunocompromised patients.

Conclusion

Immunocompromised patients, such as those with AIDS, organ transplantation, long-term hormone treatment, malignant tumors, or diabetes, are at high risks for intracranial infection. Intracranial infection caused by *Bacillus cepacia*, especially

bone destruction, is a rare infection. Early diagnosis and adequate antibiotic therapy could reduce the morbidity of immunocompromised patients suffering from disseminated *B. cepacia*.

Consent Statement

The patient's husband provided written informed consent to allow the case details and any accompanying images to be published.

Clinical research ethics committee of The First Affiliated Hospital, Zhejiang University School of Medicine approved this study (IIT20221198A).

Funding

There is no funding to report.

Disclosure

The authors report no conflicts of interest in this work.

References

1. Pareek P, Gupta B, Chetan C, et al. Burkholderia cepacia brain abscess in a term neonate. *Indian J Pediatr*. 2020;87(6):478–479. doi:10.1007/s12098-019-03156-3
2. Greer DM, Shemie SD, Lewis A, et al. Determination of brain death/death by neurologic criteria: the world brain death project. *JAMA*. 2020;324(11):1078–1097. doi:10.1001/jama.2020.11586
3. Rohit A, Rani MS, Anand NS, et al. Burkholderia vietnamiensis causing a non-lactational breast abscess in a non-cystic fibrosis patient in Tamil Nadu, India. *Indian J Med Microbiol*. 2020;38(3 and 4):496–499. doi:10.4103/ijmm.IJMM_20_329
4. Agrawal S, Kapil A, Dhawan B, et al. Burkholderia cepacia: an uncommon cause of bilateral primary psoas abscesses in a patient with a pott spine that cannot be ignored. *Natl Med J India*. 2018;31(2):124–125. doi:10.4103/0970-258X.253158
5. Fadini GP, Tiengo A, Avogaro A, et al. First isolation of Burkholderia cepacia from a deep neck abscess in a diabetic patient successfully treated with hyperbaric oxygen. *J Clin Microbiol*. 2005;43(1):529. doi:10.1128/JCM.43.1.529.2005
6. Mukhopadhyay C, Bhargava A, Ayyagari A. Two novel clinical presentations of Burkholderia cepacia infection. *J Clin Microbiol*. 2004;42(8):3904–3905. doi:10.1128/JCM.42.8.3904-3905.2004
7. Hobson R, Gould I, Govan J. Burkholderia (Pseudomonas) cepacia as a cause of brain abscesses secondary to chronic suppurative otitis media. *Eur J Clin Microbiol Infect Dis*. 1995;14(10):908–911. doi:10.1007/BF01691499
8. Simmonds NJ, Gyi KM. Cystic fibrosis, a Burkholderia cenocepacia chest wall abscess and rapid clinical deterioration. *J R Soc Med*. 2008;Suppl 1(suppl 1):S46–S50. doi:10.1258/jrsm.2008.s18011
9. Koo J, Deans GD. A rare case of Burkholderia cepacia complex septic arthritis. *Case Rep Infect Dis*. 2018;2018:6232760. doi:10.1155/2018/6232760
10. Saratziotis A, Zanotti C, Baldovin M, et al. Burkholderia cepacia causes frontal mucopyocele with anterior cranial fossa extension: a novel case report. *Iran J Otorhinolaryngol*. 2021;33(118):327–332. doi:10.22038/ijorl.2021.51654.2753

Infection and Drug Resistance

Dovepress

Publish your work in this journal

Infection and Drug Resistance is an international, peer-reviewed open-access journal that focuses on the optimal treatment of infection (bacterial, fungal and viral) and the development and institution of preventive strategies to minimize the development and spread of resistance. The journal is specifically concerned with the epidemiology of antibiotic resistance and the mechanisms of resistance development and diffusion in both hospitals and the community. The manuscript management system is completely online and includes a very quick and fair peer-review system, which is all easy to use. Visit <http://www.dovepress.com/testimonials.php> to read real quotes from published authors.

Submit your manuscript here: <https://www.dovepress.com/infection-and-drug-resistance-journal>