

Targeted Treatment of Advanced Endometrial Cancer: Focus on Pembrolizumab

Nathan El-ghazzi¹, Xavier Durando¹⁻⁴, Alexia Giro²⁻⁴, Tressie Herrmann¹

¹Oncology Department, Centre Jean Perrin, Clermont-Ferrand, France; ²Clinical Research and Innovation Department, Centre Jean Perrin, Clermont-Ferrand, France; ³INSERM U1240 IMoST, University of Clermont Auvergne, Clermont-Ferrand, France; ⁴UMR 501, Clinical Investigation Centre, Clermont-Ferrand, France

Correspondence: Nathan El-ghazzi, Oncology Department Centre Jean PERRIN 58 Rue Montalembert 63000 ClermontFerrand, Auvergne, France, Tel +3304.73.27.80.05, Fax +33 04.73.27.80.29, Email Nathan.EL-GHAZZI@clermont.unicancer.fr

Abstract: Endometrial cancer (EC) accounts for 2% of all new cancers. Advanced forms have a poor prognosis with barely 17% 5-year survival. The last few years improved our knowledge of EC with a new molecular classification derived from The Cancer Genome Atlas (TCGA). They are now divided between *POLE* mutant, Microsatellite Instability High (MSI-H) or deficient in Mismatch Repair System (dMMR), *TP53* mutant and no specific molecular profile. Until now, treatments for advanced EC have included conventional platinum-based chemotherapy or hormonotherapy. The revolution in oncology represented by the advent of immune checkpoints inhibitors (ICI) has also led to a major advance in the management of recurrent and metastatic EC. Pembrolizumab, a well-known anti PD-1, has firstly been approved as monotherapy in the second-line setting for dMMR/MSI-H advanced EC. More recently, a combination of lenvatinib with pembrolizumab offered a new effective option in the second line setting irrespectively of the MMR status, giving a new opportunity for these patients who had no actual standard of care before. This combination is currently being evaluated as frontline therapy. Despite exciting results, the main problem in identifying solid biomarkers remains unresolved and further investigations are required. New original combinations of pembrolizumab with other drugs including chemotherapy, poly ADPribose polymerase inhibitors (PARP-i) or tyrosine kinase inhibitors are being tested and promise exciting new therapeutic evolutions in a close future.

Keywords: endometrial cancer, pembrolizumab, precision medicine, immunotherapy

Introduction

Carcinoma of the uterine corpus or endometrial cancer (EC) accounts for 2% of all new cancer cases and is usually detected at early-stages within the uterus. EC ranks seventh among all female cancers worldwide with most cases diagnosed on average at age 70.¹ In Europe, EC ranks fourth among female cancers with an incidence of 12.920.2:100 000.² Mortality is low because most of the cases are localized, allowing a 5 year-survival of 95% with local disease and 69% with regional disease. Unfortunately, 8–10% of the patients present with advanced or recurrent disease with a poor prognosis of 17% 5-year overall survival (OS) demonstrating the lack of effective systemic treatment. It has been reported that the incidence of EC is increasing annually by 1–2%.^{3,4} This is partly explained by the aging of the population as well as the rise of obesity, which is a risk factor for development and death in patients (6.25 higher risk of death⁵). Other risk factors⁵ are estrogen-related and include nulliparity, infertility associated with polycystic ovarian syndrome or tamoxifen use. Hypertension and hyperinsulinemia⁶ have also been described. Finally, it is of importance to note that even though more than 90% of ECs are sporadic, 5% to 10% of them are hereditary⁷ being part of Lynch syndrome also known as hereditary non-polyposis colorectal cancer syndrome (HNPCC). It is associated with a germline mutation in the mismatch repair (MMR) genes. They tend to develop in younger women and it justifies more vigilance in detecting Lynch syndrome, especially in women under 50 years of age presenting with EC.⁸

The landscape of medical cancer treatments has deeply evolved over the past few years with the advent of immune checkpoint inhibitors (ICI) for instance, in lung cancer⁹ or melanoma.¹⁰ The last couple of years have yet demonstrated

a proper role for ICI in ECs, especially for pembrolizumab, an anti-programmed-death 1 (PD1). This review aims to give clear insight on how pembrolizumab is changing our standards of care in advanced ECs.

From a Histologic 2-Categories Classification ...

To understand how pembrolizumab may be involved in the treatment of EC, a better understanding of the histology is needed. For decades, the histopathological classification created by Bokhman, which divides EC into two groups, was used.¹¹ Endometrioid subtype was included in type I, while every other subtype fit into type II. Tumors were classified from grade 1 (G1) to grade 3 (G3) but since the last histological classification, EC are grouped into low-grade tumors (usually G1 and G2) or high-grade tumors (formerly G3).^{12,13} Estrogen Receptor (ER) and Progesterone Receptor (PgR) are usually assessed as well. If type I ECs are most of the time low grade and confined to the uterus with a good prognosis under treatment (5 year-OS 86%), type II ECs are associated with a poorer outcome (5 year-OS 59%).^{3,14,15} In addition, multiple histologic factors have been identified as having a high risk of recurrent disease, including lympho-vascular space invasion (LVSI), further complicating the management of local disease. Substantial LVSI is a major poor prognostic factor¹⁶ defined as widespread invasion of tumor emboli into the vascular spaces at and beyond the invasive tumor front. LVSI is called substantial when four or more vessels are LVSI-positive per slide versus three or fewer for focal LVSI.¹⁷ The presence of substantial LVSI may warrant adjuvant therapy in stage II ECs consisting of radiotherapy ± chemotherapy.¹⁸ However, describing the histology accurately is often found difficult for pathologists as morphologic classification is not well reproducible.¹⁹ All of these results in an imperfect characterization of tumor biology, creating a wide diversity and heterogeneity within type I and type II groups. Consequently, choosing a targeted treatment for EC used to be a challenge.

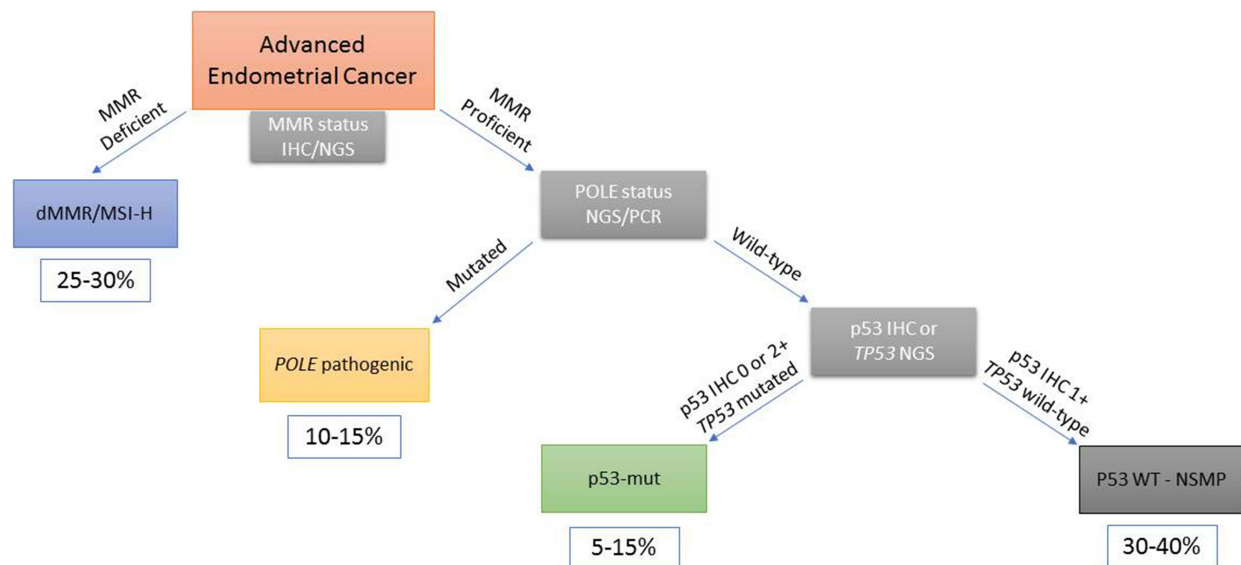
... To Four Molecular Subcategories

For the past few years, it has become clear that histologic classification does not recap the molecular heterogeneity of EC and that its lack of reproducibility prevents clinical trials from improving precision medicine. The Cancer Genome Atlas (TCGA) project proposed a new classification based on the sequencing of 373 women with EC a few years ago which is now adopted and used in clinical practice and trials. It is based on somatic mutational burden and somatic copy number variations (CNV). It allows a distinction of four molecular groups:⁷ ultramutated (>100 mutations/megabase (Mut/Mb)) with pathogenic alterations in the exonuclease domain of DNA polymerase epsilon (*POLE*); hypermutated (10–100 mut/Mb) microsatellite-unstable; somatic copy number-high with frequent pathogenic variants in *TP53*; and somatic copy number-low with frequently phosphoinositide 3-kinase (*PI3K*) and WNT signaling abnormalities.¹⁸

Obtaining MSS status and *TP53* mutations are possible by immunohistochemistry, but sequencing is becoming necessary for *POLE* alteration. The treatment strategy for patients with recurrent/metastatic ECs is now based on these four prognostic groups.²⁰ Different classifiers have been used over the last few years. The two main ones are based on the TCGA research network and summarize the molecular subgroups of EC. In the Proactive Molecular Risk Classifier for Endometrial Cancer (ProMisE)²⁰ classifier, tumors are classified in stages as described below (Figure 1). In the Leiden classifier,²¹ based on patients in the PORTEC-1²² and -2²³ studies, all molecular markers are determined for each sample, and cases with multiple molecular alterations are excluded from the classification (Figure 2). Both classifiers can predict the risk of recurrence in a molecular prediction model. This is of utmost importance in the early-stages EC where, based on the risk stratification, patients should receive or not adjuvant ChT. The use of these classifiers promises to reduce both overtreatment and undertreatment and will be used in future prospective trials. Both have been validated in large retrospective and prospective studies.^{20,21,24}

POLEmut

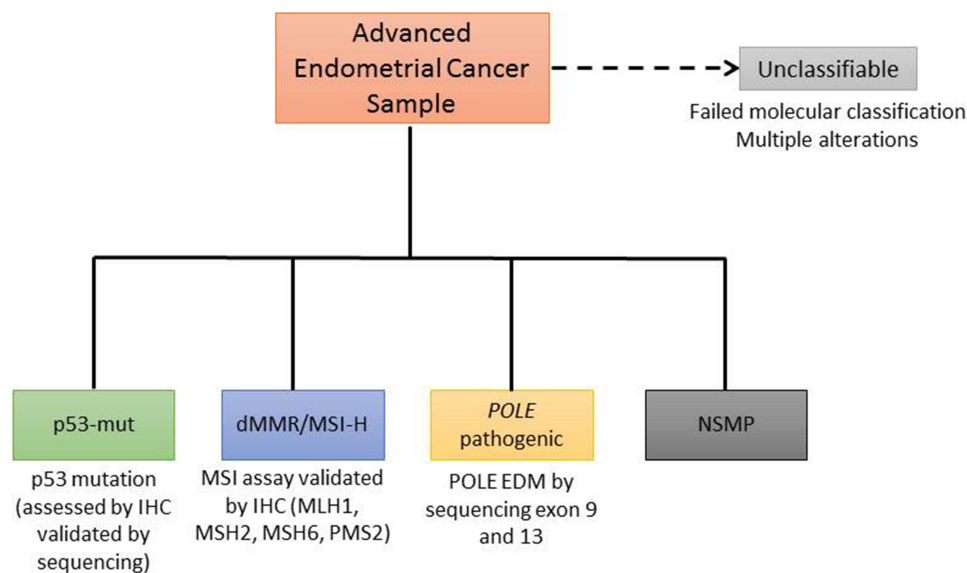
These tumors represent between 10% and 15% of the TCGA cohort, carry high mutational burden and are associated with good prognosis and the longest progression-free survival (PFS) times. Histology is mostly endometrioid, often of high grade with prominent tumor infiltrating lymphocytes (TILs). Patients have a lower body mass index (BMI) and diagnosis comes at an earlier stage. Detection of a pathogenic mutation in the exonuclease domain of *POLE* is sufficient to classify tumors into this group.^{25,26}



dMMR : mismatch repair system deficient ; pMMR : mismatch repair system proficient; MSI-H : microsatellite instability high; IHC : immunohistochemistry; NGS : new generation sequencing; PCR : polymerase chain reaction; WT : wild type; mut : mutant; NSMP : no specific molecular profile

Figure 1 Molecular classification of EC based on the ProMisE molecular classifier by Kommos et al. This classification is based on several successive biomarker investigations. First, ECs are categorized between MMR proficient and MMR deficient tumors. 25–30% belong to the latter. When pMMR, POLE mutations need to be searched through NGS or PCR. Between 10 and 15% of ECs belong to the POLE mutated subgroup. If samples are pMMR and do not harbor POLE mutations, IHC for p53 allows the distinction between p53-mut group (5–15%) and NSMP group (30–40%).

Notes: Modified with permission from Kommos S, McConechy MK, Kommos F, et al. Final validation of the ProMisE molecular classifier for endometrial carcinoma in a large population-based case series. *Ann Oncol.* 2018;29(5):1180–1188. Copyright © 2018 THE AUTHORS. Published by Elsevier Ltd. All rights reserved.²⁰



IHC : immunohistochemistry

Figure 2 Schematic of the Leiden molecular classification. All molecular markers are determined for each sample at the same time and not in a stepwise fashion. If a sample present with multiple alterations, it is considered unclassifiable.

Microsatellite Instability-High (MSI-H) or Mismatch Repair Deficient Tumors (dMMR)

They represent 25% to 30% of samples in the TCGA cohort. Such as the POLEmut group, they present with endometrioid high-grade histology and a large proportion of TILs. BMI is higher than in *POLE*mut group and when there is a germline mutation in the MMR spectrum (MLH1, MSH2, MSH6 or PMS2) patients are diagnosed with Lynch syndrome. In this case, investigations should be conducted to screen for other spectrum cancers, including family members. Prognosis is intermediate for these patients who benefit a lot from ICI.^{27,28} Immunohistochemistry (IHC) for MMR genes is a simple and efficient way to screen patients. Complete loss of expression of one or more of these MMR proteins is sufficient for the diagnosis of dMMR EC.²¹ In addition to IHC, MMR system deficiency can be analyzed on sequencing data.

TP53 Aberrant (or p53-Mut)

This group has the worst prognosis²⁹ and accounts for 5–15% of patients. The mutation rate here is less than 10 Mut/Mb but includes a high percentage of *TP53* mutation and a high somatic copy number. This type of EC is characterized by HER2 amplification and cell cycle deregulation. Histology is usually high-grade serous or mixed, but any type can be found. Immunostaining for p53 is an excellent surrogate marker for *TP53* mutations and can be used in clinical routine.³⁰

No Specific Molecular Profile (NSMP)

This is the most represented group with 30% to 40% of the samples in the TCGA. These tumors have an intermediate prognosis and can be classified through the absence of microsatellite instability, the absence of *TP53* abnormalities and the absence of *POLE* mutation on its hotspots. Mutation rate is also very low (less than 10 Mut/Mb) with a low somatic copy number. Histology is mostly low-grade endometrioid with an important expression of ER/PgR and an absence of TILs.

Front-Line Therapy for Advanced EC: Standards of Care

Currently, conventional chemotherapy (ChT) remains the mainstay of the treatment strategy for recurrent/metastatic EC. Treatment combination is recommended for most women if they are fit. Carboplatin AUC5-6 and paclitaxel 175mg/m² every 21 days for six cycles should be considered as frontline therapy with an overall response rate (ORR) of 40–50%, median PFS and OS being, respectively, 14 and 32 months.³¹ In the GOG0209 study, it was non inferior to the more intensive course consisting in paclitaxel-doxorubicin-cisplatin but quality of life and tolerance with paclitaxel carboplatin were much easier.

Another option relies on hormone therapy as first-line therapy. Their activity has mostly been reported for low-grade endometrioid tumors and depends on the status of ER and PgR even though its association with the quality of response is not as well demonstrated as in breast cancer.³² Endocrine therapy provides a 10–20% response rate with an overall survival of less than 1 year.³³ A recent meta-analysis demonstrated a mean ORR of 21%, it was greater when ER was positive (26%) or PgR was positive (35%). In second-line setting, ORR was merely 18.5%.³⁴ Endocrine treatment is usually progestins such as megestrol acetate, but can also rely on aromatase inhibitor,³⁵ tamoxifen or fulvestrant.

Hormonal therapy should be considered for low-grade carcinomas with endometrioid histology, especially with indolent or low-volume diseases. It can also be proposed to elderly patients unfit for ChT. For cases in which endocrine therapy does not have any good indication, front-line ChT should always be discussed with the patient and be based on a combination therapy of carboplatin-paclitaxel.

Of note, latest National Comprehensive Cancer Network (NCCN) guidelines from 2022 included total abdominal hysterectomy (TAH) for EC with distant metastasis in addition to systemic treatment. If most studies are retrospective and are based on conventional ChT associating paclitaxel and carboplatin, the results are encouraging. In a recent large retrospective cohort of more than 3000 stage IVB patients, median OS was almost twice better in the TAH plus ChT group versus the ChT alone group (11 versus 19.8 months, HR=0.59).³⁶ The benefit was consistent whether ChT was used before or after TAH. It seemed even greater when local treatment was completed with locoregional radiation therapy. There is a major selection bias in this study which might have selected younger and fitter patients, able to receive a locoregional treatment for whom the disease volume is often found lacking. Still, other studies³⁷ and meta-analysis³⁸

seem to present similar results, offering locoregional treatment as a valid option to be discussed despite the need of prospective data.

Beyond First-Line Therapy: Before ICI

In a similar way to ovarian cancer, most prescribers use a concept of platinum sensitivity, allowing re-treatment with platinum.³⁹ If progression occurs more than 6 months after first line platinum-based regimen, then it is tolerable to reintroduce it. Retrospective studies even showed that the longer the platinum-free interval is, the better the response rate will be. As demonstrated by Nagao et al, an interval of less than 6 months allows a response rate of 25%, while an interval of more than 24 months a response rate of 65%.⁴⁰

When platinum salts are no longer effective, other ChT are used as monotherapy. In this case, doxorubicin or taxanes are accepted in the palliative setting.⁴¹

Therefore, before the advent of immunotherapy, institutions such as ESMO or NCCN considered that there was no standard of care for systemic treatment in advanced EC beyond first-line therapy.

The Road to Pembrolizumab

As mentioned before, about 30% of ECs are categorized as MSI-H/dMMR which highlights the immune dysregulation and the potential role for ICI as monotherapy or in combination. One major step was the approval by the Food and Drug Administration (FDA) of pembrolizumab in the treatment of advanced MSI-H or dMMR tumors. This was one of the first approval of a tumor-agnostic histology-independent cancer therapy.

KEYNOTE-158²⁸ was conducted as a multicentric basket Phase II study and included dMMR/MSI-H cancers across 27 different histology at the exception of colorectal cancers. The most represented cancer was EC, being 21% of 233 patients (before gastric cancers and cholangiocarcinoma). Patients received pembrolizumab at the dose of 200mg every 21 days. Primary objective was ORR, which rose to 34% with a median PFS of 4 months and an OS of 23 months in heavily pretreated patients (1 patient out of 3 had already received 3 or more regimen courses). Tolerance was consistent with that usually observed with ICI. There was 65% toxicity of all grades, mostly asthenia, pruritus, and diarrhea, including barely 15% of high-grade toxicity.

An update of KEYNOTE-158 was recently published⁴² focusing on the EC cohort. Among the 90 patients, ORR was 48% including 11% complete responses. Regardless of the number of treatment lines received before, the results were concordant. Median PFS reached 12.1 months whereas median OS was not reached yet. Authors estimated that 3 responders out of 4 would remain responsive for at least 24 months. The main limitation of this study was the absence of a control arm, which was impossible to obtain because of the pantumoral population studied. Nevertheless, the approval of pembrolizumab in this indication was possible because of the robustness of the results in a category of heavily pretreated patients with no established standard of care to date. The Food and Drug Administration (FDA) and the European Medicines Agency (EMA) both approved pembrolizumab as an option as second-line treatment in dMMR or MSI-H ECs. MSI-H/dMMR status tends to be an actual solid predictive factor and biomarker for ICI response across all histology.

Single-agent pembrolizumab for second-line MSI-H/dMMR ECs is now the heart of the matter as the combination of pembrolizumab and lenvatinib is recommended for second-line treatment regardless of MMR status as well. Lenvatinib is a selective inhibitor of vascular endothelial growth factor receptors 1–3 and other receptor tyrosine kinases such as fibroblast growth factor receptor 1–4, platelet-derived growth factor receptor alpha, KIT or RET and is a potent angiogenesis inhibitor. In addition to being an effective immunomodulator, it suppressed and delayed tumor growth in preclinical models when combined with pembrolizumab. This effect is due to a decrease in tumor associated macrophages and an increase in T-cell populations.⁴³

In a phase Ib/II study, 108 patients with progressing ECs after platinum treatment received lenvatinib 20mg once daily plus pembrolizumab 200mg every 21 days. At week 24, ORR was 38% for all patients. Of note, in the MSI-H subgroup ORR raised up to 63.6% against 36.2% in MSS tumors. Median duration of response (DOR) was 21.2 months, and median PFS and OS were, respectively, 7.4 and 16.7 months. Half of the tumors were endometrioid and half were

PD-L1 positive. More importantly, the combination was not that well tolerated, with nearly 67% of grade 3 or 4 treatment related adverse events.⁴⁴

The Phase III trial (KEYNOTE-775)⁴⁵ randomly assigned 827 patients in a 1:1 ratio with advanced EC who had previously received at least one platinum-based chemotherapy regimen to receive either lenvatinib plus pembrolizumab or chemotherapy of the treating physician's choice (doxorubicin or paclitaxel). Fifteen percent of the tumors were dMMR. In all patients, Hazard Ratio (HR) was 0.56 (95% CI, 0.47–0.66) for PFS in favor of the combination with a median PFS of 7.2 months against 3.8 months for conventional ChT. These results were confirmed in OS with a median OS of 18.3 months in the combination group against 11.4 months in the ChT group (HR=0.62 (95% CI, 0.51–0.75)). Median DOR was 14.4 months in the lenvatinib plus pembrolizumab group. As in the phase II study, the benefits appeared to be greater in the dMMR population with long responders and a median DOR not reached yet at the end. An objective response was obtained in 31.9% of the whole population (30.3% when MMR proficient (pMMR) and 40% when dMMR). The disease control rate was 72% in the whole population receiving the combination. These efficacy results are quite impressive in this setting with an unmet medical need. The main limiting condition remains the toxicity of the combination of pembrolizumab and lenvatinib with 88.9% of grade III adverse events (AE) (against 72% in the ChT group). The most represented grade III AE was hypertension (37.9%), loss of appetite (7.9%) and weight decrease (10.3%). When we focus on any grade AE, more than half of the patients present with hypertension, hypothyroidism, diarrhea, and nausea. These AEs resulted in lenvatinib dose reductions within a median of 1.9 months (range 0.1–22.8). Two or more dose reductions were required for 45.6% of patients in the lenvatinib-pembrolizumab arm.

The median dose was 13.8 mg per day. With dose adaptation, toxicity appeared manageable. However, there were 5.7% deaths in the lenvatinib plus pembrolizumab arm. Treatment was discontinued in the combination group in 69.2% of the patients (lenvatinib in 30.8%, pembrolizumab in 18.7%, both in 14%). Regardless of all these side effects, the health-related quality of life tests had no substantial differences between ChT group and lenvatinib-pembrolizumab group. Results were updated at ESMO 2022 after a median follow-up of 14.7 months. PFS benefit continued in the combination arm with a median PFS of 7.3 months with this follow-up extended by 16 months. In the all-comer population, 7.5% of the patients reached a complete response and 26.3% a partial response confirming a consistent ORR of 33.8%. In this final analysis of OS, lenvatinib plus pembrolizumab achieved clinically meaningful improvements in OS, PFS and ORR in platinum-treated patient with advanced EC. There were no new safety signals. These results confirm the robustness of the interim analysis and validate the benefit of using this combination in the second-line setting.

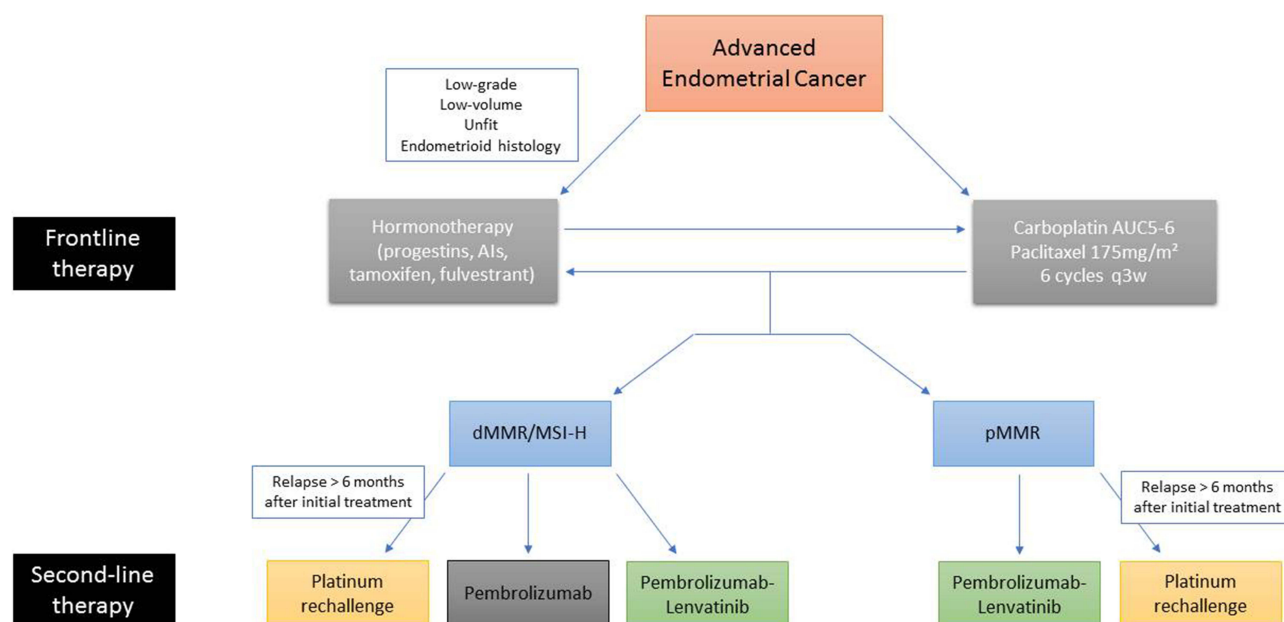
In conclusion, advanced ECs can have access to second-line pembrolizumab regardless of MMR status in combination with lenvatinib. Data remain lacking for the dMMR population, which can theoretically receive either pembrolizumab alone or in association with lenvatinib. Given the results of ICI monotherapy for dMMR/MSI-H tumors, combination therapy with lenvatinib should remain an option only for young and fit patients who can tolerate such a combination. Therapeutic strategies for advanced/recurrent ECs are resumed in Figure 3.

The main ongoing challenge is to validate this combination as a first-line treatment for advanced ECs. The ENGOT-en9/LEAP-001 study (NCT03884101) hypothesizes that pembrolizumab plus lenvatinib is superior to first-line paclitaxel-carboplatin ChT for PFS and OS in the pMMR or dMMR populations. Around 800 to 900 patients are supposed to be recruited, with results expected later this year. This trial may change the treatment strategy in first-line advanced EC.⁴⁶

Going Further in Biomarkers?

Despite excellent results for the dMMR/MSI-H populations, approximately one in three patients will not respond to ICI monotherapy. In the pMMR population the number is even higher. Moreover, only about 20% of patients achieve deep and long-term response to pembrolizumab.⁴⁵ The search for reliable and accurate predictive biomarkers is of utmost importance for a better patient's selection.

PD-L1 tumoral status as a predictive biomarker has been studied. EC shows one of the highest rates of positivity of PD-L1 among the gynecological tumors (around 50%). In a meta-analysis including more than 1500 patients, PD-L1 was not correlated with OS or PFS but was associated with poor differentiation and advanced tumor stage.⁴⁷ Data around PD-L1 and its significance for ICI response are controversial. KEYNOTE028, which specifically studied pembrolizumab in PDL-1 positive EC, demonstrated an ORR of 26% in the PD-1 positive population without any strong correlation.⁴⁸



dMMR : mismatch repair system deficient; MSI-H : microsatellite instability high; q3w : every three weeks

Figure 3 Systemic treatment strategies for advanced/metastatic endometrial cancers.

KEYNOTE-158 investigated response to ICI according to the PD-L1 status but there were too many missing data (around 70% of PD-L1 status not assessed in the EC cohort) in advanced EC to have clear insight.^{28,42} Finally, phase Ib/II study of lenvatinib-pembrolizumab combination revealed no significant difference in terms of ORR between PD-L1 positive and negative populations.⁴⁹ Based on these data, PD-L1 does not appear to be a reliable biomarker for predicting patient's response to ICI and should not be used as a decisive parameter.

Tumor mutational burden (TMB) is another biomarker often investigated. In KEYNOTE158, the authors focused on TMB⁵⁰ and its relation to pembrolizumab response. In this trial, 805 patients were evaluable for TMB. Thirteen percent of them had TMB-high (more than 10 mutations per megabase) tumors. ORR was higher for patients with TMB-high tumors (20%; 95% CI 21–39) than the others (6%; 95% CI 5–8). According to a large analysis of human cancer genomes, a correlation between MMR deficiency, TMB-high and *POLE* mutations has been shown. In these cases, the assessment of TMB becomes a biomarker of lesser interest.⁵¹ Furthermore, some tumors are pMMR without any *POLE* mutations and are still classified as TMB-high. If most MSI-H tumors are TMB-high, only 18% of TMB-high tumors are MSI-H. In a study of 60 patients from different histology, MSS/TMB-high patients treated with pembrolizumab had a better PFS than MSS/TMB-low tumors (26.8 months vs 4.3 months respectively). The definition between high and low TMB remains a key point of distinction. In this study, it was set at 20 mutations/Mb for example. Further investigations are required to determine the predictive role of TMB in the response to ICI, especially in special cases of ECs not belonging to the dMMR or *POLE*-mutated groups.⁵²

The composition of the microenvironment, such as the infiltration rate of TILs, can be analyzed as a prognostic value.⁵³ Alterations in *ARID1A* have been shown to impact TIL infiltration and PD-L1 expression. These variants have therefore been studied as a potential predictive biomarker for ICI treatment in different tumor types. Further studies are required specifically in EC.^{54,55}

To go further, the prognosis under ICI among the MSI-H population is not the same between hereditary Lynch syndrome and sporadic MMR pathway alteration. A study specifically tried to answer that question and compared the outcome with pembrolizumab in germline mutated and somatic or sporadic (*MLH1*-methylated) patients. Only 24 patients were evaluated including 6 patients harboring Lynch syndrome, while 18 patients had sporadic disease. TMB

was higher in the Lynch group. ORR was 100% in Lynch patients against 44% in sporadic patients ($p=0.024$). Defect in antigen presentation and altered interferon responses served as mechanisms of resistance to ICI in sporadic MSI-H ECs. While the number of patients in this study is small, it nevertheless demonstrates some heterogeneity within the dMMR population and provides a strong rationale for further investigation in this setting to improve ICI response.⁵⁶

Pembrolizumab: Hopes for the Future?

Little is known about primary or secondary resistance mechanisms to pembrolizumab in advanced ECs. Many combinations are currently being investigated in an attempt to either restore sensitivity to pembrolizumab or to prolong initial response. Associations of ICI with ChT, radiotherapy, PARP inhibitors and tyrosine-kinase inhibitors are the most frequently evaluated (Table 1).

Association with Conventional ChT

Through immunomodulatory properties, ChT can enhance the immune response to ICI. Indeed, it can upregulate the major histocompatibility complex (MHC) class I and thereby improve the recruitment of effector T cells. This mechanism is clearly established for platinum compounds for example.⁵⁷

A frontline association is under investigation with paclitaxel-carboplatin-pembrolizumab (NCT02549209) in ECs. This study included localized but unresectable ECs as well as stage III/IV ECs. Forty-one percent of the patients had already received platinum compound in the localized setting. ORR was 75% among the 46 patients but results need to be taken with caution considering the different stages included in the study. Still, such a ChT-ICI combination therapy is already efficient and used in other histology as a frontline treatment, including lung cancer or cervix cancer.^{58,59} Another American phase III study is about to begin enrollment in a randomized controlled trial to investigate the addition of pembrolizumab to first-line paclitaxel-carboplatin in stage III/IV or recurrent EC (NCT03914612). Biomarkers would be warranted to validate such an approach.

A Spanish phase II trial (NCT03276013; TOPIC) evaluated the efficacy of pembrolizumab combined with doxorubicin for patients with at least one prior line of systemic treatment.

Association with Other Targeted Therapies

Combination with antibody–drug conjugates (ADC) are currently being investigated. Mirvetuximab soravtansine is an antibody–drug conjugate comprising a folate receptor alpha (FR α)-binding antibody, cleavable linker, and the

Table 1 Current Combinations with Pembrolizumab Under Investigation

Trial	Phase	Setting	Combination
NCT02549209	II	Frontline Localized / aEC	Paclitaxel-Carboplatin
NCT03276013 (TOPIC)	II	Pretreated aEC	Doxorubicin
NCT03835819	II	aEC / pMMR	Mirvetuximab-soravtansine
NCT05156268	II	Pretreated aEC / p53-mut	Olaparib
NCT05419817	II	dMMR EC progressing under ICI	Sitravatinib
NCT05036681	II	pMMR pretreated aEC	Futibatinib
NCT04014530 (ATAPEMBRO)	I–II	Pretreated dMMR aEC	Ataluren
NCT03914612	III	Frontline Stage III–IV EC	Paclitaxel-Carboplatin
NCT04652076 (GYNET)	I–II	Pretreated Advanced / Metastatic EC	NP137 (Anti-Netrin1)
NCT04781088	II	Pretreated Advanced / Metastatic EC	Lenvatinib-Paclitaxel

Abbreviations: pMMR, MMR proficient; dMMR, MMR deficient; p53-mut, p53 mutated, ICI, immune checkpoint inhibitor; aEC, advanced endometrial cancer.

maytansinoid DM4, a potent tubulin-targeting agent. A phase II trial is currently underway for its combination with pembrolizumab in advanced or recurrent ECs that are pMMR (NCT03835819).

The combination of pembrolizumab with the poly ADP-ribose polymerase inhibitor (PARP-i) olaparib is being evaluated for EC as well as endometrial carcinosarcoma. ECs must belong to the p53 aberrant molecular group. *POLE* mutations and MSI-H tumors are excluded. Patients must have received at least one but no more than three prior regimens (NCT05156268).

For dMMR ECs progressing under anti PD-1 or PD-L1 treatment, a combination of pembrolizumab and sitravatinib is being investigated in a phase II study. Sitravatinib is an oral anti-angiogenesis therapy administered orally and is a potent inhibitor of receptor tyrosine kinases including MET, Axl, MERTK, VEGFR family, PDGFR family or KIT. The hypothesis is that it may overcome ICI resistance through its role on angiogenesis and immunostimulatory effects through Axl and MET inhibition (NCT05419817). In addition, antiangiogenic drugs modify the tumor microenvironment by increasing TILs, and promoting both dendritic cell maturation and T-cell infiltration.⁶⁰

Another phase II study is exploring the combination of pembrolizumab with futibatinib in patients with EC MSS ECs who have received at least one line of systemic ChT previously (NCT05036681). Futibatinib is a potent FGFR 2 inhibitor already approved in intra-hepatic cholangiocarcinoma with a *FGFR2* mutation. This combination has also been tested in urothelial carcinoma.⁶¹

Association with Radiation Therapy

To our knowledge, there are no ongoing trials in advanced ECs combining ICI and radiotherapy. In contrast, a Phase I trial is currently using the combination of pembrolizumab with lenvatinib associated with a hypofractionated pelvic external beam radiation therapy as frontline therapy (beginning at day 22, 2.5 Gy/fraction 16 fractions) in locally unresectable advanced diseases. Patients included cannot have a deficiency in the MMR system and must have recurrent or de novo unresectable EC (NCT05603910).

Conclusion

The understanding of the molecular heterogeneity of ECs had deeply improved for the past few years. If the use of pembrolizumab was initially restricted to the dMMR/MSI-H population, it has recently been approved for all advanced ECs as a second-line regimen in association with lenvatinib. It might soon reach frontline therapy for all advanced ECs in the next few months depending on the results of the ENGOYen9/LEAP-001 study. However, a better understanding of the mechanisms of resistance to ICIs and a better understanding of tumor microenvironment seem to be necessary to obtain robust biomarkers to use molecular classifications as powerful tools for personalized precision medicine. The access to pembrolizumab is also being explored in the context of localized and/or adjuvant therapy. It is therefore of utmost importance to better stratify patients to determine their potential benefit from ICI at different stages of their disease.

Disclosure

The authors report no conflicts of interest in this work.

References

1. Morice P, Leary A, Creutzberg C, Abu-Rustum N, Darai E. Endometrial cancer. *The Lancet*. 2016;387(10023):1094–1108. doi:10.1016/S0140-6736(15)00130-0
2. Bray F, Ferlay J, Soerjomataram I, Siegel RL, Torre LA, Jemal A. Global cancer statistics 2018: GLOBOCAN estimates of incidence and mortality worldwide for 36 cancers in 185 countries. *CA Cancer J Clin*. 2018;68(6):394–424. doi:10.3322/caac.21492
3. Makker V, Green AK, Wenham RM, Mutch D, Davidson B, Miller DS. New therapies for advanced, recurrent, and metastatic endometrial cancers. *Gynecol Oncol Res Pract*. 2017;4(1):19. doi:10.1186/s40661-017-0056-7
4. Lauby-Secretan B, Scoccianti C, Loomis D, Grosse Y, Bianchini F, Straif K. Body fatness and cancer — viewpoint of the IARC Working Group. *N Engl J Med*. 2016;375(8):794–798. doi:10.1056/NEJMsrl606602
5. Arthur RS, Kabat GC, Kim MY, et al. Metabolic syndrome and risk of endometrial cancer in postmenopausal women: a prospective study. *Cancer Causes Control*. 2019;30(4):355–363. doi:10.1007/s10552-019-01139-5

6. Friberg E, Orsini N, Mantzoros CS, Wolk A. Diabetes mellitus and risk of endometrial cancer: a meta-analysis. *Diabetologia*. 2007;50(7):1365–1374. doi:10.1007/s00125-0070681-5
7. Levine DA. Integrated genomic characterization of endometrial carcinoma. *Nature*. 2013;497(7447):67–73. doi:10.1038/nature12113
8. González-Cao M, Moran T, Dalmau J. Update on genetic testing in gynecologic cancer. *J Clin Oncol*. 2022;65. 10.1200/JCO.19.00363.
9. Gandhi L, Rodríguez-Abreu D, Gadgeel S, et al. Pembrolizumab plus chemotherapy in metastatic non-small-cell lung cancer. *N Engl J Med*. 2018;378(22):2078–2092. doi:10.1056/NEJMoa1801005
10. Larkin J, Chiarion-Sileni V, Gonzalez R, et al. Combined nivolumab and ipilimumab or monotherapy in untreated melanoma. *N Engl J Med*. 2015;373(1):23–34. doi:10.1056/NEJMoa1504030
11. Bokhman JV. Two pathogenetic types of endometrial carcinoma. *Gynecol Oncol*. 1983;15(1):10–17. doi:10.1016/0090-8258(83)90111-7
12. Soslow RA, Tornos C, Park KJ, et al. Endometrial carcinoma diagnosis: use of FIGO grading and genomic subcategories in clinical practice: recommendations of the International Society of Gynecological Pathologists. *Int J Gynecol Pathol*. 2019;38:S64. doi:10.1097/PGP.0000000000000518
13. Barlin JN, Zhou Q, St. Clair CM, et al. Classification and Regression Tree (CART) analysis of endometrial carcinoma: seeing the forest for the trees. *Gynecol Oncol*. 2013;130(3):452–456. doi:10.1016/j.ygyno.2013.06.009
14. Giannone G, Tuninetti V, Ghisoni E, et al. Role of cyclin-dependent kinase inhibitors in endometrial cancer. *Int J Mol Sci*. 2019;20(9):2353. doi:10.3390/ijms20092353
15. Murali R, Soslow RA, Weigelt B. Classification of endometrial carcinoma: more than two types. *Lancet Oncol*. 2014;15(7):e268–e278. doi:10.1016/S1470-2045(13)70591-6
16. Peters EEM, León-Castillo A, Hogdall E, et al. Substantial lymphovascular space invasion is an adverse prognostic factor in high-risk endometrial cancer. *Int J Gynecol Pathol*. 2022;41(3):227. doi:10.1097/PGP.0000000000000805
17. Peters EEM, León-Castillo A, Smit VTHBM, et al. Defining substantial lymphovascular space invasion in endometrial cancer. *Int J Gynecol Pathol*. 2022;41(3):220. doi:10.1097/PGP.0000000000000806
18. Oaknin A, Bosse TJ, Creutzberg CL, et al. Endometrial cancer: ESMO Clinical Practice Guideline for diagnosis, treatment and follow-up. *Ann Oncol*. 2022;33(9):860–877. doi:10.1016/j.annonc.2022.05.009
19. Gilks CB, Oliva E, Soslow RA. Poor interobserver reproducibility in the diagnosis of high-grade endometrial carcinoma. *Am J Surg Pathol*. 2013;37(6):874–881. doi:10.1097/PAS.0b013e31827f576a
20. Kommoss S, McConechy MK, Kommoss F, et al. Final validation of the ProMisE molecular classifier for endometrial carcinoma in a large population-based case series. *Ann Oncol*. 2018;29(5):1180–1188. doi:10.1093/annonc/mdy058
21. Stelloo E, Jansen AML, Osse EM, et al. Practical guidance for mismatch repair-deficiency testing in endometrial cancer. *Ann Oncol*. 2017;28(1):96–102. doi:10.1093/annonc/mdw542
22. Creutzberg CL, Nout RA, Lybeert MLM, et al. Fifteen-year radiotherapy outcomes of the randomized PORTEC-1 trial for endometrial carcinoma. *Int J Radiat Oncol Biol Phys*. 2011;81(4):e631–638. doi:10.1016/j.ijrobp.2011.04.013
23. Wortman BG, Creutzberg CL, Putter H, et al. Ten-year results of the PORTEC-2 trial for high-intermediate risk endometrial carcinoma: improving patient selection for adjuvant therapy. *Br J Cancer*. 2018;119(9):1067–1074. doi:10.1038/s41416-018-0310-8
24. Loukovaara M, Pasanen A, Bützow R. Clinicopathologic vs. molecular integrated prognostication of endometrial carcinoma by European Guidelines. *Cancers*. 2022;14(3):651. doi:10.3390/cancers14030651
25. McAlpine J, Leon-Castillo A, Bosse T. The rise of a novel classification system for endometrial carcinoma; integration of molecular subclasses. *J Pathol*. 2018;244(5):538549. doi:10.1002/path.5034
26. Stasenko M, Tunnage I, Ashley CW, et al. Clinical outcomes of patients with POLE mutated endometrioid endometrial cancer. *Gynecol Oncol*. 2020;156(1):194–202. doi:10.1016/j.ygyno.2019.10.028
27. Oaknin A, Gilbert L, Tinker AV, et al. Safety and antitumor activity of dostarlimab in patients with advanced or recurrent DNA mismatch repair deficient/microsatellite instability-high (dMMR/MSI-H) or proficient/stable (MMRp/MSS) endometrial cancer: interim results from GARNET—a Phase I, single-arm study. *J Immunother Cancer*. 2022;10(1):e003777. doi:10.1136/jitc-2021-003777
28. Marabelle A, Le DT, Ascierto PA, et al. Efficacy of pembrolizumab in patients with noncolorectal high microsatellite instability/mismatch repair-deficient cancer: results from the Phase II KEYNOTE-158 Study. *J Clin Oncol off J Am Soc Clin Oncol*. 2020;38(1):1–10. doi:10.1200/JCO.19.02105
29. Talhouk A, McConechy MK, Leung S, et al. A clinically applicable molecular-based classification for endometrial cancers. *Br J Cancer*. 2015;113(2):299–310. doi:10.1038/bjc.2015.190
30. Singh N, Piskorz AM, Bosse T, et al. p53 immunohistochemistry is an accurate surrogate for TP53 mutational analysis in endometrial carcinoma biopsies. *J Pathol*. 2020;250(3):336345. doi:10.1002/path.5375
31. Miller DS, Filiaci VL, Mannel RS, et al. Carboplatin and paclitaxel for advanced endometrial cancer: final overall survival and adverse event analysis of a Phase III Trial (NRG Oncology/GOG0209). *J Clin Oncol*. 2020;38(33):3841–3850. doi:10.1200/JCO.20.01076
32. Llombart-Cussac A, Pérez-García JM, Bellet M, et al. Fulvestrant-Palbociclib vs Letrozole/Palbociclib as initial therapy for endocrine-sensitive, hormone receptor-positive, ERBB2negative advanced breast cancer. *JAMA Oncol*. 2021;7(12):1–9. doi:10.1001/jamaoncol.2021.4301
33. Pectasides D, Pectasides E, Economopoulos T. Systemic therapy in metastatic or recurrent endometrial cancer. *Cancer Treat Rev*. 2007;33(2):177–190. doi:10.1016/j.ctrv.2006.10.007
34. Ethier JL, Desautels DN, Amir E, MacKay H. Is hormonal therapy effective in advanced endometrial cancer? A systematic review and meta-analysis. *Gynecol Oncol*. 2017;147(1):158–166. doi:10.1016/j.ygyno.2017.07.002
35. Mileschkin L, Edmondson R, O'Connell RL, et al. Phase 2 study of anastrozole in recurrent estrogen (ER)/progesterone (PR) positive endometrial cancer: the PARAGON trial – ANZGOG 0903. *Gynecol Oncol*. 2019;154(1):29–37. doi:10.1016/j.ygyno.2019.05.007
36. Wang Y, Tillmanns T, VanderWalde N, et al. Comparison of chemotherapy vs chemotherapy plus total hysterectomy for women with uterine cancer with distant organ metastasis. *JAMA Netw Open*. 2021;4(7):e2118603. doi:10.1001/jamanetworkopen.2021.18603
37. Landrum LM, Moore KN, Myers TKN, et al. Stage IVB endometrial cancer: does applying an ovarian cancer treatment paradigm result in similar outcomes? A case-control analysis. *Gynecol Oncol*. 2009;112(2):337–341. doi:10.1016/j.ygyno.2008.10.009
38. Albright BB, Monuszko KA, Kaplan SJ, et al. Primary cytoreductive surgery for advanced stage endometrial cancer: a systematic review and meta-analysis. *Am J Obstet Gynecol*. 2021;225(3):237.e1–237.e24. doi:10.1016/j.ajog.2021.04.254

39. Parmar MKB, Ledermann JA, Colombo N, et al. Paclitaxel plus platinum-based chemotherapy versus conventional platinum-based chemotherapy in women with relapsed ovarian cancer: the ICON4/AGO-OVAR-2.2 trial. *Lancet Lond Engl*. 2003;361(9375):2099–2106. doi:10.1016/s0140-6736(03)13718-x
40. Nagao S, Nishio S, Michimae H, et al. Applicability of the concept of “platinum sensitivity” to recurrent endometrial cancer: the SGSG-012/GOTIC-004/Intergroup study. *Gynecol Oncol*. 2013;131(3):567–573. doi:10.1016/j.ygyno.2013.09.021
41. Dellinger TH, Monk BJ. Systemic therapy for recurrent endometrial cancer: a review of North American trials. *Expert Rev Anticancer Ther*. 2009;9(7):905–916. doi:10.1586/era.09.54
42. O'Malley DM, Bariani GM, Cassier PA, et al. Pembrolizumab in patients with microsatellite instability-high advanced endometrial cancer: results from the KEYNOTE-158 Study. *J Clin Oncol off J Am Soc Clin Oncol*. 2022;40(7):752–761. doi:10.1200/JCO.21.01874
43. Kato Y, Tabata K, Kimura T, et al. Lenvatinib plus anti-PD-1 antibody combination treatment activates CD8+ T cells through reduction of tumor-associated macrophage and activation of the interferon pathway. *PLoS One*. 2019;14(2):e0212513. doi:10.1371/journal.pone.0212513
44. Makker V, Rasco D, Vogelzang NJ, et al. Lenvatinib plus pembrolizumab in patients with advanced endometrial cancer: an interim analysis of a multicentre, open-label, single-arm, phase 2 trial. *Lancet Oncol*. 2019;20(5):711–718. doi:10.1016/S1470-2045(19)30020-8
45. Makker V, Colombo N, Casado Herráez A, et al. Lenvatinib plus pembrolizumab for advanced endometrial cancer. *N Engl J Med*. 2022;386(5):437–448. doi:10.1056/NEJMoa2108330
46. Marth C, Tarnawski R, Tyulyandina A, et al. Phase 3, randomized, open-label study of pembrolizumab plus lenvatinib versus chemotherapy for first-line treatment of advanced or recurrent endometrial cancer: ENGOT-en9/LEAP-001. *Int J Gynecol Cancer*. 2022;32(1):93–100. doi:10.1136/ijgc-2021-003017
47. Lu L, Li Y, Luo R, Xu J, Feng J, Wang M. Prognostic and clinicopathological role of PD-L1 in endometrial cancer: a meta-analysis. *Front Oncol*. 2020;1:334.
48. Ott PA, Bang YJ, Berton-Rigaud D, et al. Safety and antitumor activity of pembrolizumab in advanced programmed death ligand 1–positive endometrial cancer: results from the KEYNOTE-028 Study. *J Clin Oncol*. 2017;35(22):2535–2541. doi:10.1200/JCO.2017.72.5952
49. Makker V, Taylor MH, Aghajanian C, et al. Lenvatinib Plus pembrolizumab in patients with advanced endometrial cancer. *J Clin Oncol off J Am Soc Clin Oncol*. 2020;38(26):29812992. doi:10.1200/JCO.19.02627
50. Marabelle A, Fakih M, Lopez J, et al. Association of tumour mutational burden with outcomes in patients with advanced solid tumours treated with pembrolizumab: prospective biomarker analysis of the multicohort, open-label, phase 2 KEYNOTE-158 study. *Lancet Oncol*. 2020;21(10):1353–1365. doi:10.1016/S1470-2045(20)30445-9
51. Chalmers ZR, Connelly CF, Fabrizio D, et al. Analysis of 100,000 human cancer genomes reveals the landscape of tumor mutational burden. *Genome Med*. 2017;9(1):34. doi:10.1186/s13073-017-0424-2
52. Goodman AM, Sokol ES, Frampton GM, Lippman SM, Kurzrock R. Microsatellite-stable tumors with high mutational burden benefit from immunotherapy. *Cancer Immunol Res*. 2019;7(10):1570–1573. doi:10.1158/2326-6066.CIR-19-0149
53. Palomero J, Panisello C, Lozano-Rabella M, et al. Biomarkers of tumor-reactive CD4+ and CD8+ TILs associate with improved prognosis in endometrial cancer. *J Immunother Cancer*. 2022;10(12):e005443. doi:10.1136/jitc-2022-005443
54. Jiang T, Chen X, Su C, Ren S, Zhou C. Pan-cancer analysis of ARID1A Alterations as Biomarkers for Immunotherapy Outcomes. *J Cancer*. 2020;11(4):776–780. doi:10.7150/jca.41296
55. De Leo A, Ravegnini G, Musiani F, et al. Relevance of ARID1A mutations in endometrial carcinomas. *Diagnostics*. 2022;12(3):592. doi:10.3390/diagnostics12030592
56. Roque DM, Bellone S, Siegel ER, et al. A phase II evaluation of pembrolizumab in recurrent microsatellite instability-high (MSI-H) endometrial cancer patients with Lynch-like versus MLH-1 methylated characteristics (NCT02899793). *J Clin Oncol*. 2021;39(15_suppl):5523. doi:10.1200/JCO.2021.39.15_suppl.5523
57. de Biasi AR, Villena-Vargas J, Adusumilli PS. Cisplatin-induced antitumor immunomodulation: a review of preclinical and clinical evidence. *Clin Cancer Res*. 2014;20(21):5384–5391. doi:10.1158/1078-0432.CCR-14-1298
58. Colombo N, Dubot C, Lorusso D, et al. Pembrolizumab for persistent, recurrent, or metastatic cervical cancer. *N Engl J Med*. 2021;385(20):1856–1867. doi:10.1056/NEJMoa2112435
59. Paz-Ares L, Luft A, Vicente D, et al. Pembrolizumab plus chemotherapy for squamous non–small-cell lung cancer. *N Engl J Med*. 2018;379(21):2040–2051. doi:10.1056/NEJMoa1810865
60. Shrimali RK, Yu Z, Theoret MR, Chinnasamy D, Restifo NP, Rosenberg SA. Antiangiogenic agents can increase lymphocyte infiltration into tumor and enhance the effectiveness of adoptive immunotherapy of cancer. *Cancer Res*. 2010;70(15):6171–6180. doi:10.1158/0008-5472.CAN-10-0153
61. Koshkin VS, Sonpavde GP, Hwang C, et al. Futibatinib plus pembrolizumab in patients (pts) with advanced or metastatic urothelial carcinoma (mUC): preliminary safety results from a phase 2 study. *J Clin Oncol*. 2022;40(6_suppl):501. doi:10.1200/JCO.2022.40.6_suppl.501

OncoTargets and Therapy

Dovepress

Publish your work in this journal

OncoTargets and Therapy is an international, peer-reviewed, open access journal focusing on the pathological basis of all cancers, potential targets for therapy and treatment protocols employed to improve the management of cancer patients. The journal also focuses on the impact of management programs and new therapeutic agents and protocols on patient perspectives such as quality of life, adherence and satisfaction. The manuscript management system is completely online and includes a very quick and fair peer-review system, which is all easy to use. Visit <http://www.dovepress.com/testimonials.php> to read real quotes from published authors.

Submit your manuscript here: <https://www.dovepress.com/oncotargets-and-therapy-journal>