

Assessing the Rejuvenation Effectiveness of a Hyaluronic Acid and Amino Acid Mixture in the Periorbital Region

Ayşe Gul Kabakci^{1,*}, Dursun Murat Bozkır^{2,*}, Çağlar Cengizler^{3,*}, Dilek Sire Eren^{4,*}, Memduha Gülhal Bozkır^{1,*}

¹Department of Anatomy, Faculty of Medicine, Cukurova University, Adana, Turkey; ²Adana Sevgi Eye Center, Adana, Turkey; ³Biomedical Device Technology Program, Vocational School of Health Services, Izmir Democracy University, Izmir, Turkey; ⁴Dr Dilek Eren Medical Aesthetic Clinic, Adana, Turkey

*These authors contributed equally to this work

Correspondence: Ayşe Gul Kabakci, Cukurova University, Faculty of Medicine, Department of Anatomy, Sarıçam, Adana, 01250, Turkey, Tel +90 322 338 60 60-3489, Fax +90 322 338 65 72, Email akabakci@cu.edu.tr

Purpose: We performed an assessment of the rejuvenation effect of an amino acid and hyaluronic acid mixture in the periorbital area.

Methods: A total of 23 of the 35 participants completed all application sessions and measurements. These 23 women were aged 30–55 years. A hyaluronic acid and amino acid mixture was injected into the participants' periorbital area. Three sessions of application with 15-day intervals were undertaken. Subjects' age, height, weight, smoking status, and sport participation were recorded. A photonic dark circle scale and Fitzpatrick's periorbital wrinkling classification were used for evaluation of dark circles and wrinkles in the periorbital area. Anatomical measurements (height of upper and lower eyelids) were done using ImageJ and a skin-analysis system (Observ 520).

Results: The 23 women had a mean age of 42.46±9.33 years, mean height 164.46±4.96 cm, and mean weight 63.94±8.26 kg. Before the sessions, the mean heights of the upper eyelids were 1.24±0.13 cm (right) and 1.21±0.13 cm (left), while those of the lower eyelids were 0.98±0.14 cm (right) and 0.97±0.17 cm (left). One month after the third session, mean upper-eyelid heights were 1.30±0.09 cm (right) and 1.28±0.11 cm (left) and lower-eyelid ones 1.02±0.11 cm (right) and 1.02±0.13 cm (left). Dark-circle and wrinkle-scale scores showed significantly positive results between before the sessions and 1 month after the third session.

Conclusion: A hyaluronic acid and amino acid mixture can be used to rejuvenation of the periorbital area in women aged 30–55 years.

Keywords: dark circle, periorbital anatomy, periorbital area, rejuvenation, wrinkle

Introduction

Important changes in the upper and lower eyelids are divided into static and dynamic components. The static component is due to changes in the bone and fat pad, while the dynamic component occurs from changes in muscle tone.^{1–3} The skin around the eyes shows special features. These features include a flattened dermal–epidermal margin, thin dermis, low density of sebaceous glands, and overactivity of the orbital portion of the orbicularis oculi muscle. For these reasons, periorbital skin is prone to low elasticity, wrinkling, and dark circles.^{1–4 3}

The periorbital region of the face is an important anatomical area for any surgical and nonsurgical rejuvenation procedures,¹ because this is one of the areas where signs of aging are seen the earliest.² Traditional surgical approaches to rejuvenation of the periorbital area are skin and muscle excision blepharoplasty, fat excision, and eyelid shortening and tightening. However, effective and less invasive treatment methods are alternatives to traditional surgical operations. The most popular nonsurgical procedures are neurotoxins, injectable fillers, and a skin-rejuvenation procedure (chemical peels and laser).² In addition, nonsurgical treatment complications are fewer and healing faster than with surgery.^{3–5}

In this study, we aimed to evaluate the rejuvenation efficacy of the nonsurgical method with a hyaluronic acid and amino acid (HA-AA) mixture in the periorbital area. Dark circles, wrinkles, and anatomical parameters (upper-eyelid and lower-eyelid height) were evaluated and the effectiveness of external aging factors (smoking and sport participation) on the healing of the periorbital area was examined, because the most important causes of periorbital aging are exposure to sunlight, smoking, lifestyle-associated factors, and other daily living activities, such as regular exercises.⁶

Methods

Participants and Study Design

Age, height, weight, smoking status, and sport participation of the volunteers were recorded. A photonic dark-circle scale and Fitzpatrick's periorbital wrinkling classification were scored by doctors. Height of upper and lower eyelids were evaluated. A single Adana center treated 23 female subjects aged 30–55 years at three microinjection sessions with 15-day intervals between each product administration in the periorbital area. Subjects were evaluated in basal conditions and after three sessions. Assessment of aesthetic results was made with photographic documentation. During the study, the relevant guidelines, regulations and experimental procedures were carried out in accordance with the Declaration of Helsinki. Approval by Noninterventional Ethics Committee of Cukurova University (122/25) was obtained. Each participant signed an informed consent form for data collection and use of photos. We grouped the anatomical and aesthetic evaluations of periorbital application (PA) in our study as follows

PA1: Before starting the first session of periorbital application.

PA2: Before starting the second session of periorbital application.

PA3: Before starting the third session of periorbital application.

PA4: One month after the third session of periorbital application.

Inclusion Criteria

Age 30–55 years

Photographic scale: mild/moderate cutaneous photoaging

Skin phototype: type II and III (Fitzpatrick's skin scale)

Exclusion Criteria

Pregnancy

Lactation

Menopausal

Body-mass index $>34.9 \text{ kg/m}^2$

Past aesthetic correction treatments and surgical operations

Problems with facial nerves

Not completing the sessions

Allergic reaction to product used in this study

Study Product

Sunekos 200 was used in the sessions. This is a medicinal product (class III) comprising lyophilized 100 mg sterile and nonpyrogenic glycine, L-proline, L-leucine, L-lysine HCl, L-valine, and L-alanine. It is produced by Professional Dietetics, Italy and used for mild–moderate correction of photoaging/aging facial and body aging signs (30 mg in 3 mL distilled water).⁷ The product was applied by the same doctor throughout the study at the same dosage.

Photography

All profile photographs were acquired using a skin-analysis system (Observ 520) with eyes closed in a standing position on a Frankfort plane (Figure 1A and B).⁸ The photos taken during each session were stored in the Observ 520 system. Then, anatomical evaluations from these photographs were performed using ImageJ.

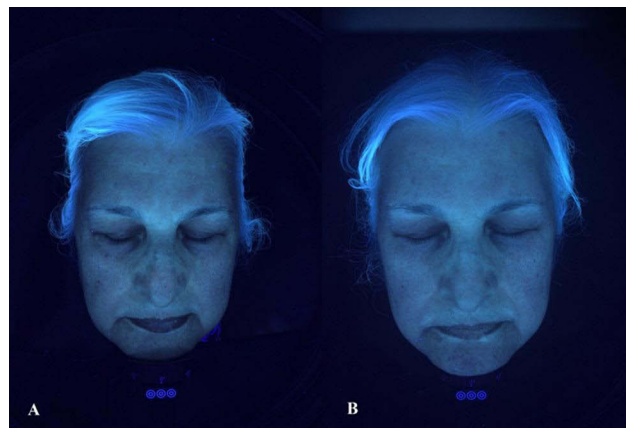


Figure 1 Positive change in dark-circle and wrinkle status at PA1 (A) and PA4 (B) in wood light mode.

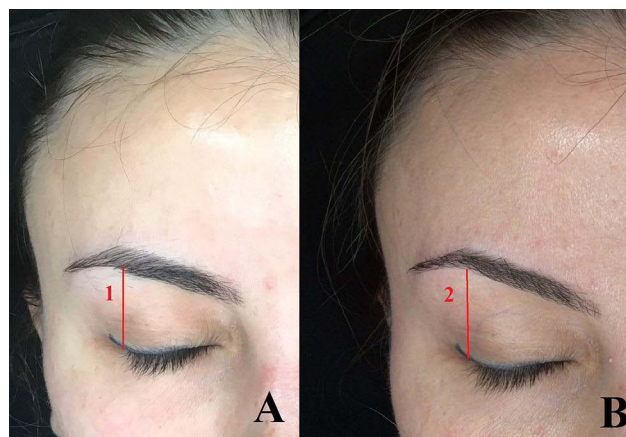

Figure 2 Change in height of upper eyelid at PA1 (A1) and PA4 (B2).

Assessment

Acquired images in the Observ 520 system were then transferred to a computer. In all the photos, a printed scale divided into millimeters with known dimensions was present. Measurements were made using ImageJ 1.52a with 1/100 mm sensitivity. Every measurement was repeated three times by the same investigators and means taken. In ImageJ, the first two landmarks were marked on the photograph and the program automatically measured the distance between the two landmarks. The obtained measurements were recorded in SPSS and statistical analyses performed. Anthropometric measurements and landmark points used were as follows.

The height of the upper and lower eyelids was measured from the palpebrale superioris to the orbitale superius (Figure 2A and B).^{9,9} A photonic scale of 0–8 points was used to evaluate the effect of the HA-AA mixture on dark circles. As the score increases, the intensity of the dark circles also increases.¹⁰ Fitzpatrick's classification was used for assessment of periorbital wrinkling: degree of elastosis from 1 point to 9 points. While 1 point indicates that the wrinkling condition is fine, 9 points indicates that the wrinkling condition is the most intense.¹¹ To measure patient satisfaction, before the first session and after each of the three sessions of periorbital application, we asked the volunteers how they felt when they looked in the mirror, from 1 point to 10 points (10, very satisfied).

Statistical Analysis

SPSS 22 was used for statistical analysis, and significance was considered as $p < 0.05$. Also, the normal distribution of the data distribution were identified by skewness and kurtosis statistics (between 1.5 and -1.5). Dark-circle scores, wrinkling

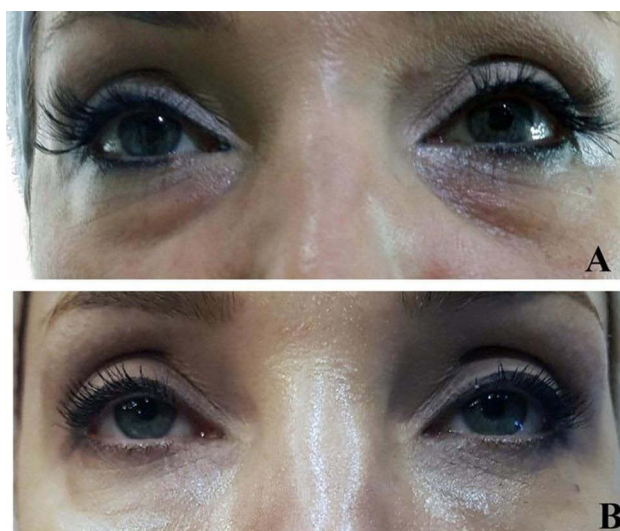

Figure 3 Positive change in dark-circle and wrinkle status at PA1 (A) and PA4 (B).

scores, height of upper eyelid, height of lower eyelid, and patient-satisfaction scores for the PA1, PA2, PA3 and PA4 sessions were analyzed using ANOVA. Data distribution of wrinkling and dark circles according to smoking and sport participation was analyzed, with categorical variables given in the table and figures.

Results

Mean age, height, and weight of the 23 women in our study were 42.46 ± 9.33 years, 164.46 ± 4.96 cm, and 63.94 ± 8.26 kg, respectively. There was a significant difference between PA1 and PA4 dark-circle scores (Figures 3B and B), wrinkle scores, patient satisfaction, upper-eyelid height (Figure 2A and B), and lower-eyelid height (Table 1). Dark-circle and wrinkle scores showed significantly positive results between PA1 and PA2, PA2 and PA3, and PA3 and PA4. However, the most significant results were found between PA1 and PA4. There was no significant difference between PA1 and PA2 ($p=0.133$) in upper-eyelid height (R), but a significant difference was found between PA2 and PA3 ($p=0.019$) and

Table 1 Dark-circle scores, wrinkle scores, patient-satisfaction scores, and height of upper and lower eyelids from PA1 to PA4

	PA1	PA2	PA3	PA4	p
	Mean \pm SD (range)				
Dark-circle score (R)	6.06 ± 1.43 (3–8)	5.14 ± 1.00 (3–7)	4.34 ± 1.00 (2–6)	2.97 ± 0.75 (2–4)	<0.001
Dark-circle score (L)	6.02 ± 1.38 (2–8)	5.77 ± 1.02 (3–8)	4.56 ± 0.98 (2–7)	2.92 ± 0.77 (1–4)	<0.001
Wrinkle score (R)	6.57 ± 1.50 (4–9)	5.66 ± 1.66 (3–8)	5.29 ± 1.53 (3–8)	4.40 ± 1.88 (1–8)	<0.001
Wrinkle score (L)	6.63 ± 1.44 (4–9)	5.77 ± 1.62 (4–8)	5.33 ± 1.49 (3–8)	4.37 ± 1.92 (1–7)	<0.001
Height of upper eyelid (R)	1.24 ± 0.13 (1–1.5)	1.19 ± 0.18 (0.9–1.5)	1.28 ± 0.13 (1.00–1.5)	1.30 ± 0.09 (1–1.5)	0.023
Height of upper eyelid (L)	1.21 ± 0.13 (1–1.5)	1.19 ± 0.17 (0.9–1.5)	1.25 ± 0.14 (1–1.5)	1.28 ± 0.11 (1.1–1.5)	0.013
Height of lower eyelid (R)	0.98 ± 0.14 (0.7–1.2)	1.00 ± 0.12 (0.8–1.2)	1.01 ± 0.12 (0.8–1.2)	1.02 ± 0.11 (0.8–1.2)	0.003
Height of lower eyelid (L)	0.97 ± 0.17 (0.7–1.3)	0.99 ± 0.15 (0.7–1.3)	1.01 ± 0.14 (0.7–1.3)	1.02 ± 0.13 (0.7–1.3)	0.001
Patient-satisfaction score	5.37 ± 1.00 (4–8)	6.40 ± 0.78 (5–8)	7.03 ± 0.75 (5–8)	7.60 ± 0.77 (6–9)	<0.001

Abbreviations: p, PA1 vs PA4; PA, periorbital application.

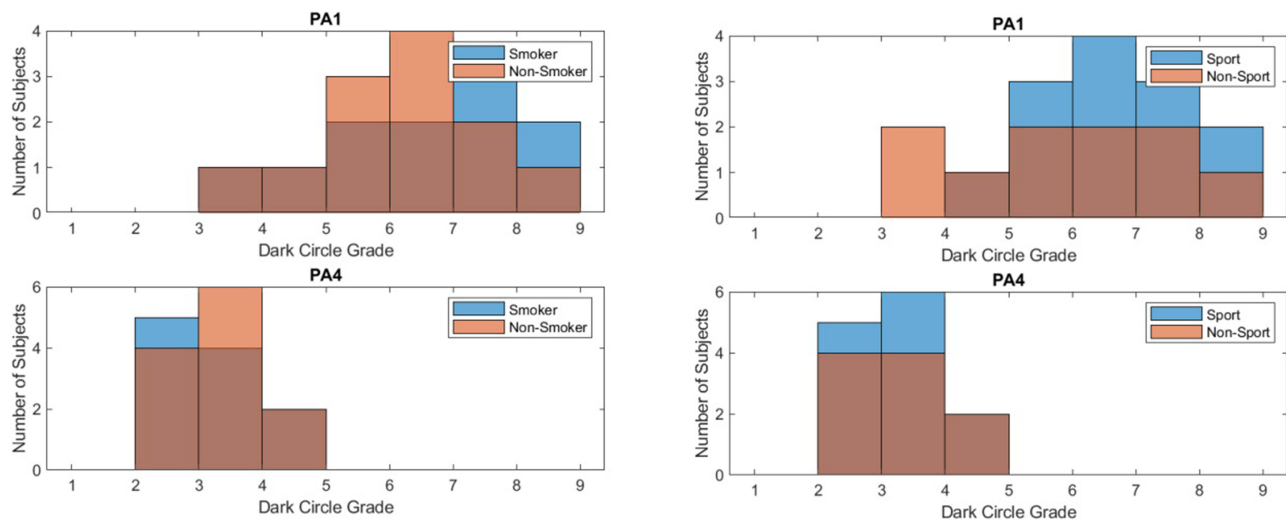


Figure 4 Distribution of dark-circle parameter according to smoking and sport participation.

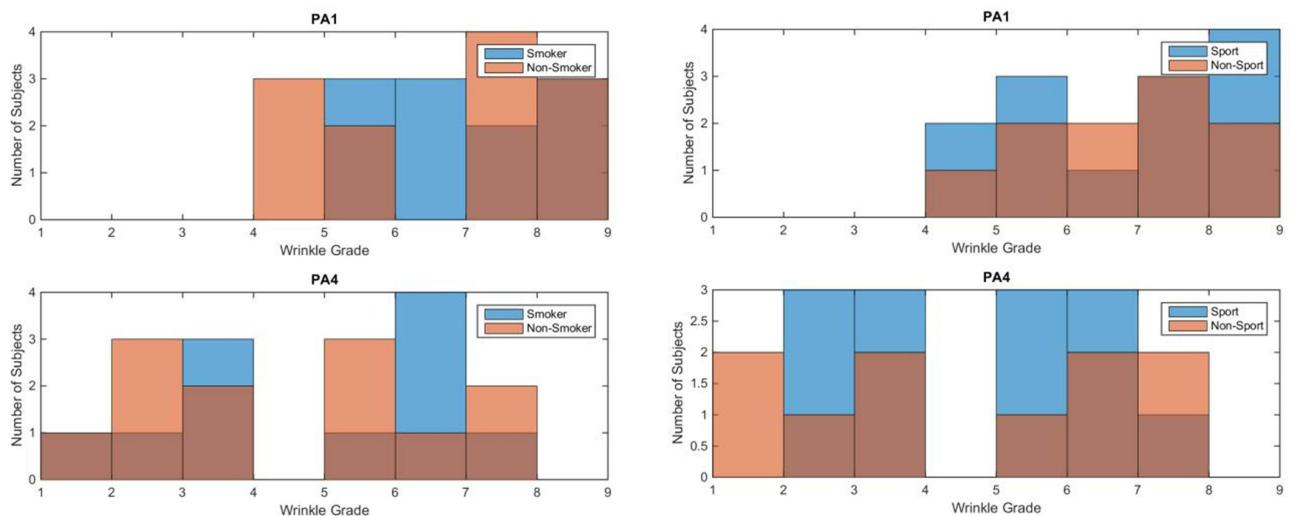


Figure 5 Distribution of wrinkle parameter according to smoking and sport participation.

between PA3 and PA4 ($p=0.027$). No significant difference was found between PA1 and PA2 ($p=0.422$), PA2 and PA3 ($p=0.089$), or PA3 and PA4 ($p=0.06$) for upper-eyelid height (L). For lower-eyelid height, there was a significant difference only between PA1 and PA2 on both the right ($p=0.030$) and left ($p=0.018$) sides. While there were significant differences between PA2 and PA3 for lower-eyelid height (R) ($p=0.83$) and lower-eyelid height (L) ($p=0.096$), there was no significant difference between PA3 and PA4 for lower-eyelid height (R) ($p=0.103$) or lower-eyelid height (L) ($p=0.096$).

While it was observed that smokers had higher dark-circle scores than nonsmokers at PA1, both groups showed decreased dark-circle scores at PA4 (Figure 4). Similarly, while dark-circle scores were high at PA1 in both sport participants and those who did not partake in any sport, positive improvement was observed at PA4 in both groups (Figure 4). Wrinkle scores were high in both smokers and nonsmokers in PA1, and decreased wrinkle scores were observed in both smokers and nonsmokers at PA4. In the same way, there was a decrease in wrinkle scores between PA1 and PA4 (Figure 5).

Discussion

Nonsurgical treatment options for skin rejuvenation are increasingly more requested than surgery. In particular, using HA gel fillers for rejuvenation of the face has been increasing in popularity over the years. This nonsurgical method (HA), temporary technique is commonly used in the periorbital region to restore volume. Lee et al emphasized in their study on nonsurgical rejuvenation that HA fillers provide an efficient option in the periorbital area.² Sharad shared the effectiveness of dermal fillers in the restoration of tear troughs for healing of dark circles.¹² Fitzgerald et al stated in their study that HA filling is a curative application in periorbital aging.¹³ Similarly, Muhn et al stated that HA filling is an effective method for aging around the eyes in Canadians.¹⁴ Cui et al used a nonsurgical facial aesthetic treatment with HA filler, which they named “Future Codes.”¹⁵ There are many studies in the literature evaluating the most common use of HA dermal fillers in periorbital rejuvenation. Bravo et al, Braz and Eduardo, and Wong used HA dermal fillers in periorbital rejuvenation in their study.^{16–18} There are few studies about HA-AA mixture application. Therefore, we evaluated the effectiveness of both HA and AA in the periorbital area. While evaluations in studies in the literature were done using patient-satisfaction scores, observations or scales, our study used anatomical measurements, scales, participant satisfaction, and demographic data for evaluation.

Upper-eyelid height increased between sessions PA1–PA2, PA2–PA3, PA3–PA4, and PA1–PA4 on the right side. However, there was no significant change between sessions PA1–PA2, PA2–PA3, or PA3–PA4 on the left side, but a significant increase was found between PA1 and PA4. Participants stated that their eyebrows had been raised between PA1 and PA4, and they were satisfied with this. For lower-eyelid height, there was no significant change between sessions, but a significant increase was noted between PA1 and PA4 in upper-eyelid height. The upper eyelid has a larger volume than the lower eyelid and is more mobile thanks to the musculus levator palpebralis. In addition, the lateral cantus is approximately 2 mm higher than the medial cantus. However, these characteristics vary according to ethnicity, for example, this distance increases in some Asian groups.^{19,20} In addition to other studies done in Indian–Malaysian and Japanese populations, in both sexes a significant difference was found in upper- and lower-eyelid height, but in our study, these parameters were higher than in those populations.^{9,21} On the other hand, these parameters in the present study were found to be similar to a US population.²² These results show that the parameters vary between ethnicities and countries. Furthermore, human skin aging is caused by intrinsic aging factors (ethnicity, genetic) and external aging factors (smoking, sport participation, exposure to chemicals and ultraviolet radiation). It is essential to know the etiology to determine whether HA is the best approach.²³ Therefore, we also examined sport participation and smoking in the women. However, no significant difference was found between wrinkles and dark circles or smoking and sport participation. We think that this result may also be because of the low number of participants in our study. We recommend that studies be conducted with the same evaluations and more participants. When we examined distribution, it was seen that smokers had higher dark-circle scores, but smokers and nonsmokers were similar in wrinkle scores. According to this result, we can say that smoking is a risk factor for dark circles. In addition, scores at PA1 had decreased at PA4 for both sport and smoking.

A positive and significant difference was found in the wrinkling and dark-circle scores, especially after the last session of HA-AA mixture application and 1 month after the last session. This result brings to mind the question: How did three sessions of microinjection create such an improvement? Aging is characterized especially in the extracellular matrix cells of the dermis. HA-AA mixture application affects the extracellular matrix of the dermis, unlike the applications that do not affect the matrix used today. This application provides activation by regularly stimulating the collagen and elastin in the extracellular matrix cells of the dermis. A recent *in vitro* study varying the quality and quantity of amino acids in the mixtures showed that it is possible to increase the expression, at gene and protein level, of elastin though maintaining stimulation of collagen. In an *in vitro* study by Servi et al conducted on human dermal fibroblasts, the efficacy of HA-AA mixture on the biosynthesis of extracellular matrix proteins, in particular of elastin, was demonstrated. Finally, they found that by varying the quality and quantity of amino acids in the mixtures, it was possible to increase the expression, at gene and protein level, of elastin though maintaining a stimulation of collagen.²⁴ Our results support the mechanism of wrinkle and dark-circle healing because of HA-AA mixture application.

Conclusion

We concluded that the application of HA-AA is effective in healing dark circles and wrinkles in women aged 30–55 years. We also revealed that the eyebrow height increased from the feedback of the participants and the increase in upper-eyelid height. Therefore, HA-AA application can be used in periorbital region rejuvenation. The main difference was seen 1 month after the end of the three application sessions. For this reason, we recommend HA-AA application be administered for at least three sessions. We also recommend similar studies with more cases.

Ethics

This study was conducted in accordance with the principles of the Declaration of Helsinki. All patients provided informed written consent prior to study commencement. Written informed consent was provided by the patients to have their case details and any accompanying images published. The protocol was approved by the Noninterventional Ethics Committee of Cukurova University (122/25).

Acknowledgments

We would like to thank Professional Dietetics (1/A Via Ciro Menotti, Milano 20129, Italy) for all important contributions. Moreover, thanks to the medical aesthetic physicians Dr E Gizem Geylani and Dr Can Mustafa Eren.

Funding

This research was funded by Professional Dietetics S.p.A. (Via Ciro Menotti 1/A, 20129, Milan, Italy).

Disclosure

The authors report no conflicts of interest in this work.

References

1. Love LP, Farrior EH. Periocular anatomy and aging. *Facial Plast Surg Clin North Am.* 2010;18:411–417. doi:10.1016/j.fsc.2010.05.001
2. Lee S, Yen MT. Nonsurgical rejuvenation of the eyelids with hyaluronic acid gel injections. *Semin Plast Surg.* 2017;31(1):17–21. doi:10.1055/s-0037-1598189
3. Glaser DA, Patel U. Enhancing the eyes: use of minimally invasive techniques for periorbital rejuvenation. *J Drugs Dermatol.* 2010;9:S118–S283.
4. Lambros V. Observation on periorbital and midface aging. *Plast Reconstr Surg.* 2007;120:1367–76. doi:10.1097/01.prs.0000279348.09156.c3
5. Guida S, Mandel VD, Farnetani F, et al. Permanent implants for lip augmentation: results from a retrospective study and presentation of tips and tricks. *J Plast Reconstr Aesthet Surg.* 2017;70:699–704. doi:10.1016/j.bjps.2017.02.005
6. Puizina-Ivić N, Mirić L, Carija A, et al. Modern approach to topical treatment of aging skin. *Coll Antropol.* 2010;34:1145–1153.
7. Sparavigna A, Orlandini A. Efficacy and tolerance of an injectable medical device containing hyaluronic acid and amino acids: a monocentric six-month open-label evaluation. *J Clin Trials.* 2017;7(4):1–6.
8. Hegde V. Significance of the Frankfort mandibular plane angle in prosthetic management of partially or completely edentulous patients with Class II malocclusions. *J Indian Prosthodont Soc.* 2005;5(4):175–179. doi:10.4103/0972-4052.21631
9. Kumar BS. Sex determination by morphometry of eyes. *J Krishna Inst Med Sci Univ.* 2019;8(1):80–85.
10. O'Mahony MM, Sladen C, Crone M, et al. A validated photo-numeric scale for infraorbital dark circles and its application in evaluating the efficacy of a cosmetic treatment product in a split-face randomized clinical trial. *Int J Cosmet Sci.* 2021;43(1):48–56. doi:10.1111/ics.12668
11. Lemperle G, Holmes RE, Cohen SR, et al. A classification of facial wrinkles. *Plast Reconstr Surg.* 2001;108(6):1735–1750. doi:10.1097/00006534-200111000-00049
12. Sharad J. Dermal fillers for the treatment of tear trough deformity: a review of anatomy, treatment techniques, and their outcomes. *J Cutan Aesthet Surg.* 2012;5(4):229–238. doi:10.4103/0974-2077.104910
13. Fitzgerald R, Carqueville J, Yang PT. An approach to structural facial rejuvenation with fillers in women. *Int J Womens Dermatol.* 2018;5(1):52–67. doi:10.1016/j.ijwd.2018.08.011
14. Muhn C, Rosen N, Solish N, et al. The evolving role of hyaluronic acid fillers for facial volume restoration and contouring: a Canadian overview. *Clin Cosmet Investig Dermatol.* 2012;5:147–158. doi:10.2147/CCID.S30794
15. Cui H, Zhao H, Xu H, et al. An innovative approach for facial rejuvenation and contouring injections in Asian patients. *Aesthet Surg J Open Forum.* 2021;3(2):ojaa053. doi:10.1093/asjof/ojaa053
16. Bravo BS, Rocha CR, Bastos JT, et al. Comprehensive treatment of periorbital region with hyaluronic acid. *J Clin Aesthet Dermatol.* 2015;8(6):30–35.
17. Braz A, Eduardo CCP. The facial shapes in planning the treatment with injectable fillers. *Indian J Plast Surg.* 2020;53(2):230–243. doi:10.1055/s-0040-1715554
18. Wong V. The science of absorbable poly(l-lactide-co-ε-caprolactone) threads for soft tissue repositioning of the face: an evidence-based evaluation of their physical properties and clinical application. *Clin Cosmet Investig Dermatol.* 2021;14:45–54. doi:10.2147/CCID.S274160

19. Dobbs NW, Budak MJ, White RD, et al. MR-Eye: high-resolution microscopy coil MRI for the assessment of the orbit and periorbital structures, part 1: technique and anatomy. *AJNR Am J Neuroradiol*. 2020;41(6):947–950. doi:10.3174/ajnr.A6495
20. Jehoon O, Kwon HJ, Choi YJ, Cho TH, Yang HM. Three-dimensional structure of the orbicularis retaining ligament: an anatomical study using micro-computed tomography. *Sci Rep*. 2018;8(1):17042. doi:10.1038/s41598-018-35425-0
21. Akita S, Maki S, Shiko Y, et al. Eyelid crease height affects the evaluation of age-related changes in the eyelids. *Plast Reconstr Surg Glob Open*. 2021;9(11):e3909. doi:10.1097/GOX.0000000000003909
22. Cartwright MJ, Kurumety UR, Nelson CC, et al. Measurements of upper eyelid and eyebrow dimensions in healthy white individuals. *Am J Ophthalmol*. 1994;117(2):231–234. doi:10.1016/S0002-9394(14)73081-8
23. Banihashemi M, Zabolinejad N, Salehi M, et al. Platelet-rich plasma use for facial rejuvenation: a clinical trial and review of current literature. *Acta Biomed*. 2021;92(2):e2021187. doi:10.23750/abm.v92i2.9687
24. De Servi B, Orlandini A, Caviola E, et al. Amino acid and hyaluronic acid mixtures differentially regulate extra cellular matrix genes in cultured human fibroblasts. *J. Biol Regul Homeost Agents*. 2018;32(3):517–527.

Clinical, Cosmetic and Investigational Dermatology

Dovepress

Publish your work in this journal

Clinical, Cosmetic and Investigational Dermatology is an international, peer-reviewed, open access, online journal that focuses on the latest clinical and experimental research in all aspects of skin disease and cosmetic interventions. This journal is indexed on CAS. The manuscript management system is completely online and includes a very quick and fair peer-review system, which is all easy to use. Visit <http://www.dovepress.com/testimonials.php> to read real quotes from published authors.

Submit your manuscript here: <https://www.dovepress.com/clinical-cosmetic-and-investigational-dermatology-journal>