

# Analysis of Chronic Low Back Pain Caused by Lumbar Microinstability After Percutaneous Endoscopic Transforaminal Discectomy: A Retrospective Study

Yang Fu, Ying-Chao Yan, Xuan-Liang Ru, Hang-Bo Qu

Department of Orthopedics, Affiliated Zhejiang Hospital, Zhejiang University School of Medicine, Hangzhou, People's Republic of China

Correspondence: Hang-Bo Qu, Department of Orthopedics, Affiliated Zhejiang Hospital, Zhejiang University School of Medicine, Hangzhou, People's Republic of China, Tel +86-153-5571-0890, Email quhb1222@163.com

**Objective:** Chronic low back pain (CLBP) after percutaneous endoscopic transforaminal discectomy (PTED) surgery may be caused by preoperative lumbar microinstability (MI). However, there is a paucity of research on the relationship between lumbar microinstability and chronic low back pain. The purpose of this article is to assess the preoperative radiographic characteristics of patients and evaluate the effects of lumbar microinstability on patient-reported outcomes among single-level lumbar disc herniation (LDH) patients who underwent PTED.

**Methods:** This study retrospectively reviewed the radiographic characteristics of a consecutive series of 127 patients with low back pain and leg pain caused by single-level LDH underwent PTED from August 2018 to March 2021. They were divided into three groups according to the radiographic parameters: the stable group (Group S), the dysfunctional group (Group D), and the microinstability group (Group M). The visual analogue scale (VAS) scores for leg and low back pain and Oswestry Disability Index (ODI) were evaluated preoperatively and postoperatively. Logistic regression analysis was used to identify independent risk factors for CLBP.

**Results:** Compared with Group D and Group S, Group M had the highest ODI scores ( $P < 0.01$ ) and VAS scores (low back pain) ( $P < 0.01$ ) after 1 year, while there were no significant differences in the VAS scores for leg pain at different time points after surgery ( $P > 0.05$ ). In addition, the logistic regression analysis results regarding CLBP revealed that muscle fatty degeneration on MRI (95% CI, 1.20–8.51,  $P = 0.02$ ), and facet tropism (95% CI, 1.39–11.37,  $P = 0.01$ ) may be independent risk factors.

**Conclusion:** Patients with lumbar microinstability may have CLBP after PTED, so patients with lumbar microinstability may need to take internal fixation surgery to solve their symptoms.

**Keywords:** chronic low back pain, PTED, microinstability, risk factor

## Introduction

Lumbar disc herniation (LDH) is the most common cause of sciatica and accounts for the greatest social health burden in terms of disability and work absenteeism.<sup>1</sup> Patients may resort to surgical intervention because of severe low back pain and leg pain that affect their quality of life. Although there are some controversies in terms of surgical indications and methods, percutaneous endoscopic transforaminal discectomy (PTED) is an accepted surgical procedure worldwide for patients with a single-level lumbar disc herniation.<sup>2</sup> This method can be used to resect herniated intervertebral discs through a very small incision with the advantages of a low risk of soft tissue injury, fast rehabilitation, and preservation of the motion function of the operated segments.<sup>3,4</sup> After surgery, the symptoms of the nerve root can be relieved immediately in most patients, and as many as 95% of patients can achieve satisfactory patient-reported outcomes.<sup>5</sup>

However, some patients are prone to persisting chronic low back pain (CLBP) with visual analogue scale (VAS) scores higher than 3 for one year after PTED, which is even worse than that preoperatively, and affects their post-operative recovery and the early return to normal.<sup>6</sup> Theoretically, many factors are involved in chronic low back pain,

including inflammation, muscle degeneration, and facet joint fluid, but the major cause may be related to inherent lumbar instability preoperatively or iatrogenic lumbar instability postoperatively.<sup>7</sup> In a previous study, Iguchi et al<sup>8</sup> found that the critical factor for low back pain was lumbar instability, and the results revealed that patients with a higher degree of lumbar instability had significantly more days with pain and more hospital visits for their symptoms than other patients. Thus, lumbar instability is commonly the first consideration in determining the treatment strategy.

Although there are multiple modalities for diagnosing lumbar instability, the most common diagnostic technique is the use of lateral flexion and extension standing radiographs.<sup>9</sup> However, these have several limitations. Patients cannot perform adequate flexion and extension due to serious pain when standing, which causes analgic contraction and altered muscle tone, which indicates that it is a poor method to reveal lumbar instability.<sup>10</sup> Recent studies have proposed many theories regarding lumbar motions, including dynamic instability, lumbar dysfunction, and lumbar microinstability (MI).<sup>11</sup> Moreover, Landi et al<sup>12</sup> defined clinical condition-specific pathoanatomical and clinical characteristics in the vertebral segment of interest without the presence of spondylolisthesis in flexion–extension radiography as indicators of lumbar microinstability, and found a close relationship between lumbar microinstability and adjacent segment disease (ASD). This publication indicated that low back pain might correlate with lumbar microinstability, and this theoretical background can also apply to patients with CLBP after PTED. However, there is a paucity of research using lumbar microinstability to investigate the motion characteristics of the involved segment or surgical outcomes. Thus, the purpose of this study was to assess the radiographic characteristics of patients and evaluate the effects of lumbar microinstability on patient-reported outcomes for single-level LDH patients who underwent PTED.

## Methods

### Patients

After approval by the Ethics Committee of Zhejiang Hospital, we retrospectively reviewed the medical records of patients who underwent PTED from August 2018 to March 2021 at the hospital. All methods were performed in accordance with relevant guidelines and regulations and informed consent was obtained from all subjects. We followed the Declaration of Helsinki guidelines. Patients enrolled in this study had to meet the following inclusion criteria: (1) patients with PTED due to single-level LDH; (2) patients'VAS scores for leg pain and low back pain were lower than 4 at the one-year follow-up after operation. (3) patients with PTED were followed up on a regular basis for at least a year; Exclude any of the following: (1) obvious vertebral column Canal stenosis, such as intermittent claudication; (2) mobile movement, the width of the adjacent vertebral body at 3 mm, and/or >8% of the affected segment;<sup>13</sup> (3) patients with multi-level lumbar disc herniation; (4) patients with spinal fractures; (5) patients with spinal infections; (6) trauma patients; (7) a cancer patient; (8) patients with a history of lumbar spondylosis.

### Surgical Technique

All patients received the same surgical treatment. The PTED patient was placed in the prone position under local anesthesia. Through C-arm lateral fluoroscopy, the surgical segment and the puncture needle point were determined. Puncture at 12–14 cm of the incision gap and make a mark. With the needle near the midline of the pedicle, the needle is located on the disc and the posterior edge of the spine under lateral fluoroscopy. A guide wire was used instead of the needle to pass the dilator through the guide wire into the working cannula. Using forceps and a bipolar radiofrequency coagulation device, the herniated disc fragments were removed endoscopically. Pay attention to the space between the lumbar intervertebral disc and the ligamentum flavum, and ensure sufficient relaxation. After surgery, the surgeon determines the following criteria for decompression: the nerve tissue can move on its own, the dura mater and nerve roots beat autonomously (in synchrony with the heartbeat), restore the anatomical position of the nerve tissue, and improve the blood supply to the nerve tissue. The surgeon also needs to ensure that symptoms have subsided.

### Evaluation of Baseline Characteristics

Baseline characteristics included patient factors (age, sex, BMI and vertebral level of the operation), basic radiographic parameters on X-rays (Van Akkerveeken's lines, Hadley's "S" curve, Ullmann's line), and CT (osteoarthritic facet

degeneration grade and facet tropism) and MRI findings (Pfirrmann grading, modic changes, facet fluid measurement, and muscle fatty degeneration). The visual analogue scale (VAS) scores for leg and low back pain were used to evaluate patient-reported outcomes preoperatively, at 1 month, 3 months, 6 months and 1 year postoperatively. The Oswestry Disability Index (ODI) was used to evaluate patient-reported outcomes preoperatively, at 3 months, 6 months and 1 year postoperatively. CLBP was defined as VAS  $\geq 4$  at every point, because VAS  $\geq 4$  was defined as moderate pain.

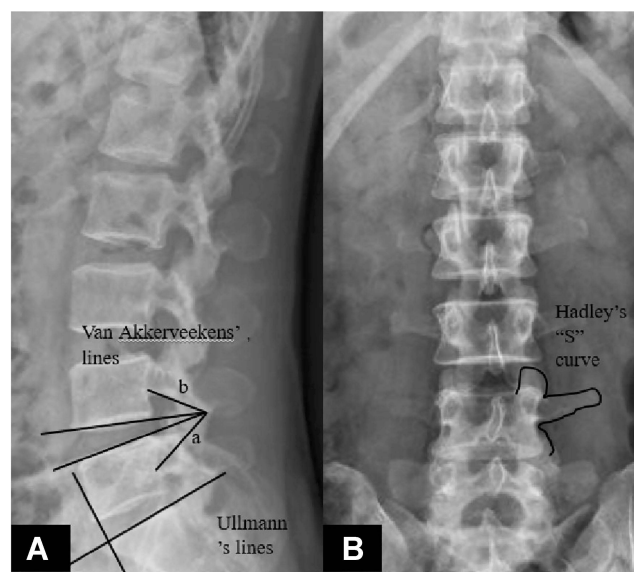
## Radiographic Evaluation

All radiographic parameters were performed twice and averaged to reduce the errors by a single spine surgeon, the pathoanatomic alterations in relation to spinal motor unit dysfunction were analysed, and a specific score was given to every kind of alteration. In X-rays, the Van Akkerveeken's lines<sup>12</sup> refer to the distance between the crossing of the two lines passing through the endplates and the posterior wall of the vertebral body. Hadley's "S" curve<sup>12</sup> is an S-shaped line passing through the inferior margin of the transverse process and the lateral margin of the articular mass. An interruption of the S-shaped line means facet subluxation. Ullmann's line<sup>12</sup> is a line passing through the endplate of S1, and the other line is perpendicular to the first line and passes through the sacral promontory. If L5 is beyond the line, the segment is unstable. In addition, the slip distance percentage was measured as the interval between two extended lines of the posterior aspects of the two vertebral bodies with herniation in dynamic X-rays, which were used to evaluate lumbar instability whether or not (Figure 1).

On CT, the osteoarthritic facet degeneration grade<sup>14</sup> evaluates the grade of osteoarthritic facet degeneration and includes 4 progressive grades. Facet tropism<sup>15</sup> was measured as the difference in the angle between the midline and the line passing through the articular rim.

On MRI, Pfirrmann grading<sup>16,17</sup> is a method for evaluating intervertebral disc degeneration, which includes 5 progressive degeneration grades that are related to the degree of progressive instability. Modic changes<sup>18–20</sup> evaluate the degeneration of the endplates, and include 3 progressive degeneration grades. Facet fluid<sup>21</sup> refers to a large ( $>1.5$  mm) facet effusion. Muscle fatty degeneration<sup>22</sup> evaluates whether the lumbar multifidus muscle has fatty infiltration.

A score of 0 is assigned if there is no alteration, or a score of 1 is assigned if the specific alteration is found (ie, the presence of facet fluid, muscle fatty degeneration, facet tropism and of the measurements on the X-ray). The score



**Figure 1** The Van Akkerveeken's lines were measured as the distance between the crossing of the two lines passing through the endplates and the posterior wall of the vertebral body. "a" is the distance between the crossing of the two lines passing through the endplates and the midpoint of the posterior edge of the lower vertebral body. "b" is the distance between the crossing of the two lines passing through the endplates and the midpoint of the posterior edge of the upper vertebral body (A). Ullmann's line is a line that passes through the endplate of S1, and the other line is perpendicular to the first line and passes through the sacral promontory (A). Hadley's "S" curve is an S-shaped line passing through the inferior margin of the transverse process and the lateral margin of the articular mass (B).

assigned ranges from 0 to 4 depending on the specific alterations, including modic changes, Pfirrmann grading, and osteoarthritic facet degeneration grade (Table 1).

The sum of the different scores defines a total score varying from 0 to 14 and indicates the degree of lumbar dysfunction, where a score of 0 indicates a stable lumbar spine and scarce clinical meaning and a score of 14 indicates severe microinstability.

## Study Groups

The enrolled patients were divided into three groups: a stable group (Group S), a dysfunctional group (Group D) and a microinstability group (Group M), based on the sum of the different scores obtained in individual examinations. Group S included patients with scores of 0–3, which was defined as a stable lumbar spine, which indicates that the clinical and radiological findings indicate dysfunction in its initial stage and that there is little clinical and biomechanical meaning of the findings. Group D included patients with scores of 4–8, which was defined as a dysfunctional lumbar spine, with accompanies moderate clinical and biomechanical meaning of the findings. Group M included patients with scores of 9–14, defined as microinstability of the lumbar spine, which indicates advanced-stage dysfunction with great clinical and biomechanical of the findings.

## Statistical Analysis

Two primary analyses were conducted. First, baseline characteristics were compared among Group S, Group D and Group M. Second, the radiographic characteristics were compared among the three groups. All data were analysed using SPSS version 24.0 (SPSS, Chicago, IL, USA). The data were fit to a normal distribution, so the paired t-test was used to analyse the intragroup differences. Analysis of variance (ANOVA) and the chi-square test were used to analyse the

**Table 1** Scores for Radiographic Data

Radiographs		Specific Alterations	Score
Static X-Rays	The Van Akkerveekens' measurements (>1.5mm) Hadley's "S" curve Ullman's line	+/-	1/0
		+/-	1/0
		+/-	1/0
CT	Osteoarthritic facet degeneration grade	Grade I	0
		Grade II	1
		Grade III	2
		Grade IV	3
	Facet tropism	+/-	1/0
MRI	Pfirrmann grading	Grade I	0
		Grade II	1
		Grade III	2
		Grade IV	3
		Grade V	0
	Modic changes	Grade 0	0
		Grade I	2
		Grade II	1
		Grade III	0
	Facet fluid(>1.5mm)	+/-	1/0
	Fatty degeneration	+/-	1/0

differences among these three groups. Moreover, logistic regression was performed to ascertain potential related and independent risk factors for CLBP. A P value <0.05 was considered statistically significant.

## Results

### Baseline Characteristics

A total of 127 patients who underwent surgical treatment with PTED were included in this study. The average age of these patients was 50.6 years (range 25–87 years). Of the 127 patients, 71 (55.9%) were male, 31 (24.4%) patients were assigned to Group S, 59 (46.5%) patients were assigned to Group D, and 37 (29.1%) patients were assigned to Group M. There was no difference in reporting among the groups in age, sex, or BMI. Their demographic information was recorded (Table 2). L4-5 was the most common surgical level ( $n = 76$ , 59.8%), followed by L5-S1 ( $n = 46$ , 36.2%) and L3-4 ( $n = 5$ , 3.9%). In addition, the follow-up period was not significantly different among Group S ( $22.4 \pm 7.3$ ), Group D ( $20.8 \pm 8.9$ ) and Group M ( $20.3 \pm 10.3$ ).

### Evaluation of the Radiographic Characteristics

The measurements from the X-rays are shown in Table 3. In Group M, the Van Akkerveeken's lines and Hadley's "S" curves were significantly higher than those in the other two groups ( $P < 0.01$ ,  $P = 0.04$ , respectively), whereas no significant difference was observed in the Ullman lines ( $P = 0.11$ ). In the CT images, compared to Group S and Group D, Group M demonstrated significantly higher osteoarthritic facet degeneration ( $0.26 \pm 0.44$  versus  $0.76 \pm 0.60$  versus  $1.54 \pm 0.69$ , respectively) and different facet tropisms ( $0.29 \pm 0.46$  versus  $0.56 \pm 0.50$  versus  $0.86 \pm 0.35$ , respectively) (Table 4). As shown in Table 5, the greatest degenerative indication was observed in Group M via Pfirrmann grading ( $2.83 \pm 0.44$ ), facet fluid ( $0.85 \pm 0.35$ ), muscle fatty degeneration ( $0.81 \pm 0.40$ ) and modic change ( $1.08 \pm 0.54$ ). The logistic regression analysis results for low back pain ( $VAS \geq 4$ ) revealed that muscle fatty degeneration (95% CI, 1.20–8.51,  $P = 0.02$ ) and facet tropism (95% CI, 1.39–11.37,  $P = 0.01$ ) were independent risk factors (Table 6)

**Table 2** Baseline Characteristics

N					
Characteristics	All (127)	Group S (31)	Group D (59)	Group M (37)	P
Sex					
Male	71	18	34	19	0.80
Female	56	13	25	18	
Age (years)	$50.6 \pm 15.5$	$48.6 \pm 14.3$	$49.5 \pm 15.6$	$54.1 \pm 16.0$	0.26
BMI ( $\text{kg}/\text{m}^2$ )	$24.4 \pm 3.5$	$23.2 \pm 3.9$	$25.0 \pm 3.3$	$24.5 \pm 3.3$	0.07
Follow-up(months)	$20.9 \pm 7.3$	$22.4 \pm 7.3$	$20.8 \pm 8.9$	$20.4 \pm 10.3$	0.74
Surgical level					
L4-5 or above	73	19	38	16	0.11
L5-S1	54	12	21	21	

**Table 3** Radiographic Findings in the X-Rays

	Group S	Group D	Group M	P
Van	$0.13 \pm 0.34$	$0.32 \pm 0.47$	$0.78 \pm 0.42$	<0.01
Hadley	$0.19 \pm 0.40$	$0.41 \pm 0.50$	$0.49 \pm 0.51$	0.04
Ullman	$0.42 \pm 0.50$	$0.56 \pm 0.50$	$0.68 \pm 0.47$	0.11

**Abbreviations:** Van, the Van Akkerveeken's measurements; Hadley, Hadley's "S" curve; Ullman, Ullman's line.

**Table 4** Radiographic Findings in the CT

	Group S	Group D	Group M	P
<b>OF</b>	0.26 ± 0.44	0.76 ± 0.60	1.54 ± 0.69	<0.01
<b>Tropism</b>	0.29 ± 0.46	0.56 ± 0.50	0.86 ± 0.35	<0.01

**Abbreviations:** OF, osteoarthritic facet degeneration grade; Tropism, facet tropism.

**Table 5** Radiographic Findings in the MRI

	Group S	Group D	Group M	P
<b>Pfirmann</b>	0.94 ± 0.51	2.41 ± 0.65	2.83 ± 0.44	<0.01
<b>Modic</b>	0.03 ± 0.18	0.58 ± 0.62	1.08 ± 0.54	<0.01
<b>Fluid</b>	0.10 ± 0.30	0.63 ± 0.49	0.86 ± 0.35	<0.01
<b>Fatty</b>	0.13 ± 0.34	0.42 ± 0.50	0.81 ± 0.40	<0.01

**Abbreviations:** Pfirmann, Pfirmann grading; modic, modic changes; fluid, facet fluid; fatty, muscle fatty degeneration; OF, osteoarthritic facet degeneration grade; tropism, facet tropism.

**Table 6** Logistic Regression Analysis for High Risk Factors for Low Back Pain

	OR	P	Wald	95% CI
<b>Van</b>	2.47	0.06	3.54	0.96–6.34
<b>Hadley</b>	1.46	0.42	0.64	0.58–3.73
<b>OF</b>	1.33	0.39	0.74	0.69–2.55
<b>Tropism</b>	3.98	0.01	6.70	1.39–11.37
<b>Pfirmann</b>	1.11	0.74	0.11	0.60–2.05
<b>Modic</b>	1.26	0.55	0.35	0.59–2.70
<b>Fluid</b>	1.99	0.20	1.64	0.70–5.68
<b>Fatty</b>	3.20	0.02	5.43	1.20–8.51

**Abbreviations:** Van, the Van Akkerveekens' measurements; Hadley, Hadley's "S" curve; OF, osteoarthritic facet degeneration grade; Tropism, facet tropism; Pfirmann, Pfirmann grading; modic, modic changes; Fluid, facet fluid; Fatty, muscle fatty degeneration.

## Patient-Reported Outcomes

For patient-reported outcomes, preoperative symptoms including VAS for leg pain and low back pain and ODI scores were not significantly different among the three groups, and all patients achieved significant clinical relief after surgery (ODI scores,  $P < 0.01$ ; VAS of leg pain,  $P < 0.01$ ; VAS of low back pain,  $P < 0.001$ ). However, the scores of ODI and VAS for low back pain scores in Group M were significantly higher than those in the other two groups at 1 month (VAS scores for low back pain,  $2.6 \pm 0.7$  vs  $3.5 \pm 1.2$  vs  $4.2 \pm 1.4$ , Group S, Group D, Group M, respectively), 3 months (ODI,  $18.7 \pm 4.39$  vs  $21.2 \pm 4.09$  vs  $23.3 \pm 3.87$ ; VAS scores for low back pain,  $2.2 \pm 0.7$  vs  $2.4 \pm 1.1$  vs  $3.9 \pm 1.2$ , Group S, Group D, Group M, respectively), 6 months (ODI,  $16.6 \pm 3.91$  vs  $19.4 \pm 3.75$  vs  $21.4 \pm 4.46$ ; VAS scores for low back pain,  $1.9 \pm 0.5$  vs  $2.2 \pm 1.0$  vs  $3.8 \pm 1.2$ , Group S, Group D, Group My, respectively) and 1 year postoperatively (ODI,  $15.4 \pm 3.71$  vs  $17.0 \pm 3.93$  vs  $20.1 \pm 4.24$ ; VAS scores for low back pain,  $1.8 \pm 1.1$  vs  $2.1 \pm 1.3$  vs  $3.7 \pm 1.1$ , Group S, Group D, Group M, respectively), as shown in Table 7 ( $P < 0.05$ ). Additionally, the VAS (leg pain) scores were not significantly different among the three groups at different time points after percutaneous endoscopic transforaminal discectomy surgery (1 month,  $P = 0.14$ ; 3 months,  $P = 0.09$ ; 6 months,  $P = 0.15$ ; 1 year,  $P = 0.08$ ).

**Table 7** Comparison of ODI Scores, VAS (Leg Pain) and VAS (Low Back Pain)

	Group S	Group D	Group M	P value
ODI scores				
Preoperative	60.1 ± 9.66	61.5 ± 9.97	64.7 ± 8.05	0.11
3 months	18.7 ± 4.39	21.2 ± 4.09	23.3 ± 3.87	<0.01*
6 months	16.6 ± 3.91	19.4 ± 3.75	21.4 ± 4.46	<0.01*
1 year	15.4 ± 3.71	17.0 ± 3.93	20.1 ± 4.24	<0.01*
VAS (leg pain)				
Preoperative	5.9 ± 1.8	6.1 ± 1.4	6.6 ± 1.3	0.12
1 month	1.4 ± 0.7	1.7 ± 0.9	1.8 ± 1.0	0.14
3 months	1.1 ± 0.3	1.2 ± 0.5	1.4 ± 0.9	0.09
6 months	0.8 ± 0.4	1.0 ± 0.5	1.1 ± 0.6	0.15
1 year	0.6 ± 0.5	0.7 ± 0.5	0.8 ± 0.5	0.08
VAS (low back pain)				
Preoperative	5.4 ± 0.7	5.7 ± 1.6	6.1 ± 1.2	0.14
1 month	2.6 ± 0.7	3.5 ± 1.2	4.2 ± 1.4	<0.01*
3 months	2.2 ± 0.7	2.4 ± 1.1	3.9 ± 1.2	<0.01*
6 months	1.9 ± 0.5	2.2 ± 1.0	3.8 ± 1.2	<0.01*
1 year	1.8 ± 1.1	2.1 ± 1.3	3.7 ± 1.1	<0.01*

**Note:** \*Statistically significant among Group Stable, Group Dysfunctional and Group Microinstability.

## Discussion

The CLBP after PTED surgery was associated with an increased incidence of postoperative complications and decreased patient satisfaction.<sup>23</sup> Various studies have reported the risk factors for CLBP after PTED, which include BMI, level of surgery, paraspinal muscle degeneration, sex and Modic changes,<sup>24,25</sup> but lumbar instability is the first consideration.<sup>26</sup> Theoretically, a stable lumbar spine is one of the surgical indications, and PTED is not a good choice for patients with lumbar instability. The most commonly used method to evaluate lumbar instability is flexion and extension standing radiographs, so it is significant to know whether this method is accurate or not.

Recently, Landi et al<sup>12</sup> proposed a new clinical test and defined the vertebral segment according to the specific dysfunctional condition without the presence of an obvious instability, such as those with MI, using preoperative radiological examinations. Spinal functional units (SFUs) with MI will have disordered biomechanics, rendering them unable to perform physiological functions well and resulting in spinal degenerative disease and low back pain. Furthermore, their findings demonstrated that MI at the involved segments has good predictive value for adjacent segment disease (ASD) after instrument and fusion surgery.

These theoretical considerations can also be applied to patients who have undergone PTED, almost all of whom have biomechanical problems in the lumbar spine, which may be caused by the dysfunction of the SFU and result in clinical symptoms. In addition, the most commonly used dynamic X-rays for detecting lumbar instability may be less sensitive. Chen et al<sup>27</sup> reported that flexion was limited subsequent to aggravated back pain, which appeared during a forward bending posture when instructed to “bend forward from your lower back as low as possible, do not stick out your buttocks” and was accurately diagnosed, and treatment was therefore limited at the same time.

Patients in our study with CLBP had an average MI score of 9.84, which indicated that, for this subset of patients, operative levels of MI and dysfunctional lumbar units were present. However, the outcome evaluated by dynamic X-rays was “stable”. Such a large difference may be related to use of the biomechanical assessment method. When using the entire spine as a spinal functional unit for evaluation, multiple pieces of information may be ignored due to many limitations, including aggravated back pain and body position changes. Nevertheless, MI, a concept parallel to vertebral instability, considers lumbar degenerative disease a dysfunction of an individual, the spinal motor unit and is defined as “active discopathy” and described as configuring the first phase of the degenerative cascade. The biomechanical function of the spinal motor unit demands assessment using various radiological data and can divide the level of dysfunction into three classes: the stable level (scores of 0–3), the dysfunctional level (scores of 4–8), and the microinstability level (scores of 9–14). Our study demonstrated that class 3 (the microinstability level) is associated with relevant pathoanatomic alterations, with high clinical relevance for CLBP after PTED surgery. Meanwhile, this outcome indicates that many radiographic characteristics need to be taken into account before choosing surgical treatments instead of evaluating lumbar instability with dynamic X-rays only.

On the X-ray evaluations, our results revealed that the Van Akkerveeken’s lines and the “Hadley” curve were significantly different among the three groups. The Van Akkerveeken’s lines are the distance between the crossing of the two lines and the posterior wall of the vertebral body. When the outcome of the measurements is greater than 1.5 mm in lateral projections, it indicates damage to the posterior ligaments and a high disc. The Hadley’s “S” curve is an S-shaped line that passes through the lower edge of the transverse process and the outer edge of the engagement block. A break in the S-shaped line indicates subluxation of the facet. Radcliff et al<sup>28</sup> demonstrated that the complete posterior ligament complex is conducive to maintaining the stability of the lumbar spine and has good clinical efficacy, which was similar to the results of our study. When damage to the ligament complex occurs, force from the ligaments will be placed on the lumbar disc, facet joints or lumbar vertebrae, which results in SFU dysfunction. In addition, Farajpour et al<sup>29</sup> found that bracing the ligament complex at an optimal angle is highly effective in reducing low back pain, which indicates that ligaments, fractures and biomechanical function all play a significant role in lumbar stability. Furthermore, a high disc may indicate solid nucleus pulposus tissue. When the ligament complex is damaged, tremendous pressure acts on the lumbar intervertebral disc directly, which may cause disc-originating low back pain but not affect the slip distance in dynamic X-rays.

Additionally, the patients in Group M demonstrated that a higher osteoarthritic facet degeneration and asymmetrical facet joints (facet tropism) were associated with CLBP. The osteoarthritic facet degeneration grade is an assessment of the degree of facet joint osteoarthritis. The facet joint has only one synovial joint, including the joint capsule, synovium, and hyaline cartilage that covers the subchondral bone. Duc et al<sup>30</sup> indicated that facet tropism could cause torsion during lumbar flexion and extension, increase the shear force on the spine, and be associated with degenerative osteoarthritis of the facet joint, which can reduce the stability of the lumbar spine, as found in our study. Similarly, Ko et al<sup>31</sup> reported a correlation among facet tropism, herniated nucleus pulposus and spondylolisthesis, and they showed that CLBP was associated with facet tropism at the lumbar spine in a selected community-based populations. Based on the findings of the above studies, facet tropism and facet joint osteoarthritis are likely important mechanisms contributing to MI, and facet tropism may be the initiating factor. This may also explain why facet tropism is an independent factor correlated with CLBP according to the multivariate logistic regression analysis in our study.

Our results support the hypothesis that the condition of the whole SFU, including the lumbar disc, facet joints and lumbar multifidus muscle, is involved in CLBP after PTED surgery. According to the MRI, Group M was characterized by more degenerated discs, facet fluid and a weaker lumbar multifidus muscle than the other groups. Our study indicates that CLBP may originate from the posterior elements of the SFU. The fatty infiltration of the lumbar multifidus muscle may provide insufficient muscular strength, which gives rise to disc degeneration and causes pain and instability of the spine.<sup>32</sup> In addition, facet joint fluid is a known source of low back pain, and the underlying reasons may be related to CLBP. More facet fluid may predict a lower disc height and a disordered spinal functional unit. In a previous study, Snoddy et al<sup>33</sup> demonstrated that facet fluid has a close relationship with dynamic instability and that patients can achieve significant improvement in low back pain following posterior lumbar instrumentation and fusion. The clinical results support that PTED may be a less effective treatment for patients with high MI scores.

There are several limitations to this study. First, the current study is a retrospective cohort study, which means that the level of evidence is not substantially high. Second, this study only included 127 patients who underwent PTED surgery at our single center, which may be subject to some biases, including misclassification and selection bias. Second, the radiological parameters on X-rays are not routine evaluation methods; however, they have the potential to guide surgical decision-making, as they are capable of revealing whether the lumbar spine is unstable or dysfunctional, especially for patients with high expectations regarding symptom relief after PTED surgery.<sup>26,27</sup> Finally, further studies are needed to clarify whether patients with MI might take advantage of fusion or dynamic stabilization.

## Conclusions

In conclusion, this study found a positive association between CLBP and MI or dysfunctional SFUs, and the evaluation of the function of an SFU should depend on complete radiographic outcomes rather than on standing lumbar flexion and extension only. The findings of this analysis suggest that patients with MI could not achieve good improvement in low back pain after PTED. Patients with lumbar microinstability may need to take internal fixation surgery to solve their symptoms.

## Abbreviations

MI, lumbar microinstability; LDH, lumbar disc herniation; PTED, percutaneous endoscopic transforaminal discectomy; CLBP, chronic low back pain; ODI, Oswestry Disability Index; VAS, visual analogue scale; ASD, adjacent segment disease; SFU, spinal functional unit.

## Data Sharing Statement

The datasets used and/or analysed during the current study are not publicly available due to the patients asking for privacy but are available from the corresponding author on reasonable request.

## Ethics Approval and Consent to Participate

The study was observational and not experimental and did not involve human tissues. The data used was collected from the hospital. All treatments were performed according to relevant guidelines and rules and informed consent was obtained from all participants. The ethics committee of Zhejiang Hospital approved the study. We followed the Declaration of Helsinki guidelines.

## Consent for Publication

The details of any images, videos, recordings, etc can be published, and that the person(s) providing consent have been shown the article contents to be published.

## Funding

There is no funding to report.

## Disclosure

The authors declare that there are no conflicts of interest in this work.

## References

1. Gibson J, Waddell G. Surgical interventions for lumbar disc prolapse: update cochrane review. *Spine*. 2007;32(16):1735–1747. doi:10.1097/BRS.0b013e3180bc2431
2. Cao J, Huang W, Wu T, Jia J, Cheng X. Percutaneous endoscopic lumbar discectomy for lumbar disc herniation as day surgery - short-term clinical results of 235 consecutive cases. *Medicine*. 2019;98(49):e18064. doi:10.1097/MD.00000000000018064
3. Gadjradj PS, Rubinstein SM, Peul WC, et al. Full endoscopic versus open discectomy for sciatica: randomised controlled non-inferiority trial. *BMJ*. 2022;376:e065846. doi:10.1136/bmj-2021-065846
4. Gadjradj PS, Broulikova HM, van Dongen JM, et al. Cost-effectiveness of full endoscopic versus open discectomy for sciatica. *Br J Sports Med*. 2022. doi:10.1136/bjsports-2021-104808
5. Lequin MB, Verbaan D, Jacobs WC, et al. Surgery versus prolonged conservative treatment for sciatica: 5-year results of a randomised controlled trial. *BMJ Open*. 2013;3(5):e002534. doi:10.1136/bmjopen-2012-002534

6. Liu X, Yuan S, Tian Y, et al. Comparison of percutaneous endoscopic transforaminal discectomy, microendoscopic discectomy, and microdiscectomy for symptomatic lumbar disc herniation: minimum 2-year follow-up results. *J Neurosurg Spine*. 2018;28(3):317–325. doi:10.3171/2017.6.SPINE172
7. Lv B, Yuan J, Ding H, et al. Relationship between endplate defects, modic change, disc degeneration, and facet joint degeneration in patients with low back pain. *Biomed Res Int*. 2019;2019:9. doi:10.1155/2019/9369853
8. Iguchi T, Ozaki T, Chin T, et al. Intimate relationship between instability and degenerative signs at L4/5 segment examined by flexion-extension radiography. *Eur Spine J*. 2011;20(8):1349–1354. doi:10.1007/s00586-011-1793-7
9. Matz PG, Meagher RJ, Lamer T, et al. Guideline summary review: an evidence-based clinical guideline for the diagnosis and treatment of degenerative lumbar spondylolisthesis. *Spine J*. 2016;16(3):439–448. doi:10.1016/j.spinee.2015.11.055
10. Chan V, Marro A, Rempel J, Nataraj A. Determination of dynamic instability in lumbar spondylolisthesis using flexion and extension standing radiographs versus neutral standing radiograph and supine MRI. *J Neurosurg Spine*. 2019;1–7. doi:10.3171/2019.2.SPINE181389
11. Nguyen C, Poiraudau S, Rannou F. From Modic 1 vertebral-endplate subchondral bone signal changes detected by MRI to the concept of ‘active discopathy’. *Ann Rheum Dis*. 2015;74(8):1488–1494. doi:10.1136/annrheumdis-2015-207317
12. Landi A, Gregori F, Mancarella C, et al. Lumbar spinal degenerative “microinstability”: hype or hope? Proposal of a new classification to detect it and to assess surgical treatment. *Eur Spine J*. 2015;24(suppl 7):872–878. doi:10.1007/s00586-015-4274-6
13. Cabraja M, Mohamed E, Koeppen D, Kroppenstedt S. The analysis of segmental mobility with different lumbar radiographs in symptomatic patients with a spondylolisthesis. *Eur Spine J*. 2012;21(2):256–261. doi:10.1007/s00586-011-1870-y
14. Fujiwara A, Tamai K, Yamato M, et al. The relationship between facet joint osteoarthritis and disc degeneration of the lumbar spine. *Eur Spine J*. 1999;8:396–401. doi:10.1007/s005860050193
15. Anatomic A, An HS, Lim T-H, Haughton VM. Morphologic changes in the lumbar intervertebral foramen due to flexion-extension, lateral bending, and axial rotation. *Spine*. 2001;26(8):876–882. doi:10.1097/00007632-200104150-00010
16. Griffith J, Wang F, Antonio G, et al. Modified Pfirrmann grading system for lumbar intervertebral disc degeneration. *Spine J*. 2007;32(24):E708–E12. doi:10.1097/BRS.0b013e31815a59a0
17. Paul F, Yu L-P, Qian -W-W, Yin G-Y, Ren Y-X, Hu Z-Y. MRI assessment of lumbar intervertebral disc degeneration with lumbar degenerative disease using the pfirrmann grading systems. *PLoS One*. 2012;7(12):e48074. doi:10.1371/journal.pone.0048074
18. Bianchi M, Peterson CK, Pfirrmann CW, Hodler J, Bolton J. Are the presence of MODIC changes on MRI scans related to “improvement” in low back pain patients treated with lumbar facet joint injections? *BMC Musculoskelet Disord*. 2015;16:234. doi:10.1186/s12891-015-0688-x
19. Rahme R, Moussa R. The modic vertebral endplate and marrow changes: pathologic significance and relation to low back pain and segmental instability of the lumbar spine. *AJNR Am J Neuroradiol*. 2008;29(5):838–842. doi:10.3174/ajnr.A0925
20. Maatta JH, Karppinen JI, Luk KD, Cheung KM, Samartzis D. Phenotype profiling of Modic changes of the lumbar spine and its association with other MRI phenotypes: a large-scale population-based study. *Spine J*. 2015;15(9):1933–1942. doi:10.1016/j.spinee.2015.06.056
21. Chaput C, Padon D, Rush J, Lenehan E, Rahm M. The significance of increased fluid signal on magnetic resonance imaging in lumbar facets in relationship to degenerative spondylolisthesis. *Spine J*. 2007;32(17):1883–1887. doi:10.1097/BRS.0b013e318113271a
22. Mengiardi B, Schmid M, Boos N, et al. Fat content of lumbar paraspinal muscles in patients with chronic low back pain and in asymptomatic volunteers: quantification with MR spectroscopy. *Radiology*. 2006;240:786–792. doi:10.1148/radiol.2403050820
23. Yu P, Qiang H, Zhou J, Huang P. Percutaneous transforaminal endoscopic discectomy versus micro-endoscopic discectomy for lumbar disc herniation. *Med Sci Monit*. 2019;25:2320–2328. doi:10.12659/MSM.913326
24. Beack JY, Chun HJ, Bak KH, Choi KS, Bae IS, Kim KD. Risk factors of secondary lumbar discectomy of a herniated lumbar disc after lumbar discectomy. *J Korean Neurosurg Soc*. 2019;62(5):586–593. doi:10.3340/jkns.2019.0085
25. Wang H, Wang T, Wang Q, Ding W. Incidence and risk factors of persistent low back pain following posterior decompression and instrumented fusion for lumbar disk herniation. *J Pain Res*. 2017;10:1019–1025. doi:10.2147/JPR.S132862
26. Landi A, Gregori F, Marotta N, Donnarumma P, Delfini R. Hidden spondylolisthesis: unrecognized cause of low back pain? Prospective study about the use of dynamic projections in standing and recumbent position for the individuation of lumbar instability. *Neuroradiology*. 2015;57(6):583–588. doi:10.1007/s00234-015-1513-9
27. Chen X, Zhou QS, Xu L, et al. Does kyphotic configuration on upright lateral radiograph correlate with instability in patients with degenerative lumbar spondylolisthesis? *Clin Neurol Neurosurg*. 2018;173:96–100. doi:10.1016/j.clineuro.2018.07.020
28. Radcliff K, Su BW, Kepler CK, et al. Correlation of posterior ligamentous complex injury and neurological injury to loss of vertebral body height, kyphosis, and canal compromise. *Spine*. 2012;37(13):1142–1150. doi:10.1097/BRS.0b013e318240fcd3
29. Farajpour H, Jamshidi N. Effects of different angles of the traction table on lumbar spine ligaments: a finite element study. *Clin Orthop Surg*. 2017;9(4):480–488. doi:10.4055/cios.2017.9.4.480
30. Do DH, Taghavi CE, Fong W, Kong MH, Morishita Y, Wang JC. The relationship between degree of facet tropism and amount of dynamic disc bulge in lumbar spine of patients symptomatic for low back pain. *Eur Spine J*. 2011;20(1):71–78. doi:10.1007/s00586-010-1558-8
31. Ko S, Chae S, Choi W, Kim JY, Kwon J, Doh J. The prevalence of facet tropism and its correlation with low back pain in selected community-based populations. *Clin Orthop Surg*. 2019;11(2):176–182. doi:10.4055/cios.2019.11.2.176
32. Faur C, Patrascu JM, Haragus H, Anglitoiu B. Correlation between multifidus fatty atrophy and lumbar disc degeneration in low back pain. *BMC Musculoskelet Disord*. 2019;20(1):414. doi:10.1186/s12891-019-2786-7
33. Snoddy MC, Sielatycki JA, Sivaganesan A, Engstrom SM, McGirt MJ, Devin CJ. Can facet joint fluid on MRI and dynamic instability be a predictor of improvement in back pain following lumbar fusion for degenerative spondylolisthesis? *Eur Spine J*. 2016;25(8):2408–2415. doi:10.1007/s00586-016-4525-1

**Journal of Pain Research**

Dovepress

**Publish your work in this journal**

The Journal of Pain Research is an international, peer reviewed, open access, online journal that welcomes laboratory and clinical findings in the fields of pain research and the prevention and management of pain. Original research, reviews, symposium reports, hypothesis formation and commentaries are all considered for publication. The manuscript management system is completely online and includes a very quick and fair peer-review system, which is all easy to use. Visit <http://www.dovepress.com/testimonials.php> to read real quotes from published authors.

Submit your manuscript here: <https://www.dovepress.com/journal-of-pain-research-journal>