


# Hypopigmented Mycosis Fungoides: A Clinicopathological Review of 32 Patients

Hao-ze Shi , Yi-qun Jiang, Xiu-lian Xu, Wei Zhang, Hao Song, Xiao-po Wang, Xue-si Zeng, Jian-fang Sun, Hao Chen

Department of Pathology, Institute of Dermatology, Chinese Academy of Medical Sciences and Peking Union Medical College, Nanjing, 210042, People's Republic of China

Correspondence: Hao Chen; Jian-fang Sun, Department of Pathology, Institute of Dermatology, Chinese Academy of Medical Sciences and Peking Union Medical College, Nanjing, 210042, Email [ch76ch@163.com](mailto:ch76ch@163.com); [fangmin5758@aliyun.com](mailto:fangmin5758@aliyun.com)

**Background:** Hypopigmented mycosis fungoides (hMF) is gradually acknowledged by more dermatologists, yet a consensus regarding its characteristics is not reached. The profile of Chinese hMF patients has not been deeply reviewed previously. Our research may contribute to the understanding of hMF, especially the Chinese patients with Fitzpatrick phototypes of III and IV.

**Aim:** To have a better understanding of hMF in terms of clinical, histopathological and immunohistochemical features in the Chinese population and to determine if there are differences between the Chinese population and other ethnic groups.

**Methods:** We made a retrospective analysis of clinical, histopathological and immunohistochemical features of 32 hMF patients in our hospital from 2010 to 2020. These features were then summarized and compared with previous reports.

**Results:** All patients belonged to Fitzpatrick phototypes of III or IV. Twenty-one male (65.63%) patients and 11 female (34.37%) patients were analyzed, and the male to female ratio was 1.9:1. The age at diagnosis of patients ranged from 4 to 39 years, and the average age at diagnosis of these patients was 18 years, the median age was 16.5. Back was the most frequent site (34.37%). The clinical and histological results of lesions had no distinctive points. Immunohistochemically, among these 32 patients, there were 30 patients whose information was complete, there was 19 patients (63.33%) who were CD8 positive lymphocytes predominance, 9 patients (30%) had CD8 and CD4 positive lymphocyte mixed infiltration, and other 2 patients (6.67%) had CD4 positive lymphocytes predominance. Partial loss of CD7 was only observed in 1 patient (3.33%). Nearly all patients adopted topical nitrogen mustard and topical steroid and most of them had an excellent prognosis.

**Conclusion:** The clinical profiles of hMF in Chinese population shared differences with other ethnic groups, but its histopathological, immunohistochemical results and prognosis condition were resembled with other previous reports. Hence, more patients were needed to find the characteristics of hMF.

**Keywords:** hypopigmented, mycosis fungoides, cutaneous, MF

## Introduction

Hypopigmented mycosis fungoides (hMF) is a rare subtype of mycosis fungoides (MF) which generally affects children and adolescents with darker skin types (Fitzpatrick types IV–VI) and the Asian population.<sup>1</sup> Compared with classic MF, hMF often has a better prognosis.<sup>2</sup> Clinically, it usually presents as hypopigmented plaque with a fine scale which could be misdiagnosed as vitiligo, pityriasis alba, ichthyosis or Hansen's disease. In terms of immunohistochemical results, hMF has similar histological presentation with classic MF, but hMF is identified by CD8 positive profile instead of CD4.<sup>3</sup> Currently, there have been more hMF cases reported worldwide. However, there is less literature to describe the general condition of hMF in the Asian population, especially Chinese patients. Therefore, in order to understand the hMF in the Chinese population more deeply, we made a retrospective analysis and review of 32 hMF patients diagnosed in our hospital from 2010 to 2020.

## Methods

During the period January 2010–October 2020, based on the clinical, histopathological and immunohistochemical results, there were 32 patients diagnosed as having hMF at the Institute of Dermatology, Chinese Academy of Medical Sciences. The information of these cases was recorded electronically. All cases were pure hypopigmented MF without lesions of classic MF confirmed by at least 2 dermatologists. Paraffin-embedded sections were commonly stained with hematoxylin and eosin (H&E). Immunohistochemistry was performed using an autostainer (Autostainer link45 System, Dako, Denmark). Antibodies including CD3, CD4, CD5, CD7, CD8, CD20, CD30, CD79a were used (all the antibodies were purchased from Dako, Denmark). The chromogen was DAB. The criteria applied to diagnose hMF included clinical presentations and results of skin biopsy like histopathological and immunohistochemical results. Also, an indolent course was also a useful clue. A predominance of CD8 or CD4 represented the percentage was higher than 70%. The results were analyzed by six independent dermatologists (H Chen, XL Xu, YQ Jiang, W Zhang, XP Wang and H Song). Statistical analyses were performed using IBM SPSS Statistics 23.

## Results

Among these patients, all patients belonged to Fitzpatrick phototypes of III or IV. There were 21 male (65.63%) patients and 11 female (34.37%) patients, and the male to female ratio was 1.9:1 (Table 1). The age at diagnosis of these patients ranged from 4 to 39 years. The average age at diagnosis of these patients was 18 years and the median age was 16.5 years (Table 1). In terms of location, all patients had their lesions on the trunk and limbs, and back (34.37%) was the most frequent site among our patients (Table 1). The lesion often presented as hypopigmented plaque or patch without obvious feelings (Figure 1). Histopathologically, hMF has similar features as classic MF. Most of our patients showed atypical lymphocytes lined up at the basal layer of the epidermis and the phenomenon of epidermotropism was frequent (Figure 2A, D and G). Immunohistochemically, the predominance of CD8 positive lymphocytes was more common (Table 1), which was different from classic MF. Among these 32 patients, immunohistochemical information of 30 patients was complete. There were 19 patients (63.33%) who had CD8 positive lymphocytes predominance (Figure 2B and C), 9 patients (30%) had CD8 and CD4 positive lymphocyte mixed infiltration (Figure 2E and F), and another 2 patients (6.67%) had CD4 positive lymphocytes predominance (Figure 2H and I). We only observed one patient (3.33%) had a partial loss of CD7 in 11 patients who underwent CD7 staining (Table 1).

The treatment methods we prescribed for patients were topical nitrogen mustard and topical steroid rather than narrow band ultraviolet B (NB-UVB) or ultraviolet A cabins associated with the use of psoralen (PUVA). All patients (100%) could have a repigmentation treated only with topical nitrogen mustard and steroid gradually with different duration. Thirty patients (93.75%) had an excellent prognosis, only 2 patients (6.25%) reported that the condition was not promising but then they were both lost to follow-up. Among 30 patients whose immunohistochemical information was complete, these 2 patients (6.67%) were generally older than other patients (23-year-old female and 32-year-old male), and their CD4/CD8 was in a mixed pattern.

## Discussion

hMF is a rare subtype of MF. Generally, hMF has an excellent prognostic outcome and immunohistochemical results are different from classic MF. Patients generally shared a non-specific clinical presentation which resembled vitiligo, pityriasis alba, ichthyosis or post-inflammatory hypochromia. It generally affects children and adolescents with darker skin types (Fitzpatrick types IV–VI). hMF could be a solely manifestation or coexist with other subtypes of MF.<sup>4</sup> The Chinese population nearly all belongs to Fitzpatrick types III–IV, and literature regarding hMF in the Chinese population is rare. We collected and reviewed 32 cases of pure hMF in our hospital to find out if there were some special features in the Chinese population.

The male to female ratio of these 32 patients was 1.9:1, which was not in accordance with some previous literatures reporting that gender predilection was not obvious.<sup>5–8</sup> A report also found that male to female ratio was 1:1.45, which was also different from our results.<sup>9</sup> Shabrawi-Caelen et al<sup>10</sup> observed an obvious female predominance with a male to female ratio of 4:11. There was also a report proposed by Boulos et al which was in agreement with our results, concluding that CD8 positive

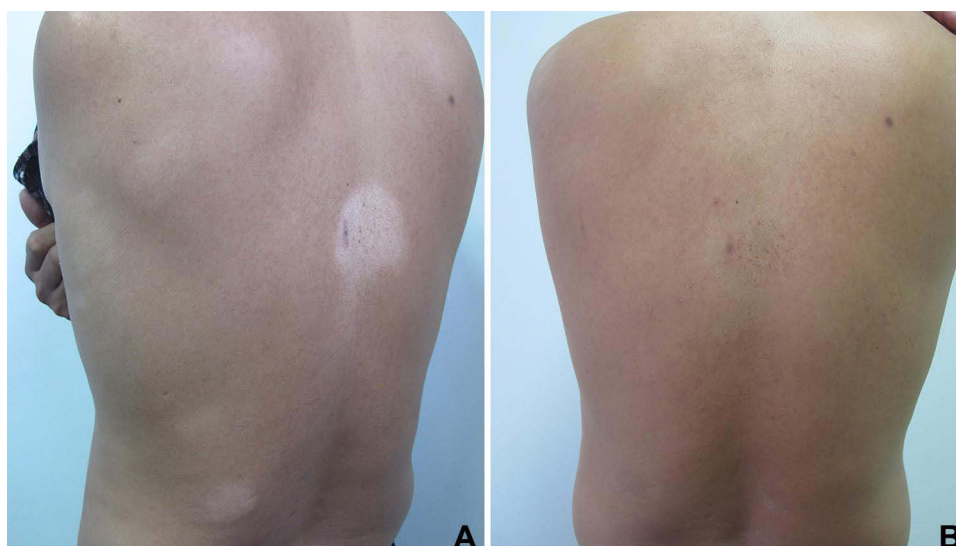**Table I** Clinical, Immunohistological Information of 32 hMF Patients

Patient No.	Age	Gender	Location	CD4/CD8	CD7 Loss	Average Follow-Up Time
1	19	Male	Back	Mixed infiltration	N/A	79 M
2	10	Female	Buttocks	CD4 predominance	N/A	79 M
3	18	Male	Abdomen	CD8 predominance	N/A	68 M
4	13	Male	Waist	N/A	N/A	67 M
5	11	Male	Back	CD8 predominance	N/A	66 M
6	4	Male	Abdomen	Mixed infiltration	N/A	56 M
7	9	Male	Buttocks	CD8 predominance	Partial loss	56 M
8	14	Male	Buttocks	CD8 predominance	N/A	53 M
9	11	Male	Legs	CD8 predominance	N/A	53 M
10	32	Male	Left leg	CD8 predominance	N/A	53 M
11	11	Male	Back	CD8 predominance	N/A	52 M
12	19	Male	Back	CD8 predominance	N/A	51 M
13	29	Male	Back	Mixed infiltration	Positive	51 M
14	31	Female	Waist	Mixed infiltration	N/A	45 M
15	39	Female	Right leg	CD4 predominance	N/A	44 M
16	7	Male	Left arm, abdomen	N/A	N/A	42 M
17	10	Male	Abdomen	CD8 predominance	N/A	42 M
18	23	Female	Left arm, abdomen	Mixed infiltration	N/A	42 M
19	15	Female	Legs	CD8 predominance	N/A	41 M
20	26	Female	Left arm, right leg	CD8 predominance	N/A	41 M
21	29	Male	Back, arms	Mixed infiltration	Positive	41 M
22	10	Female	Back	CD8 predominance	N/A	37 M
23	9	Male	Buttocks	Mixed infiltration	Positive	29 M
24	31	Male	Back	CD8 predominance	N/A	27 M
25	10	Female	Right arm, left leg	CD8 predominance	Positive	19 M
26	21	Male	Back	CD8 predominance	Positive	7 M
27	4	Male	Buttocks	Mixed infiltration	Positive	7 M
28	11	Male	Buttocks	CD8 predominance	Positive	6 M
29	32	Female	Buttocks	Mixed infiltration	Positive	5 M
30	21	Female	Back	CD8 predominance	Positive	5M
31	25	Female	Back	CD8 predominance	Positive	3M
32	22	Male	Buttocks	CD8 predominance	N/A	3 M

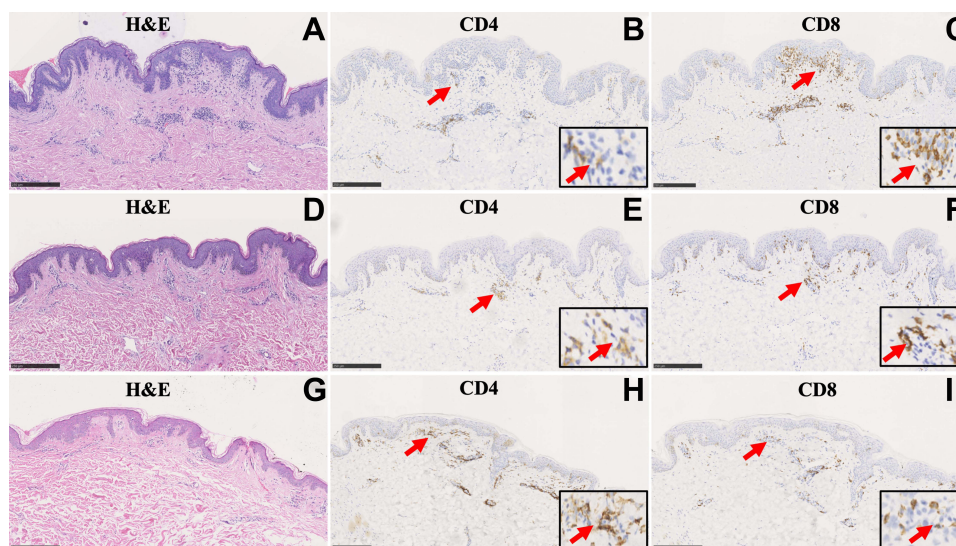
juvenile MF had a male predominance, with a male to female ratio of 2:1.<sup>11</sup> A study of hMF in 27 Egyptian patients also showed a male to female ratio of 2:1.<sup>4</sup> Khopkar et al<sup>12</sup> also noticed a male predominance (2:1) in 15 hMF patients. Furthermore, a research from Mexico also noticed a male predominance in 48 hMF patients, out of which 60% of patients were men.<sup>13</sup>

Compared with previous reports, the average age of our patients was relatively lower. But there were also some reports claiming that the average age was 12 years,<sup>8</sup> which were lower than our results. There were 47 patients (31 were Chinese) diagnosed with hMF in Singapore and the average age of diagnosis of these patients was 21.6 years,<sup>7</sup> which was similar with our results, but the age of involved patients ranged from 4 to 51 years. A Mexican study covered 48 hMF patients also reported that the mean age at diagnosis was 27.3 years.<sup>13</sup> Khopkar et al<sup>12</sup> proposed that the average age at the time of diagnosis was 32.2 years with the age range being 7–65 years. And Rodney et al in their research proposed that the age of patients ranged from 4 to 57 years, with an average of 37.5 years.<sup>6</sup> The mean age of patients at the onset of disease in Egyptian patients diagnosed as hMF was 35.39±13.13.<sup>4</sup> The average age of these reports was generally higher than our reports. Above all, although hMF was commonly seen in children and adolescents, the age range was relatively extensive.

The lesions mostly occurred on the trunk, and the back (34.37%) was the most frequent site in our patients. hMF had similar histopathological presentations with classic MF and perhaps multiple biopsies were needed since some



**Figure 1** (A) The lesions of hMF generally presented as hypopigmented plaque or patch without obvious feelings. (B) The lesions of this patients were relieved obviously treated with topical nitrogen mustard combined with topical glucocorticoid for 1 year.



**Figure 2** (A, D and G) showed the typical histopathological presentation of hMF, namely, atypical lymphocytes lined up at the basal layer of the epidermis and the phenomenon of epidermotropism could be noticed. (B, E and H) showed CD4 staining (100×). (C, F and I) showed CD8 staining (100×). (A–C) showed a hMF patient with CD8 positive lymphocytes predominance. (D–F) showed a hMF patient with CD8 and CD4 positive lymphocyte mixed infiltration. (G–I) showed a hMF patient with CD4 positive lymphocytes predominance. Red arrows mean abnormal lymphocytes with the positive staining.

histological features may not typical. Amorim et al<sup>5</sup> reported that between 1 and 5 biopsies were needed, the average number 2.5 biopsies.

Immunohistochemically, the predominance of CD8 positive lymphocytes (63.33%) was more common in hMF, which was different from classic MF. Our results were in agreement with such finding. Besides, only 1 patient (3.33%) in 9 who underwent CD7 staining was positive, which was not in keeping with previous reports claiming that CD7 loss in hMF was a common phenomenon.

Generally, the methods taken for the treatment of hMF were narrow band ultraviolet B (NB-UVB) or ultraviolet A cabins associated with the use of psoralen (PUVA), since these phototherapies could achieve a relatively fast response. Yet, nearly all patients adopted the method of topical nitrogen mustard and topical steroid and all of them could get relief and repigmentation. This treatment method was also taken by Rodney et al.<sup>6</sup> The 2 patients mentioned above who had



a relatively worse prognosis were identified with mixed pattern of CD4 and CD8, and they were older than most patients. Thus, we wondered that whether age combined with CD4/CD8 infiltration pattern could be the prognostic clues for hMF, but we need more evidence to confirm such speculation. It has been reported that CD8 positive T cell plays a protective role in classic MF.<sup>6</sup> De Marchi et al<sup>14</sup> reported that co-expression of CD4 and CD8 in cutaneous diseases was associated with low rate of progression. Yet, there was an opinion proposed by Jaque et al<sup>15</sup> stating that atypical immunophenotype perhaps had no effect on progression and transformation of MF. Therefore, perhaps the role of CD8 expression in hMF, was still controversial.

In summary, the profile of hMF patients involved in our study shared some similarities, but also differences, with previous reports. More patients are needed to conclude the definite features of hMF in Chinese population, especially the aspects of treatment and prognosis.

## Consent Statements

This study was approved by the ethical committees of Institute of Dermatology, Chinese Academy of Medical Sciences. All the patients signed a written informed consent to participate in this study, in accordance with the Declaration of Helsinki. A parent or legal guardian of patients under 18 years of age was provided informed consent.

## Funding

This work was supported by the Nanjing Incubation Program for National Clinical Research Center (2019060001), the Natural Science Foundation of Jiangsu Province Grant (BK20211026) and Medical scientific research project approved by Jiangsu Provincial Health Commission (M2021045).

## Disclosure

The authors declare no conflicts of interest in this work.

## References

1. Castano E, Glick S, Wolgast L, et al. Hypopigmented mycosis fungoides in childhood and adolescence: a long-term retrospective study. *J Cutan Pathol*. 2013;40:924–934. doi:10.1111/cup.12217
2. Jung JM, Lee MY, Won CH, et al. Hyperpigmented mycosis fungoides: a retrospective and comparative analysis with other subtypes of mycosis fungoides. *Leuk Lymphoma*;2022. 1–9. doi:10.1080/10428194.2022.2043303
3. Reiter O, Amitay-Laish I, Oren-Shabtai M, et al. Paediatric mycosis fungoides - characteristics, management and outcomes with particular focus on the folliculotropic variant. *J Eur Acad Dermatol Venereol*. 2022;36:671–679. doi:10.1111/jdv.17971
4. Hassab-El-Naby HM, El-Khalawany MA. Hypopigmented mycosis fungoides in Egyptian patients. *J Cutan Pathol*. 2013;40:397–404. doi:10.1111/cup.12093
5. Amorim GM, Niemeyer-Corbellini JP, Quintella DC, et al. Hypopigmented mycosis fungoides: a 20-case retrospective series. *Int J Dermatol*. 2018;57:306–312. doi:10.1111/ijd.13855
6. Rodney IJ, Kindred C, Angra K, et al. Hypopigmented mycosis fungoides: a retrospective clinicohistopathologic study. *J Eur Acad Dermatol Venereol*. 2017;31:808–814. doi:10.1111/jdv.13843
7. Tan ES, Tang MB, Tan SH. Retrospective 5-year review of 131 patients with mycosis fungoides and Sézary syndrome seen at the National Skin Centre, Singapore. *Australas J Dermatol*. 2006;47:248–252. doi:10.1111/j.1440-0960.2006.00290.x
8. Valencia Ocampo OJ, Julio L, Zapata V, et al. Mycosis Fungoides in Children and Adolescents: a Series of 23 Cases. *Actas Dermosifiliogr*. 2020;111:149–156. doi:10.1016/j.ad.2019.04.004
9. Jayasinghe DR, Dissanayake K, de Silva MVC. Comparison between the histopathological and immunophenotypical features of hypopigmented and nonhypopigmented mycosis fungoides: a retrospective study. *J Cutan Pathol*. 2020;48(4):486–494. doi:10.1111/cup.13882
10. El-Shabrawi-Caelen L, Cerroni L, Medeiros LJ, et al. Hypopigmented mycosis fungoides: frequent expression of a CD8+ T-cell phenotype. *Am J Surg Pathol*. 2002;26(4):450–457. doi:10.1097/00000478-200204000-00006
11. Boulous S, Vaid R, Aladily TN, et al. Clinical presentation, immunopathology, and treatment of juvenile-onset mycosis fungoides: a case series of 34 patients. *J Am Acad Dermatol*. 2014;71:1117–1126. doi:10.1016/j.jaad.2014.07.049
12. Khopkar U, Doshi BR, Dongre AM, et al. A study of clinicopathologic profile of 15 cases of hypopigmented mycosis fungoides. *Indian J Dermatol Venereol Leprol*. 2011;77:167–173. doi:10.4103/0378-6323.77456
13. Domínguez-Gómez MA, Baldassarri-Ortego LF, Morales-Sánchez MA. Hypopigmented mycosis fungoides: a 48-case retrospective series. *Australas J Dermatol*. 2021;62:e419–e20. doi:10.1111/ajd.13565
14. De Marchi SU, Stinco G, Errichetti E, et al. The influence of the coexpression of CD4 and CD8 in cutaneous lesions on prognosis of mycosis fungoides: a preliminary study. *J Skin Cancer*. 2014;2014:624143. doi:10.1155/2014/624143
15. Jaque A, Mereniuk A, Walsh S, et al. Influence of the phenotype on mycosis fungoides prognosis, a retrospective cohort study of 160 patients. *Int J Dermatol*. 2019;58:933–939. doi:10.1111/ijd.14391

**Clinical, Cosmetic and Investigational Dermatology****Dovepress****Publish your work in this journal**

Clinical, Cosmetic and Investigational Dermatology is an international, peer-reviewed, open access, online journal that focuses on the latest clinical and experimental research in all aspects of skin disease and cosmetic interventions. This journal is indexed on CAS. The manuscript management system is completely online and includes a very quick and fair peer-review system, which is all easy to use. Visit <http://www.dovepress.com/testimonials.php> to read real quotes from published authors.

Submit your manuscript here: <https://www.dovepress.com/clinical-cosmetic-and-investigational-dermatology-journal>