

# Successful Treatment of Metastatic Gallbladder Carcinoma with PD-L1 Expression by the Combination of PD-1 Inhibitor Plus Bevacizumab with Chemotherapy: A Case Report

Lihong Guo\*, Jie Zhang\*, Xueqin Liu, Haocong Liu, Yamin Zhang, Jinpeng Liu

Department of Oncology, Xi 'an International Medical Center Hospital, Xi 'an, Shaanxi Province, People's Republic of China

\*These authors contributed equally to this work

Correspondence: Jinpeng Liu, Tel +8613772079179, Email lekai0822@163.com

**Abstract:** Gallbladder cancer (GBC) is the most common type of biliary tract cancer. The GBC is often diagnosed at an advanced stage, which limits surgical intervention due to its aggressive nature, and as a consequence of its insensitivity to chemotherapy, more effective treatments are required. In GBC, the efficacy of chemotherapy combined with anti-PD-L1/VEGF inhibition remains to be clarified. The present case report describes successful treatment by toripalimab in combination with bevacizumab and gemcitabine in a patient with metastatic GBC and PD-L1 combined positive score (CPS) =30. After six courses of therapy, a partial response was observed in the patient's clinical condition. So far, her PFS has exceeded 15 months. To the best of our knowledge, there was no other case where toripalimab plus bevacizumab were used in combination with gemcitabine as an effective treatment strategy for GBC. The remarkable response is likely to be related to the positive expression of PD-L1. Further, VEGF inhibition in combination with chemotherapy may result in improved clinical outcomes due to increased antitumor immunity. Chemotherapy regimens combined with anti-PD-L1/VEGF inhibition are promising therapies for GBC. Further well-designed prospective clinical trials are needed in order to confirm the efficacy and safety of the three-drug regimen.

**Keywords:** gall bladder cancer, GBC, PD-1 inhibitor, toripalimab, bevacizumab, chemotherapy

## Introduction

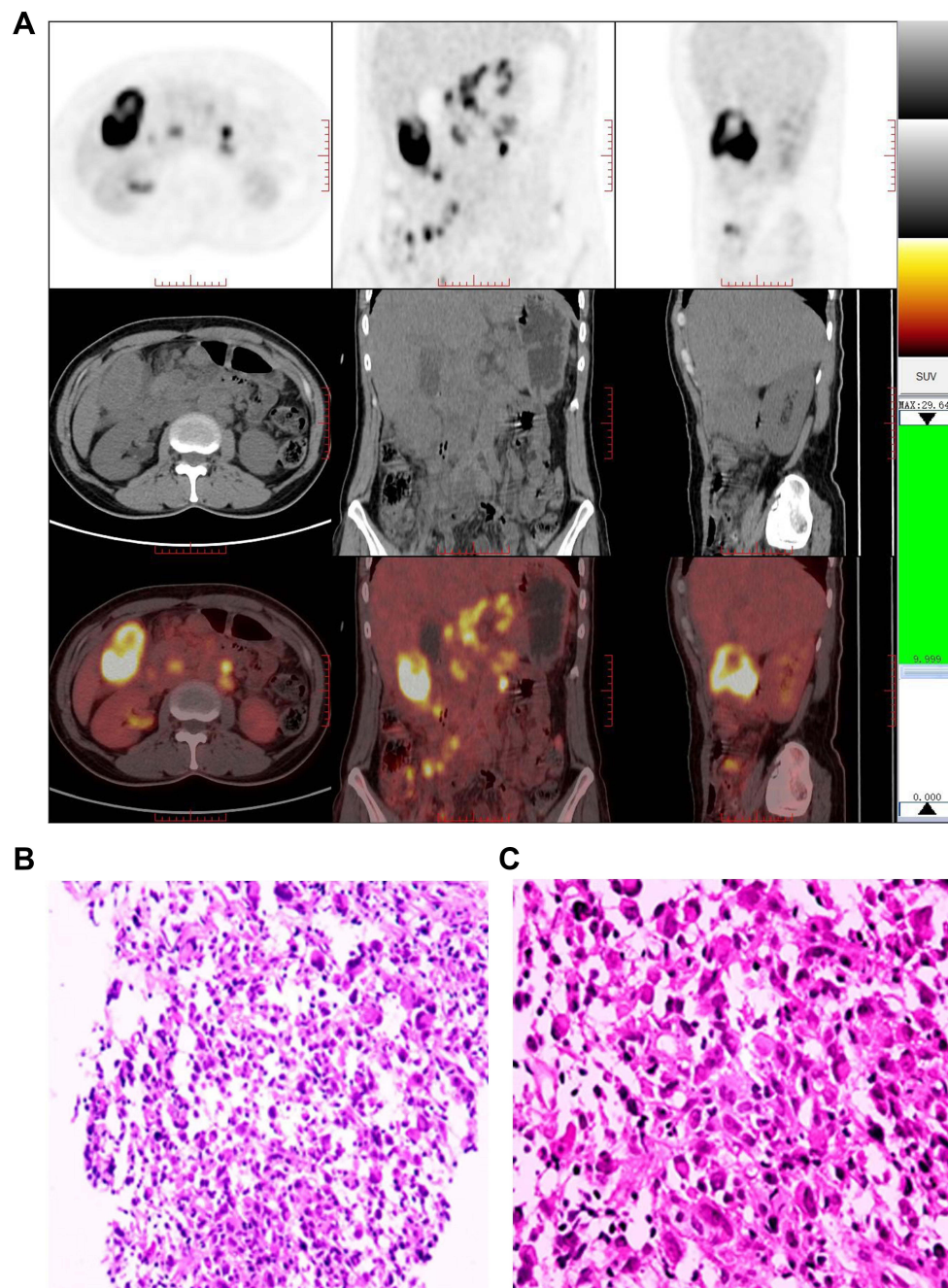
It has been reported that gallbladder cancer is the most common pathological type of biliary tract cancer (BTC), accounting for 1.23% of newly diagnosed cancers and 1.45% of reported deaths of all cancers in China.<sup>1</sup> Gallbladder cancer (GBC) is difficult to find in the early stages. In most cases, GBC is diagnosed following a pathologic examination at an advanced stage. With local advance and metastasis, the median survival time is less than 1 year. In spite of its rarity, GBC remains one of the leading causes of cancer-related death and holds a poor prognosis. The 3-year survival rate for patients with advanced GBC is approximately 1%.<sup>2,3</sup> Large-scale clinical trials have uncovered a limited effectiveness of the treatment options traditionally used to treat advanced GBCs, such as surgery, chemotherapy, and radiation therapy.<sup>4</sup> Based on the results of the ABC-02 trial, the combination of gemcitabine plus cisplatin remains the current standard of care in treatment-naïve patients.<sup>5</sup> However, the median survival of the doublet regimen was still only 11.7 months. Molecularly-targeted agents also have limited application in GBC. Inhibitor of mutations of IDH1 as well as fusions/rearrangement with fibroblast growth factor receptors (FGFR) and BRAFV600E mutations are potential targets, as they are found almost exclusively in intrahepatic cholangiocarcinomas.<sup>6-9</sup> With regards to angiogenesis, addition of bevacizumab (a monoclonal antibody against Vascular Endothelial Growth Factor) to capecitabine/gemcitabine failed to

improve outcome when compared with historical controls in a group of patients suffering from locally advanced or metastatic BTC.<sup>10</sup> As a result, more effective treatments for GBC are urgently needed.

Tumor immunotherapy, especially immune checkpoint inhibitors (ICIs), is an emerging field of tumor therapy. The use of ICI has received particular attention in curation for various types of cancers.<sup>11–15</sup> It prevents cancer from immune evading via activating the immune system and inducing antitumor responses.<sup>16</sup> Several monoclonal antibodies are available for ICI therapy, including those directed at Cytotoxic T-Lymphocyte Antigen 4 (CTLA-4), programmed cell death 1 (PD-1) and programmed death ligand-1 (PD-L1).<sup>17</sup> Although ICIs have revolutionized the treatment landscape of several malignancies, the promise of immunotherapy in BTC is currently under investigation.<sup>18,19</sup> The results of ICIs as monotherapy were disappointing in unselected BTC patients.<sup>20</sup> The objective response rate (ORR) of pembrolizumab in the BTC cohort was only 17% and 5.8% in the KEYNOTE-028 trial and KEYNOTE-158 trial, respectively.<sup>21</sup> In addition, available clinical data on ICIs in BTCs are mainly achieved from subanalyses of basket trials and small single-arm trials.<sup>21–23</sup> As in patients with other types of tumor, only a small proportion of patients respond to PD-1 or PD-L1 inhibitor monotherapy due to both primary and acquired resistance via various mechanisms within the tumor and the tumor microenvironment (TME).<sup>24</sup> It has been found that Vascular Endothelial Growth Factor (VEGF) is involved in the regulation of immunosuppressive BTC TME, thereby the study for the efficacy of anti-VEGF therapy in conjunction with PD-1/PD-L1 inhibitors in this clinical condition is warranted.<sup>25,26</sup> Cytotoxic chemotherapies, such as gemcitabine, can also increase antitumor immunity.<sup>27</sup> Anti-VEGF and chemotherapy complement each other and jointly strengthen antitumor immunity of PD-1 inhibitors. Therefore, combined inhibition of PD-L1 and VEGF along with the immunomodulating effects of gemcitabine may produce an immune-friendly TME in BTC, which leads to additional clinical benefits. Here, we report a case of metastatic GBC that was treated with a combination of an anti-PD1 monoclonal antibody with antiangiogenic agent and gemcitabine chemotherapy, and partial remission (PR) was achieved after six courses of treatment, with a mild adverse effect. At present, the patient is currently on maintenance therapy (bevacizumab plus PD-1 inhibitor) and her condition is quite stable. This case encouraged us to consider the three-drug combination as a promising treatment of advanced GBC.

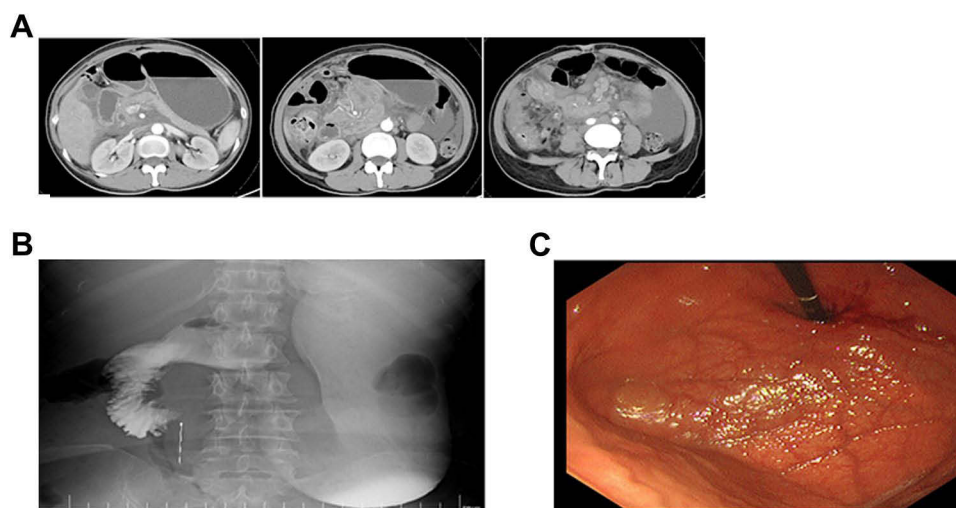
## Case Presentation

In August 2020, a 47-year-old female patient complaining of pain in the abdomen and back was admitted to Xi'an International Medical Center Hospital. She had a 20-year history of cholecystitis and cholecystolithiasis but had never sought treatment since she was asymptomatic. There was no cancer history or pathogenic germline mutation in her family. The positron emission tomography/computed tomography (PET/CT) examination revealed a gallbladder malignant tumor with lymph node metastasis in the left supraclavicular fossa, hepatic hilum, hepato-gastric space, retro-peritoneum, abdominal cavity, and right pelvic cavity (Figure 1A). The histopathology of cystic mass biopsy guided by ultrasound showed a gallbladder adenocarcinoma with metastases in multiple lymph nodes at stage IVB (cT3N2M1) (Figure 1B). There was no surgical chance for the patient. However, the immunohistochemistry (IHC) indicated that the PD-L1 expression of the tumor was positive (TPS 30%) (Figure 1C). In light of the examinations presented above, the patient received PD-1 inhibitor toripalimab combined with gemcitabine and cisplatin as therapy on September 11, 2020. In the following 2 months, the patient did not receive the next course of anti-tumor treatment on schedule and took some biological agents (details unknown) by herself. On November 27, 2020, the patient revisited our hospital due to aggravated low back pain. Her accompanying symptoms were abdominal distension, abdominal pain, nausea, vomiting, and flatulence. According to the Eastern Cooperative Oncology Group (ECOG), the patient's performance status (PS) was 3. Physical examination revealed multiple hard masses in the abdomen, which were partially confluent and fixed. The tumor biomarkers CEA and CA19-9 were normal, however, CA125 was elevated to 182 U/mL (normal range, <35 U/mL). Computed tomography (CT) revealed that the gallbladder tumor was larger than before and had multiple peritoneal, intra-abdominal, retroperitoneal, and mesenteric lymph node metastases, suggesting progression of the disease (Figure 2A). Upper gastrointestinal radiography showed obstruction at the origin of the horizontal part of the duodenum (Figure 2B). Electronic gastroduodenoscopy showed stenosis of the horizontal transition of the duodenum (Figure 2C). Combined with the patient's symptoms and examinations, we considered that the tumor had compressed the duodenum leading to duodenal obstruction. On December 15, 2020, the patient underwent exploratory laparotomy and jejunostomy



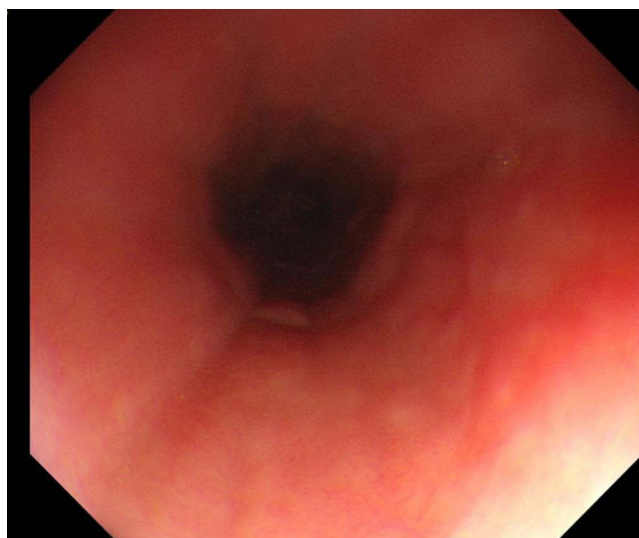
**Figure 1** PET/CT images or pathology of primary and metastatic tumor. **(A)** PET/CT showing a gallbladder malignant tumor with multiple lymph node metastases. **(B)** The histopathology of gallbladder mass biopsy indicating gallbladder adenocarcinoma. **(C)** The result of IHC showing a positive expression of PD-L1.

feeding tube implantation in the Department of Gastroenterology of our hospital. After postoperative symptomatic and supportive treatment such as anti-infection and nutrition, the general condition was significantly improved, with a PS of 2 points. For the purpose of identifying an effective treatment regimen, the tumor sample was subject to next-generation sequencing (NGS) analysis using a 599-gene panel supplied by Guangzhou Jinyu Medical Laboratory Group Company Limited. According to NGS results, the tumor mutation burden (TMB) was 9.3 mutations per megabase, and the microsatellite status of the tumor was stable. Genetic mutations were seen in *ATM*, *CCND1*, *CARD11*, *CDKN2A*, *CIC*, *CTNNB1*, *KDM6A*, *KDR*, *LRP1B*, *NOTCH3*, *RICTOR*, *SLX4*, and *TSC2*. There are no currently recommended targeted drugs for gene mutations. From January 7, 2021, the patient began to receive toripalimab (240 mg d1, q3w)



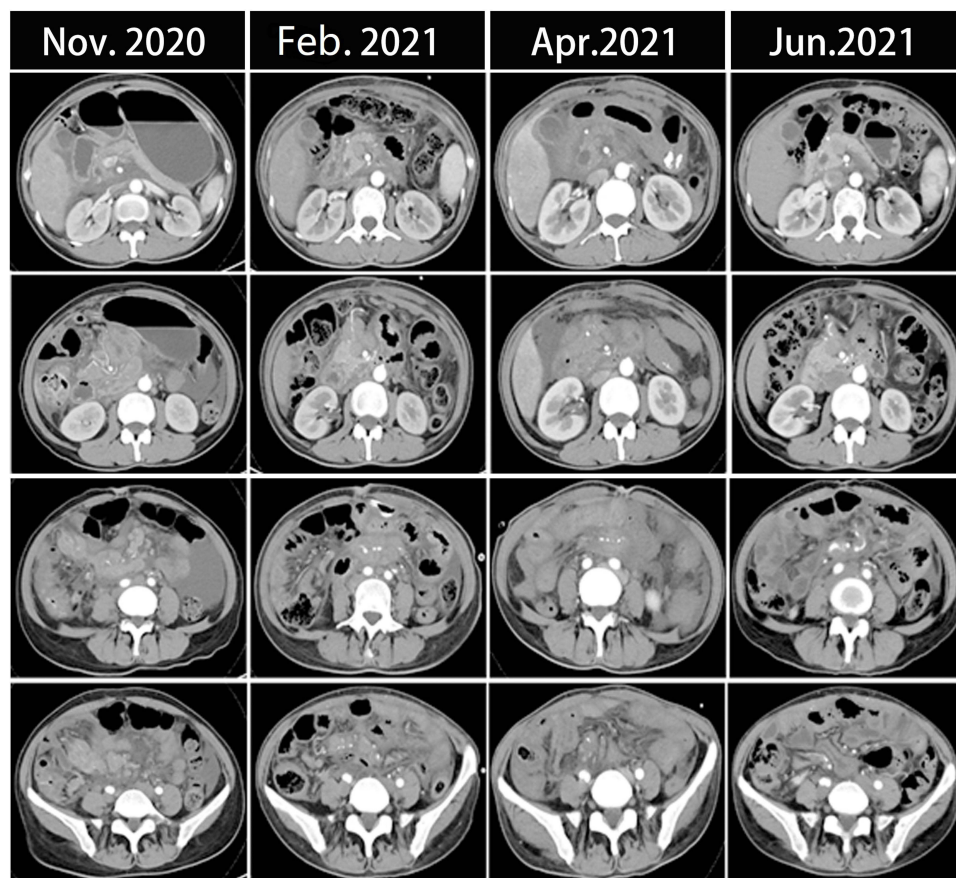
**Figure 2** Radiological imaging studies and electronic gastroduodenoscopy showing progression of disease. **(A)** CT scan revealed that the gallbladder tumor lesion was larger than before and more lymph node metastases. **(B)** Upper gastrointestinal radiography showed obstruction at the origin of the horizontal part of the duodenum. **(C)** Electronic gastroduodenoscopy showed stenosis of the horizontal transition of the duodenum.

combined with gemcitabine (1 g d1, 8, q3w) and VEGF/VEGFR inhibitor bevacizumab (300 mg, q3w). After a complete course, the patient felt better, and repeat gastroscopy showed no significant stenosis in the descending part of the duodenum (**Figure 3**). Surprisingly, after two courses, CT on February 19, 2021 showed a significant shrinkage of primary lesions and metastatic lymph nodes (**Figure 4**). Six courses later, we delightfully noticed that the patient's gall bladder lesions were reduced further, and abdominal lymph nodes were significantly reduced and decreased (**Figure 4**). The lesion was assessed as partial response (PR) based on an abdominal CT scan. Thereafter, the patient received maintenance therapy with toripalimab in combination with bevacizumab and underwent CT examinations regularly. During the maintenance therapy, the general conditions of the patient were improved, with an ECOG performance status of 0. So far, the patient has received nine cycles of maintenance therapy. Recent imaging was performed on December 31, 2021 (**Figure 5**) and tumor lesions were stable. **Figure 6** shows the process of development and treatment

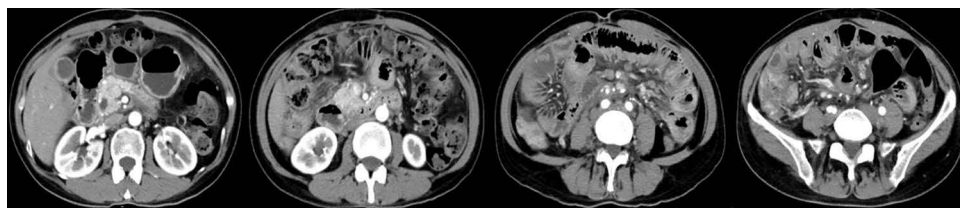


**Figure 3** Electronic gastroduodenoscopy showing no significant stenosis in the duodenum.

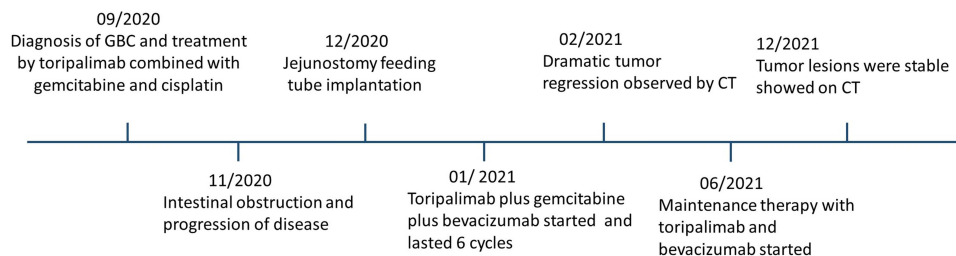




**Figure 4** CT scans show the therapeutic response of patients following a series of treatment.



**Figure 5** CT scan shows the tumor in gall bladder and metastatic lymph nodes on December 31, 2021.



**Figure 6** The timeline of the process of development and treatment of the patient.

of the disease. This patient is still alive at the time of writing, with a Progression-Free Survival (PFS) of over 15 months, and no significant adverse events have been observed. The patient expressed great expectations for this emerging therapy and an optimistic outlook regarding the future.

## Discussion and Conclusions

In this case report, we described a unique patient with metastatic GBC who was treated with an ICI (toripalimab) in combination with an antiangiogenic drug (bevacizumab) and single-agent chemotherapy (gemcitabine) and had a surprising partial response to the therapy. Toripalimab is a selective, recombinant, humanized monoclonal antibody against PD-1 developed by Shanghai Junshi Bioscience Co., Ltd. Toripalimab binds to PD-1 and blocks the interaction with its ligands. Considering the poor general condition of the patients, we chose gemcitabine single-agent chemotherapy. VEGF-A-targeting monoclonal antibody bevacizumab, the first available anti-angiogenic therapy, has shown efficacy in the treatment of metastatic colorectal cancer, breast cancer, non-small-cell lung cancer, glioblastoma, renal cell carcinoma, ovarian cancer, and cervical cancer. To the best of our knowledge, this is the first case presenting a significant response in an advanced GBC patient with immunotherapy combined with bevacizumab plus chemotherapy all over the world.

We reckoned that there were some facts which contribute to such a good outcome. First, the patient bore a positive PD-L1 expression (30%). PD-L1 expression has been considered as an immunotherapy biomarker in NSCLC, hepatocellular carcinoma, head and neck squamous cell carcinoma, and many other solid tumors, and the expression level was associated with efficacy.<sup>28</sup> Whether PD-L1 expression is a biomarker for BTC immunotherapy is still uncertain. In our case, the patient obtained a significant benefit from toripalimab treatment, which might indicate that PD-L1 expression could be a potential biomarker in GBC immunotherapy. Secondly, it is presumably because tumor cells damaged by chemotherapy could release antigens that could serve as adaptive immune response targets and enhance immune response. Immunotherapy combined with chemotherapy has been investigated in many types of cancers and has shown promising antitumor efficacy.<sup>29</sup> In this case, we combined gemcitabine monotherapy on GBC, which may augment the immunogenicity of the tumor and enhanced immunotherapy response. Thirdly, this synergetic effect between bevacizumab and ICI might also contribute to the significant response to toripalimab in this patient. We now know that VEGF not only plays a major role in controlling blood vessel formation, but also modulates tumor-induced immunosuppression.<sup>26</sup> VEGF suppresses the immune system by decreasing dendritic cell maturation and function, impairing CD8<sup>+</sup> T-cell infiltration and functioning, inducing inhibitory immunity checkpoints, and accumulating immunosuppressive cells such as myeloid-derived suppressor cells (MDSC), regulatory T cells (Treg), and tumor-associated macrophages (TAM).<sup>30,31</sup> Antiangiogenic drugs have been shown to reverse VEGF-induced immunosuppression and enhance the activity of PD-1 and PD-L1 inhibitors in a number of preclinical and clinical studies.<sup>26</sup> In clinical trials, combining of PD-1 or PD-L1 inhibitors, anti-VEGF agents have proved superior to standard treatments for non-squamous non-small cell lung cancer, renal-cell carcinoma, and hepatocellular carcinoma.<sup>32–35</sup> It is also demonstrated that maintenance therapy with bevacizumab combined with toripalimab achieved long-term stability in the present case.

In conclusion, the present case showed that the combination of ICI and antiangiogenic drug along with chemotherapy held potential to be a novel treatment for metastatic GBC. However, immunotherapy should not be considered a standard of care in all comers, due to the limited efficacy in unselected population. There is no effective way of evaluating in advance the effectiveness of immunotherapy. Multiple biomarkers, including TMB, MSI, and PD-L1, can be used to assess the effectiveness.<sup>36</sup> Unfortunately, the available data on the predictors of the response to ICIs in GBC are conflicting, and no single biomarker may select patients likely to benefit from this therapeutic approach.<sup>36</sup> As previously discussed, immune classification of the TME from tumor biopsies may help distinguish immunotherapy-responsive from resistant patient subgroups, but will need to be confirmed in prospective studies. GBC responds to combination therapy in an extremely complicated way from a pathological and physiological standpoint. Probably combination of multiple biomarkers is feasible to screen those who may benefit from ICIs. In the next 5 years, ICIs are likely to be approved for untreated, advanced disease, in combination with chemotherapy and antiangiogenic therapy. This should lead to more studies on the use of ICI-based treatment for earlier stages of GBC including neoadjuvant therapy for tumor downstaging, particularly for unresectable disease and in combination with locoregional therapies to increase their efficacy. ICIs will provide a promising treatment strategy to improve the survival benefit of GBC patients. Combining with antiangiogenic agents, chemotherapy, radiation therapy or targeted therapy will improve response rates of immunotherapy.

## Ethical Statement

This study was approved by the Ethics Committee of Xi'an International Medical Center Hospital.

## Patient Consent for Publication

Written informed consent was obtained from the patient for publication of this case report. She gave her consent for the publication of identifiable details, which can include photograph(s) and/or videos and/or case history and/or details within the text ("Material") to be published in the journal and article.

## Acknowledgments

There was no funding for this paper. Lihong Guo and Jie Zhang are co-first authors for this study.

## Disclosure

All authors declare no potential conflicts of interest in this work.

## References

- Chen W, Zheng R, Baade PD, et al. Cancer statistics in China, 2015. *CA Cancer J Clin*. 2016;66(2):115–132. doi:10.3322/caac.21338
- Lamarca A, Ross P, Wasan HS, et al. Advanced intrahepatic cholangiocarcinoma: post Hoc analysis of the ABC-01, -02, and -03 Clinical Trials. *J Natl Cancer Inst*. 2020;112(2):200–210. doi:10.1093/jnci/djz071
- Zhu X, Zhang X, Hu X, et al. Survival analysis of patients with primary gallbladder cancer from 2010 to 2015: a retrospective study based on SEER data. *Medicine*. 2020;99(40):e22292. doi:10.1097/md.00000000000022292
- Azizi AA, Lamarca A, Valle JW. Systemic therapy of gallbladder cancer: review of first line, maintenance, neoadjuvant and second line therapy specific to gallbladder cancer. *Chin Clin Oncol*. 2019;8(4):43. doi:10.21037/cco.2019.07.05
- Valle J, Wasan H, Palmer DH, et al. Cisplatin plus gemcitabine versus gemcitabine for biliary tract cancer. *N Engl J Med*. 2010;362(14):1273–1281. doi:10.1056/NEJMoa0908721
- Abou-Alfa GK, Macarulla T, Javle MM, et al. Ivosidenib in IDH1-mutant, chemotherapy-refractory cholangiocarcinoma (ClarIDHy): a multicentre, randomised, double-blind, placebo-controlled, Phase 3 study. *Lancet Oncol*. 2020;21(6):796–807. doi:10.1016/s1470-2045(20)30157-1
- Abou-Alfa GK, Sahai V, Hollebecque A, et al. Pemigatinib for previously treated, locally advanced or metastatic cholangiocarcinoma: a multicentre, open-label, Phase 2 study. *Lancet Oncol*. 2020;21(5):671–684. doi:10.1016/s1470-2045(20)30109-1
- Lamarca A, Barriuso J, McNamara MG, Valle JW. Molecular targeted therapies: ready for "prime time" in biliary tract cancer. *J Hepatol*. 2020;73(1):170–185. doi:10.1016/j.jhep.2020.03.007
- Subbiah V, Lassen U, Élez E, et al. Dabrafenib plus trametinib in patients with BRAF (V600E)-mutated biliary tract cancer (ROAR): a phase 2, open-label, single-arm, multicentre basket trial. *Lancet Oncol*. 2020;21(9):1234–1243. doi:10.1016/s1470-2045(20)30321-1
- Iyer RV, Pokuri VK, Groman A, et al. A multicenter Phase II study of gemcitabine, capecitabine, and bevacizumab for locally advanced or metastatic biliary tract cancer. *Am J Clin Oncol*. 2018;41(7):649–655. doi:10.1097/jco.0000000000000347
- Mansfield AS, Kaźarnowicz A, Karaseva N, et al. Safety and patient-reported outcomes of atezolizumab, carboplatin, and etoposide in extensive-stage small-cell lung cancer (IMpower133): a randomized phase I/III trial. *Ann Oncol*. 2020;31(2):310–317. doi:10.1016/j.annonc.2019.10.021
- Gandhi L, Rodriguez-Abreu D, Gadgeel S, et al. Pembrolizumab plus chemotherapy in metastatic non-small-cell lung cancer. *N Engl J Med*. 2018;378(22):2078–2092. doi:10.1056/NEJMoa1801005
- Burtneß B, Harrington KJ, Greil R, et al. Pembrolizumab alone or with chemotherapy versus cetuximab with chemotherapy for recurrent or metastatic squamous cell carcinoma of the head and neck (KEYNOTE-048): a randomised, open-label, Phase 3 study. *Lancet*. 2019;394(10212):1915–1928. doi:10.1016/s0140-6736(19)32591-7
- André T, Shiu KK, Kim TW, et al. Pembrolizumab in microsatellite-instability-high advanced colorectal cancer. *N Engl J Med*. 2020;383(23):2207–2218. doi:10.1056/NEJMoa2017699
- Janjigian YY, Shitara K, Moehler M, et al. First-line nivolumab plus chemotherapy versus chemotherapy alone for advanced gastric, gastro-oesophageal junction, and oesophageal adenocarcinoma (CheckMate 649): a randomised, open-label, Phase 3 trial. *Lancet*. 2021;398(10294):27–40. doi:10.1016/s0140-6736(21)00797-2
- Tang S, Ning Q, Yang L, Mo Z, Tang S. Mechanisms of immune escape in the cancer immune cycle. *Int Immunopharmacol*. 2020;86:106700. doi:10.1016/j.intimp.2020.106700
- Xin YJ, Hodge JP, Oliva C, Neftelinov ST, Hubbard-Lucey VM, Tang J. Trends in clinical development for PD-1/PD-L1 inhibitors. *Nat Rev Drug Discov*. 2020;19(3):163–164. doi:10.1038/d41573-019-00182-w
- Vogel A, Bathon M, Saborowski A. Immunotherapies in clinical development for biliary tract cancer. *Expert Opin Investig Drugs*. 2021;30(4):351–363. doi:10.1080/13543784.2021.1868437
- Rizzo A, Ricci AD, Brandi G. Recent advances of immunotherapy for biliary tract cancer. *Expert Rev Gastroenterol Hepatol*. 2021;15(5):527–536. doi:10.1080/17474124.2021.1853527
- Ricci AD, Rizzo A, Brandi G. Immunotherapy in biliary tract cancer: worthy of a second look. *Cancer Control*. 2020;27(3):1073274820948047. doi:10.1177/1073274820948047
- Piha-Paul SA, Oh DY, Ueno M, et al. Efficacy and safety of pembrolizumab for the treatment of advanced biliary cancer: results from the KEYNOTE-158 and KEYNOTE-028 studies. *Int J Cancer*. 2020;147(8):2190–2198. doi:10.1002/ijc.33013

22. Rizzo A, Ricci AD, Brandi G. Durvalumab: an investigational anti-PD-L1 antibody for the treatment of biliary tract cancer. *Expert Opin Investig Drugs*. 2021;30(4):343–350. doi:10.1080/13543784.2021.1897102
23. Oneda E, Abu Hilal M, Zaniboni A. Biliary tract cancer: current medical treatment strategies. *Cancers*. 2020;12(5):1237. doi:10.3390/cancers12051237
24. Murciano-Goroff YR, Warner AB, Wolchok JD. The future of cancer immunotherapy: microenvironment-targeting combinations. *Cell Res*. 2020;30(6):507–519. doi:10.1038/s41422-020-0337-2
25. Fukumura D, Kloepper J, Amoozgar Z, Duda DG, Jain RK. Enhancing cancer immunotherapy using antiangiogenics: opportunities and challenges. *Nat Rev Clin Oncol*. 2018;15(5):325–340. doi:10.1038/nrclinonc.2018.29
26. Hack SP, Zhu AX, Wang Y. Augmenting anticancer immunity through combined targeting of angiogenic and PD-1/PD-L1 pathways: challenges and opportunities. *Front Immunol*. 2020;11:598877. doi:10.3389/fimmu.2020.598877
27. Bailly C, Thuru X, Quesnel B. Combined cytotoxic chemotherapy and immunotherapy of cancer: modern times. *NAR cancer*. 2020;2(1):zcaa002. doi:10.1093/narcan/zcaa002
28. Teng F, Meng X, Kong L, Yu J. Progress and challenges of predictive biomarkers of anti PD-1/PD-L1 immunotherapy: a systematic review. *Cancer Lett*. 2018;414:166–173. doi:10.1016/j.canlet.2017.11.014
29. Kon E, Benhar I. Immune checkpoint inhibitor combinations: current efforts and important aspects for success. *Drug Resist Updates*. 2019;45:13–29. doi:10.1016/j.drug.2019.07.004
30. Pinter M, Jain RK, Duda DG. The current landscape of immune checkpoint blockade in hepatocellular carcinoma: a review. *JAMA Oncol*. 2021;7(1):113–123. doi:10.1001/jamaoncol.2020.3381
31. Chen DS, Hurwitz H. Combinations of bevacizumab with cancer immunotherapy. *Cancer j*. 2018;24(4):193–204. doi:10.1097/ppo.0000000000000327
32. Socinski MA, Jotte RM, Cappuzzo F, et al. Atezolizumab for first-line treatment of metastatic nonsquamous NSCLC. *N Engl J Med*. 2018;378(24):2288–2301. doi:10.1056/NEJMoa1716948
33. Rini BI, Plimack ER, Stus V, et al. Pembrolizumab plus Axitinib versus sunitinib for advanced renal-cell carcinoma. *N Engl J Med*. 2019;380(12):1116–1127. doi:10.1056/NEJMoa1816714
34. Finn RS, Qin S, Ikeda M, et al. Atezolizumab plus bevacizumab in unresectable hepatocellular carcinoma. *N Engl J Med*. 2020;382(20):1894–1905. doi:10.1056/NEJMoa1915745
35. Ren Z, Xu J, Bai Y, et al. Sintilimab plus a bevacizumab biosimilar (IBI305) versus sorafenib in unresectable hepatocellular carcinoma (ORIENT-32): a randomised, open-label, phase 2–3 study. *Lancet Oncol*. 2021;22(7):977–990. doi:10.1016/s1470-2045(21)00252-7
36. Rizzo A, Ricci AD, Brandi G. PD-L1, TMB, MSI, and other predictors of response to immune checkpoint inhibitors in biliary tract cancer. *Cancers*. 2021;13(3):558. doi:10.3390/cancers13030558

## OncoTargets and Therapy

Dovepress

### Publish your work in this journal

OncoTargets and Therapy is an international, peer-reviewed, open access journal focusing on the pathological basis of all cancers, potential targets for therapy and treatment protocols employed to improve the management of cancer patients. The journal also focuses on the impact of management programs and new therapeutic agents and protocols on patient perspectives such as quality of life, adherence and satisfaction. The manuscript management system is completely online and includes a very quick and fair peer-review system, which is all easy to use. Visit <http://www.dovepress.com/testimonials.php> to read real quotes from published authors.

Submit your manuscript here: <https://www.dovepress.com/oncotargets-and-therapy-journal>