

Analysis of the Effect of Wound-Edge Microgranular Skin Grafting in the Treatment of Various Small Wounds

Tiannan Chen, Yuesen Lin, Chengshuo Cui, Fangfang Zhang, Tingting Su, Kaiyu Guo, Jialin Hu

Department of Burn and Wound Repair, Yueqing City People's Hospital; Wenzhou Medical College Affiliated Yueqing Hospital, Wenzhou City, Zhejiang, 325600, People's Republic of China

Correspondence: Jialin Hu, Department of Burn and Wound Repair, Yueqing City People's Hospital; Wenzhou Medical College Affiliated Yueqing Hospital, No. 338, Qingyuan Road, Chengnan Street, Yueqing City, Wenzhou City, Zhejiang, 325600, People's Republic of China, Tel +86 15868777770, Fax +86 577-62061788, Email hujialin_ys@163.com

Objective: To explore the clinical effect of wound edge microgranular skin grafting in the treatment of various small wounds.

Methods: From September 2018 to September 2021, Yueqing people's Hospital of Wenzhou City, Zhejiang Province collected and recorded the data of 12 patients with chronic wounds and third degree burns. The method of skin grafting with particles at the edge of the wound was used to graft skin on the wound. Scar evaluation scale was used to evaluate the wound. The patients were followed up for 12 months. The preoperative and postoperative data, scar index and patient satisfaction after healing were recorded and statistically analyzed.

Results: All patients in this group were followed up for 3–12 months, and the results showed that SCAR Scale score decreased gradually over time, with patient satisfaction ranging from 80% to 96%. The patient gradually healed, scar hyperplasia gradually improved, functional activities gradually returned to normal, clinical effect is satisfactory.

Conclusion: Microparticle skin grafting at the edge of wound avoids skin grafting at different skin donor sites. It has the characteristics of simple anesthesia, small trauma and convenient operation. This method can be considered when treating patients with chronic wounds and burns who need skin grafting.

Keywords: wound-edge microgranular skin grafting, chronic wounds, burns, curative effect analysis

Introduction

In recent years, people have paid more and more attention to beauty, and the healing of various small wounds has attracted more and more attention.¹ If there is no intervention, only a simple dressing change may end up with a large scar on the affected area, which will affect the function, and at the same time, the infection may become worse or even difficult to heal. Such wounds routinely require surgery such as abdominal embedment, skin grafting or skin flap transfer to avoid aggravation of infection, heal the wound, and restore the function of the affected area. However, patients are generally unwilling to perform such operations, especially in patients with acute and chronic wounds or third-degree burns in various parts of the body. Burns and chronic wounds are independent risk factors affecting wound healing. For patients with burns or chronic wounds complicated with type 2 diabetes, the difficulty of wound healing is greatly increased. How to repair lower limb ulcer wounds in patients with burns or chronic wounds and diabetes has become a clinical challenge. However, because some patients with large-area burns have less autologous skin sources, post-operative wound repair is more difficult,² or because the physical conditions cannot tolerate anesthesia, when the wound condition is mature, under local anesthesia at the bedside, we directly take part of the wound edge skin (the thickness depends on the wound base conditions) and cut it into microgranular skin for grafting. At present, microgranular skin grafting technology is widely used in the repair of large-area burns, large-area skin and soft tissue defects, and the curative effect is definite.^{3–6} The treatment of wound edge microgranular skin grafting not only accelerates the wound healing, but also restores the color and texture of the original skin, and avoids other skin donor site operations. In this

study, we used wound edge microgranular skin grafting. In order to explore the clinical effects of wound edge microgranular skin grafting in the treatment of various small wounds, we treated a total of 12 patients and achieved good results. The report is as follows.

General Information

The data of 12 patients with chronic wounds or third-degree burns were collected. They were admitted to our hospital from September 2018 to September 2021, including 8 males and 4 females; aged 40–72 years old. The wounds of the patients all required skin grafting surgery. Among them, 9 cases had chronic wounds (They are mainly four types of traumatic ulcers, postoperative ulcer, diabetic ulcers and pressure ulcers.) and 3 cases had third-degree burns. Preoperative assessments all routinely required skin grafting. Because the patients and their family members refused to perform the conventional different area skin grafting with greater trauma, they chose local anesthesia to perform the wound edge microgranular skin grafting. The preoperative and postoperative data, scar index of the patients after healed and patient satisfaction were recorded. All patients gave informed consent to this study and signed informed consent. Patients with coagulation dysfunction, serious mental illness or consciousness disorder were excluded.

Treatment Methods

Preparation of Particle Skin

Preparation of particle skin: cut a circle of skin with a width of about 0.5–1.0 cm around the wound edge (select the thickness according to the wound condition, such as full-thickness particle skin for the full-thickness defect of a wound or if some dermis still exists, select the epidermis plus some dermis particles.) After the skin is removed, clean the skin by hand to remove fat, etc. After cleaning, cut the skin as evenly as possible into (0.5–1.0) mm × (0.5–1.0) mm particle skin with scissors, and soak it in 0.9% sodium chloride solution.

Treatment of Donor Area

Wound-Edge Microgranular Skin Grafting

The treatment methods are as follows.

(1) Wound conditions for preparing for debridement dressing, for patients with physical conditions, can undertake VSD negative pressure drainage, improve time to speed up the wound, if you do not support to general anaesthesia patients physical condition, debridement dressing is, every time debridement, need to clean up the wound infection, oven removes wound fibre, in the coverage of antimicrobial agents, keep moist wound environment, Accelerate the formation of wound granulation tissue. Once the preoperative preparation was completed, there was no necrotic tissue, secretion decreased, and granulation tissue appeared fresh on the wound surface.

(2) All operations were performed in the outpatient operating room. Routine wound disinfection was performed, and the wound was expanded and debrided again under local anaesthesia to clean the wound thoroughly.

Skin grafting operation: after thorough debridement and skin removal, there was some bleeding from the wound, so it was necessary to actively stop the bleeding to avoid postoperative blood stasis resulting in skin particles floating on the wound and affecting the skin graft. The particle skin was dispersed into the wound surface and evenly dispersed between the particles.

(3) After the operation, the wound was covered with silver ion gauze or ordinary Vaseline gauze for about four to seven days and covered with a cotton pad to keep the skin attached to the wound. The patient was advised to avoid strenuous activities. The dressing was changed regularly in the clinic after surgery.

Effect Evaluation

We followed up with the patients for 3–12 months after the surgery, and used the Scar Cosmesis Assessment and Rating (SCAR) Scale and Vancouver Scar Scale (VSS) to measure the outcome.⁷ The SCAR scale consists of six questions recorded by the observer and two simple questions answered by the patient with a SCAR score of 0–15 points. The VSS scale includes colour, blood circulation, softness and thickness, and is rated on a scale of 0–15 points. The higher the

score, the more severe the scar. The same person evaluated the SCAR and VSS scales. The visual similarity scale evaluated the patient's overall satisfaction with their scar (0 = most satisfied, 10 = least satisfied).

Results

Therapeutic Effect

Patients in this group were followed up for 3–12 months and scored every 3 months. The preoperative SCAR Scale score is 5–10. The results of 12 postoperative follow-up showed that, over time, the patient's surgical wound was gradually closed and complete, the quality of the wound was gradually improved, the skin function was gradually restored, the scar on the wound was slightly increased, the chronic refractory wound healed well, and the patient satisfaction was between 80% and 96%, with satisfactory results. See [Table 1](#) for details.

Typical Cases

Typical Case I

The patient, a 56-year-old female with no history of diabetes, had purulent secretions at the incision due to breast cancer surgery ([Figure 1A](#)). The wound surface was clean after microparticle skin grafting at the wound edge ([Figure 1B](#)). Two-to-three weeks later, granulation filling could be seen on the wound surface, and there were still some skin defects ([Figure 1C](#)). A second microskin graft was performed ([Figure 1D](#)), and two-to-three weeks postoperative, the patient's wound was flat with no obvious scar hyperplasia, and complete healing was visible ([Figure 1E and F](#)).

Typical Case II

The patient, a 57-year-old female with no history of diabetes, had a chronic wound on the back of the forefoot for more than half a year, resulting in a complete skin defect of 2.5 cm in size ([Figure 2A](#)). After periodic debridement and dressing change ([Figure 2B](#)), microparticle skin grafting was performed on the wound edge ([Figure 2C](#)). Within two-to-three weeks, the patient's wound was flat with no obvious scar hyperplasia, and complete healing was observed ([Figure 2D](#)).

Typical Case III

The patient was an 82-year-old male with a history of type 2 diabetes, hypertension, cerebral infarction, and long-term bed rest. He had a chronic wound near the lateral malleolus of the lower leg that lasted for more than one year and resulted in infection. The skin defects were 5.6 and 4.9 cm, respectively ([Figure 3A](#)). After periodic debridement and dressing change ([Figure 3B and C](#)), the wound was cleaned, then the wound margin microskin graft was performed and the proximal suture wound was sutured ([Figure 3E](#)). Within about two-to-three weeks, the patient's wound was flat, no obvious scar hyperplasia was observed, and the patient began to heal ([Figure 3D and F](#)).

Table 1 Scar Score of 12 Patients

Patient Number	Preoperative	After 3 Months	After 6 Months	After 9 Months	After 12 Months	Satisfaction (%)
1	10	9	8	6	6	85
2	8	7	6	5	5	80
3	7	5	3	3	3	96
4	7	6	5	4	3	90
5	9	8	7	6	6	80
6	8	7	6	5	4	86
7	6	5	4	3	3	80
8	7	6	5	3	3	90
9	8	6	5	4	4	85
10	10	9	7	—	—	—
11	5	4	3	3	2	90
12	7	6	4	4	4	92

Notes: No. 1, 2 and 10 are burn patients, the rest are chronic trauma patients, and No. 10 patient was lost to follow-up.

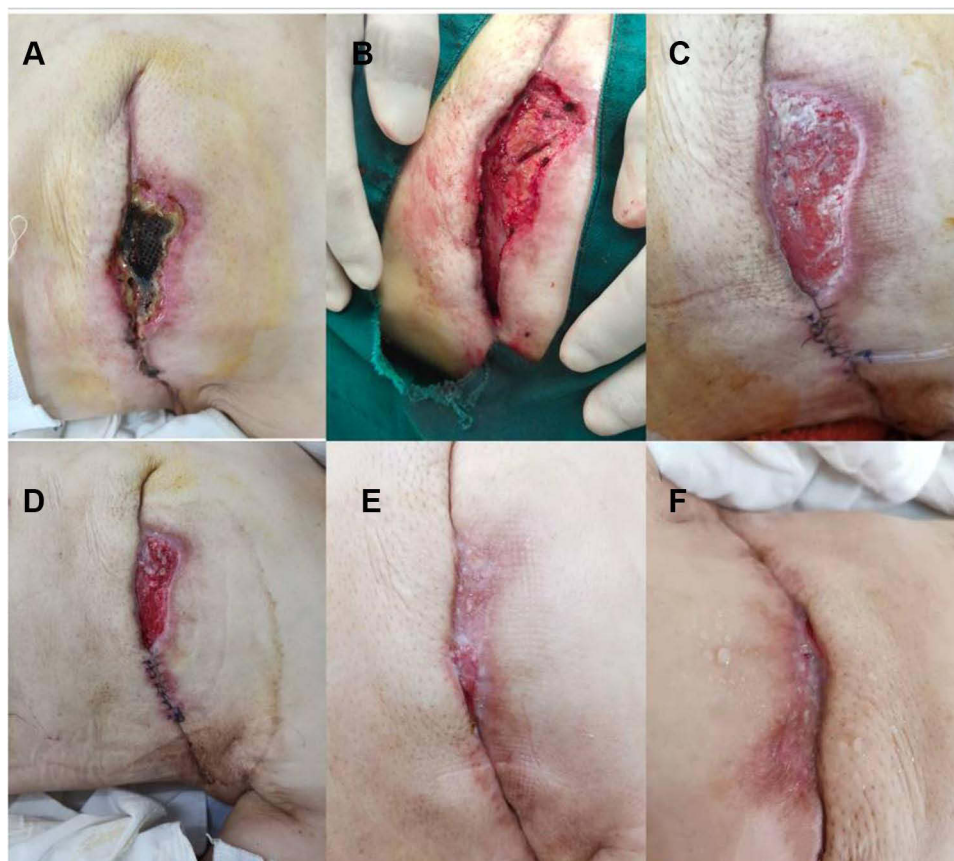


Figure 1 Typical case I. (A) On physical examination, there was purulent secretion at the incision, and the wound skin was completely defective. (B) The suturable part was sutured. (C) Larger scar tissue might be formed in this area. (D) It was recommended to perform the second microgranular skin grafting surgery. (E and F) The wound is completely healed.

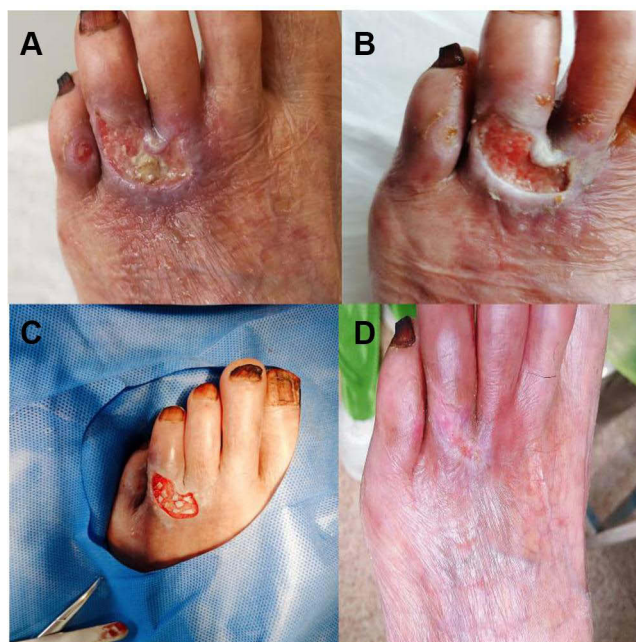


Figure 2 Typical case II. (A) Chronic wound on the back of forefoot for over six months. (B) Debridement and dressing change regularly. (C) Basically clean wound. (D) The wound is completely healed.

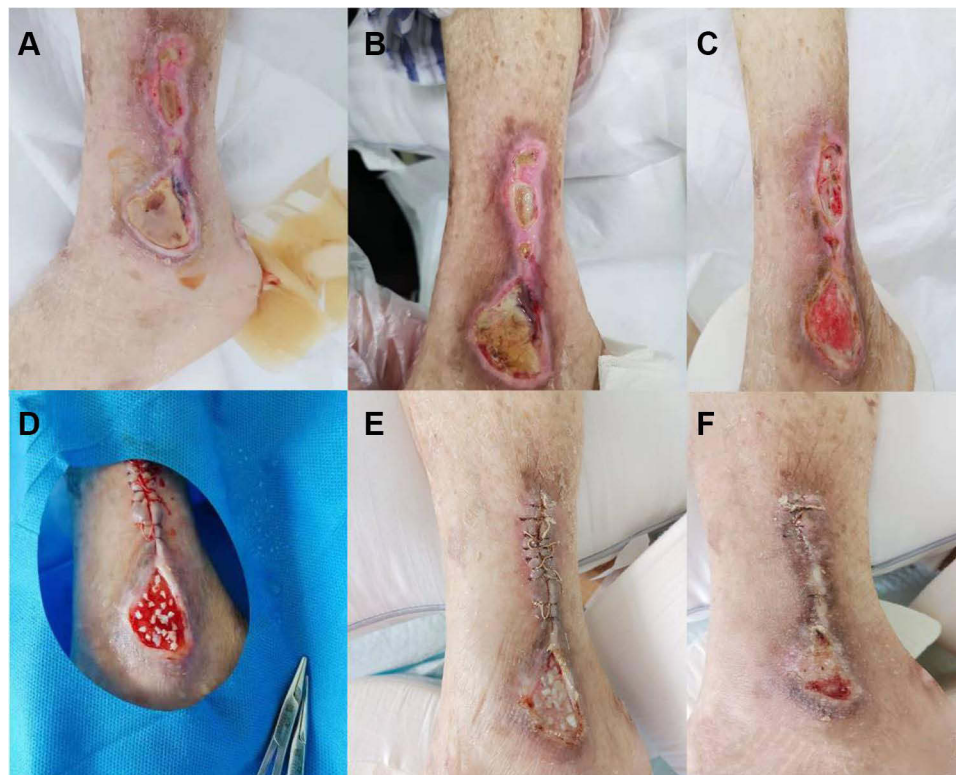


Figure 3 Typical case III. (A) Chronic wound near the lateral malleolus of the lower leg. (B and C) Debridement and dressing change regularly. (D) No obvious scar hyperplasia was found and the wound healed basically. (E) After the wound was basically cleaned, the wound that could be sutured proximal was sutured. (F) No obvious scar hyperplasia was found and the wound healed basically.

Discussion

With current developments in medical technology, treatment options for large-scale wounds mainly include microgranular skin transplantation, Meek skin grafting, allogeneic skin perforation and autologous skin transplantation, mesh autologous skin transplantation, autologous stamp skin transplantation, autologous particles combined with allogeneic large-scale skin transplantation,⁸ etc. Microgranular skin transplantation is widely used due to the large skin expansion ratio, which can maximise the use of limited skin sources to seal larger wounds.^{9–15} The development of various dermal substitutes has been particularly quick and has solved the problem for many patients with large skin defects that need skin grafting but have difficulty obtaining skin sources.¹⁶ Patients with large wounds have been treated to a certain extent, but for some patients with a small wound area, if they underwent previous skin grafting, there could be damage to the donor area, and the cost will be greatly increased. Moreover, simply changing the dressing does not accelerate wound healing. On the contrary, there is the aggravation of infection and the formation of a scar, affecting function and bringing a greater burden to patients and their families.

Microgranular skin transplantation has been used in China for 33 years. Microgranular skin grafting technology is a special skin grafting technology that cuts the skin into fine particles to increase its expansion and proliferation ability. The microgranular skin tissue has five dermal surfaces and one epidermal surface. After transplantation into the wound, blood vessels grow in and move around during the plasma nutrition period and gradually stabilise as the nerve fibres grow.^{17,18} We further studied microgranular skin grafting and performed related operations. On this basis, we proposed the idea of this kind of operation, whether it is possible to use only the skin on the edge of the wound to perform a type of microgranular skin grafting surgery, and whether such an operation can bring better results to these patients. Skin wounds will secrete growth factors,^{19,20} so the normal skin on the edge of the wound will also secrete growth factors. We conducted an operation with microgranular skin grafting. The skin island formed by the microgranular skin accelerated the wound healing. At the same time, we found more exciting news: the wound

recovered quite smoothly, and scar hyperplasia was very small. This surgical method has some advantages: reduced trauma, lower surgical operation requirements, and a stable curative effect. Our treatment found that the microgranular skin expands and the local dermal tissue expands so that the wound surface can be restored to a certain degree of elasticity, with a better healing effect. At present, the results of the operation are good, and there are no obvious complications. Maybe it is because we strictly pay attention to the aseptic operation every time the dressing is changed, or it may be that the preoperative wound preparation is adequate. This study evaluated the wound edge particles repair skin transplantation in chronic wounds or the application effect of burn wounds, the results show that skin grafting to repair wounds particles are less for leather, high healing rate, and the characteristics of the small wound healing quality is good, avoid the taken from different parts of the skin, is a kind of suitable for application in chronic wounds or burns wound repair technology. It can be seen that this operation has a good effect on patients with such wounds, and at the same time it can alleviate the pain of the patient, save time and economic costs.

Microgranular skin grafting has been widely used in China,⁷ especially in solving the problem of insufficient skin donation areas for many large-scale deep burns. This is of great importance. While the development of microgranular skin grafting is slow, its potential is huge, and more research is needed. This article currently has only three cases and a small sample size. The number of cases will be expanded in the future, and controlled studies will be carried out. At the same time, relevant surgical treatment methods will be improved to achieve better clinical results.

Data Sharing Statement

The datasets used or analyzed during the current study are available from the corresponding author on reasonable request.

Ethics Approval and Consent to Participate

This study was conducted in accordance with the Declaration of Helsinki with patient informed consent and approved by the ethics committee of Yueqing City People's Hospital. All patients whose case details as described in this manuscript have provided specific informed consent for their case details and accompanying images to be published.

Author Contributions

All authors made a significant contribution to the work reported, whether that is in the conception, study design, execution, acquisition of data, analysis and interpretation, or in all these areas; took part in drafting, revising or critically reviewing the article; gave final approval of the version to be published; have agreed on the journal to which the article has been submitted; and agree to be accountable for all aspects of the work.

Funding

There is no funding to report.

Disclosure

All of the authors had no any personal, financial, commercial, or academic conflicts of interest separately.

References

1. Khan AA, Khan IM, Nguyen PP, et al. Skin graft techniques. *Clin Podiatr Med Surg*. 2020;37(4):821–835. doi:10.1016/j.cpm.2020.07.007
2. Kang K, Shao Y, Song GD. [Research status and prospect on autologous tissue-engineered skin as permanent graft]. *Zhonghua Shao Shang Za Zhi*. 2020;36(10):971–974. Chinese. doi:10.3760/cma.j.cn501120-20200204-00043
3. Li L, Chou HY, Fan PF, Wang K, Zhan W. Observation on the effect of platelet-rich plasma combined with autologous microgranular skin transplantation in promoting the healing of the donor area after skin grafting. *J Chin Pract Diagn Ther*. 2021;35(4):352–354.
4. Takagi S, Oyama T, Jimi S, Saparov A, Ohjimi H. A novel autologous micrografts technology in combination with Negative Pressure Wound Therapy (NPWT) for quick granulation tissue formation in chronic/refractory ulcer. *Healthcare*. 2020;8(4):513. doi:10.3390/healthcare8040513
5. Andreone A, de Hollander D. A case report on the effect of micrografting in the healing of chronic and complex burn wounds. *Int J Burns Trauma*. 2020;10(1):15.
6. Horie Y, Notoya S, Matsuda M, Trovato L. Use of autologous micrografting in the treatment of stretch marks. *Dermatol Ther*. 2020;33(2). doi:10.1111/dth.13217
7. Kantor J. Reliability and photographic equivalency of the Scar Cosmesis Assessment and Rating (SCAR) scale, an outcome measure for postoperative scars. *JAMA Dermatol*. 2017;153(1):55–60. doi:10.1001/jamadermatol.2016.3757

8. Wang DL, Ma XQ, Zhang XQ. The clinical effects of different skin grafting methods in repairing large-area burn wounds. *Chin Med Guide*. 2021;19(3):39–40.
9. Zhang ML, Wang CY, Chang ZD. [Microskin grafting in animal experiments and clinical practice]. *Zhonghua Wai Ke Za Zhi*. 1986;24(4):219–221, 253–254. Chinese.
10. Singh M, Nuutila K, Collins KC, Huang A. Evolution of skin grafting for treatment of burns: reverdin pinch grafting to Tanner mesh grafting and beyond. *Burns*. 2017;43(6):1149–1154. doi:10.1016/j.burns.2017.01.015
11. Ozthathil DK, Tay MW, Wolf SE, Branski LK, Narrative A. Review of the history of skin grafting in burn care. *Medicina*. 2021;57(4):380. doi:10.3390/medicina57040380
12. Oda T, Kato H, Nakamura M, Morita A. Analysis of biomonitoring data after full-thickness skin grafting. *J Dermatol*. 2021;48(7):1035–1043. doi:10.1111/1346-8138.15873
13. Pan BH, Sun Y, Tang T, Xiang Y, Zhu SH. Application of antigen-free pig peritoneum as a carrier of autologous microgranular skin transplantation in patients with extensive deep burns. *Chin J Burns*. 2020;36(9):861–864. doi:10.3760/cma.j.cn501120-20190725-00311
14. Zhang P, Yuan LL, Luo J, et al. Influencing factors and predictive value of skin graft survival after Meek skin grafting in severely burned patients. *Chin J Burns*. 2021;37(1):243–249. doi:10.3760/cma.j.cn501120-20201127-00503
15. Wang ZJ, Li HH, Ben C, Lu H, Zhu SH. Research progress in the application of microgranular skin grafting technology. *Chin J Burns*. 2021;37(1):93–96. doi:10.3760/cma.j.cn501120-20191223-00468
16. Lee OJ, Ju HW, Kim JH, et al. Development of artificial dermis using 3D electrospun silk fibroin nanofiber matrix. *J Biomed Nanotechnol*. 2014;10(7):1294–1303. doi:10.1166/jbn.2014.1818
17. Agarwal P, Tiwari S, Kukrele R, Sharma D. Microskin grafting: clinical study of its feasibility and results. *Eur J Plast Surg*. 2020;44:255–262.
18. Chen X, Qin FJ, Yu DN, Sun YH. The history, current situation and future of microgranular skin transplantation. *Chin J Inj Repair Wound Healing*. 2019;14(1):9–12.
19. Hambrick GW Jr, Lamberg SI, Bloomberg R. Observations on keratinization of human skin in vitro. *J Invest Dermatol*. 1966;47(6):541.
20. Bhora FY, Dunkin BJ, Batzri S, et al. Effect of growth factors on cell proliferation and epithelialization in human skin. *J Surg Res*. 1995;59(2):236–244. doi:10.1006/jsre.1995.1160

Clinical, Cosmetic and Investigational Dermatology

Dovepress

Publish your work in this journal

Clinical, Cosmetic and Investigational Dermatology is an international, peer-reviewed, open access, online journal that focuses on the latest clinical and experimental research in all aspects of skin disease and cosmetic interventions. This journal is indexed on CAS. The manuscript management system is completely online and includes a very quick and fair peer-review system, which is all easy to use. Visit <http://www.dovepress.com/testimonials.php> to read real quotes from published authors.

Submit your manuscript here: <https://www.dovepress.com/clinical-cosmetic-and-investigational-dermatology-journal>