

# Demodicosis Imitating Acne Vulgaris: A Case Report

Anon Paichitrojjana 

School of Anti-Aging and Regenerative Medicine, Mae Fah Luang University, Bangkok, 10110, Thailand

Correspondence: Anon Paichitrojjana, School of Anti-Aging and Regenerative Medicine, Mae Fah Luang University, 36/87-88 PS Tower 25Fl, Asoke Road, Sukumvit 21, Klong Toey Nua, Wattana, Bangkok, 10110, Thailand, Tel +66819343050, Email anonpaic@gmail.com

**Abstract:** Demodicosis is caused by *Demodex* mite infestation and can present with a variety of clinical manifestations, including pityriasis folliculorum type, rosacea-like type, folliculitis-like type and perioral dermatitis-like type. Therefore, this skin condition is often misdiagnosed or underdiagnosed. This report presents a 19-year-old woman with a history of pityriasis folliculorum type demodicosis and successful treatment with oral ivermectin. After one year of remission, the patient began to develop a dry, itchy rash on her face for one month before multiple small edematous papules and pustules gradually appeared on both cheeks. The patient was first diagnosed as acne vulgaris and treated with doxycycline for 2 weeks, but the clinical symptoms did not show any signs of improvement. After reassessment based on clinical presentation and laboratory examination that found multiple *Demodex* mites from pustules and rash on both cheeks, the patient was diagnosed with folliculitis-like type demodicosis. However, this patient still had a very good response to oral ivermectin and metronidazole gel, and all clinical symptoms disappeared within 4 weeks after treatment. This is a case report of demodicosis imitating acne vulgaris and the first report demonstrating a change in clinical manifestations of demodicosis from pityriasis folliculorum type to folliculitis-like type.

**Keywords:** *Demodex* mite, demodicosis, acne vulgaris, pityriasis folliculorum, folliculitis-like demodicosis

## Introduction

*Demodex* is a genus of mites that live in the pilosebaceous unit of mammals as a normal flora. In special circumstances, *Demodex* mite can cause multiple skin disorders grouped under the term demodicosis or demodicidosis, which has various clinical features based on the literature. For example, pityriasis folliculorum type manifests as erythematous patch with dry, sandpaper-like rough skin due to the increased scale within hair follicles.<sup>1,2</sup> Rosacea-like type consists of itchy, burning, erythematous skin with papulopustular lesions involving the face of patients, with or without pre-existing rosacea.<sup>3,4</sup> Folliculitis-like type is described as localized follicular pustules that mimic acne vulgaris or folliculitis.<sup>2,5</sup> Perioral dermatitis-like type has the appearance of papulopustular lesions involving the perioral area like perioral dermatitis.<sup>6</sup> This report describes a young woman who initially developed clinical symptoms of pityriasis folliculorum type demodicosis which turned into folliculitis-like type demodicosis, imitating acne vulgaris.

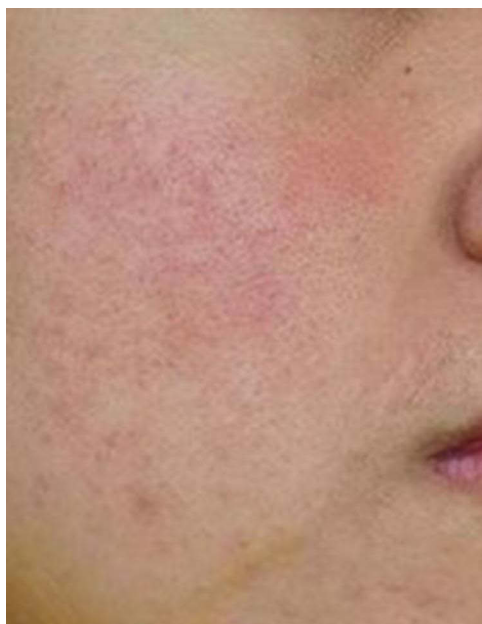## Case Report

A healthy 19-year-old woman presented with dry, itchy rash with multiple small edematous papules and pustules on both cheeks for four weeks. One year ago, this patient had a history of recurrent unexplained eczematous rash on her face that had a good response to topical 0.1% triamcinolone cream and relapsed immediately after treatment. Skin examination revealed dry erythematous patch, rough skin with “sandpaper-like” texture on her face. An abnormally high density of *Demodex* mites was detected with more than 5 *Demodex* mites/cm<sup>2</sup> from rash on her cheeks by standardized skin surface biopsy. Based on clinical symptoms and laboratory test, the patient was diagnosed with pityriasis folliculorum type demodicosis and treated with two doses of oral ivermectin (200 µg/kg per dose, 1 week apart) and topical 0.75% metronidazole gel for 4 weeks. After the treatment, all clinical symptoms disappeared without using any other topical medications. Six weeks ago, the patient

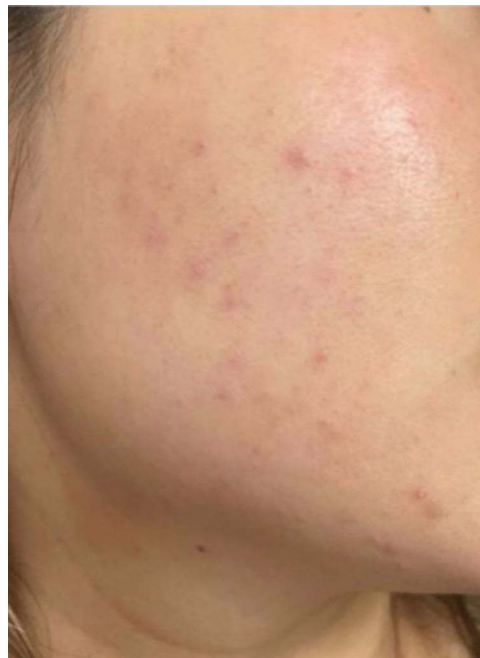began to develop dry itchy rash on her face (Figure 1), and two weeks later multiple small erythematous papules and pustules gradually appeared on both cheeks. The patient did not have a history of using new cosmetic products or any other topical treatment before the symptoms manifested. Physical examination revealed dry, patchy erythematous patch on face and upper part of the neck combined with multiple small edematous erythematous papules and minute whitish papules, size 3–5 mm, discrete on both cheeks (Figure 2). The patient was first diagnosed as acne vulgaris and treated with doxycycline 100 mg twice a day for 2 weeks, but the clinical symptoms did not show any signs of improvement. Laboratory investigations were performed to determine the cause of rash and pustules on the face. Standardized skin surface biopsy from the rash with microscopic examination found 8 *Demodex* mites/cm<sup>2</sup> of sampling area (Figure 3). Superficial needle-scraping with methylene blue staining was used to determine the cause of pustules. Five *Demodex* mites were detected from five pustular lesions on both cheeks (Figure 4A–C). Based on clinical symptoms and laboratory findings, the patient was diagnosed with folliculitis-like type demodicosis and was treated with 2 doses of oral ivermectin (200 µg/kg, 1 week apart) in combination with moisturizer and topical 0.75% metronidazole gel. Most of the erythematous papules, pustules and dry erythematous patch gradually resolved in 2 weeks after treatment had started. All clinical symptoms disappeared in an additional two weeks with topical 0.75% metronidazole gel treatment.

## Discussion

*Demodex* mites are common ectoparasites in human skin. Studies have shown that the number of mites increases with age and is found to be significantly higher in people with obesity, high blood sugar levels, end-stage chronic renal failure and immunodeficiency.<sup>7–9</sup> In addition, an abnormal increase in the number of *Demodex* mites has been reported following repeated facial application of topical steroids and other immunomodulators.<sup>10</sup> Changing in facial skin microenvironment, moisture, pH levels, types and quantities of skin surface lipids and epidermal barrier function may facilitate *Demodex* mite proliferation.<sup>11</sup> The *Demodex* mite can cause multiple skin disorders, which are grouped under the term demodicosis or demodicidosis. Some studies have shown an association between acne vulgaris and *Demodex* mite infestation, suggesting that when conventional treatments for acne vulgaris are ineffective, examination of *Demodex* mites and acaricidal therapies should be considered.<sup>2,12</sup> This report demonstrates a case of demodicosis presenting with clinical symptoms that looked like acne vulgaris, including erythematous edematous papules and pustules on both cheeks, leading to the difficulty in differential diagnosis. Therefore, the method used to determine the mite density per square centimeter is important for diagnosing demodicosis. Standardized skin surface biopsy

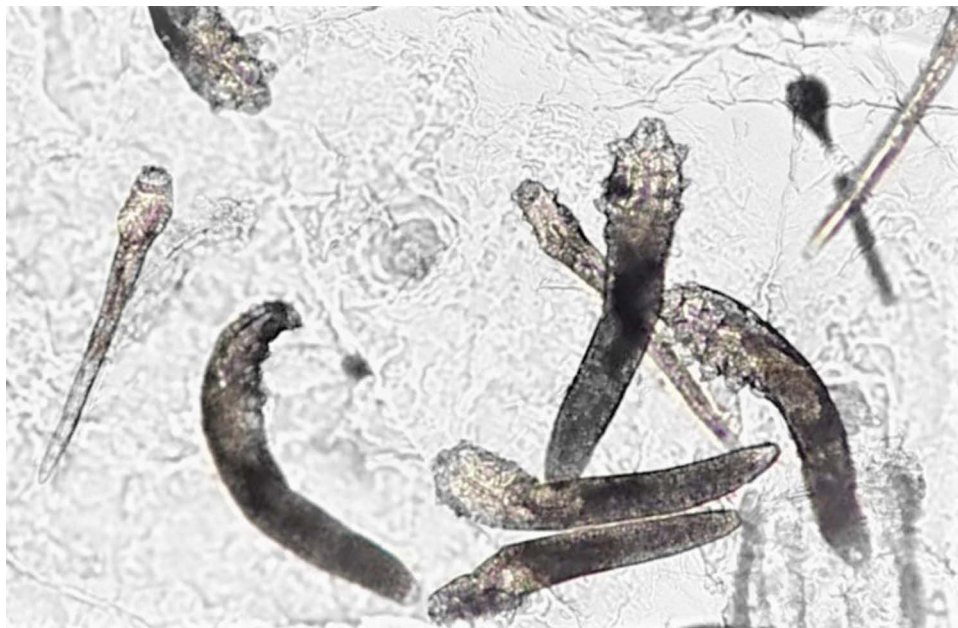

**Figure 1** Dry erythematous patch, follicular scales and rough skin with “sandpaper-like” texture on the right cheek.

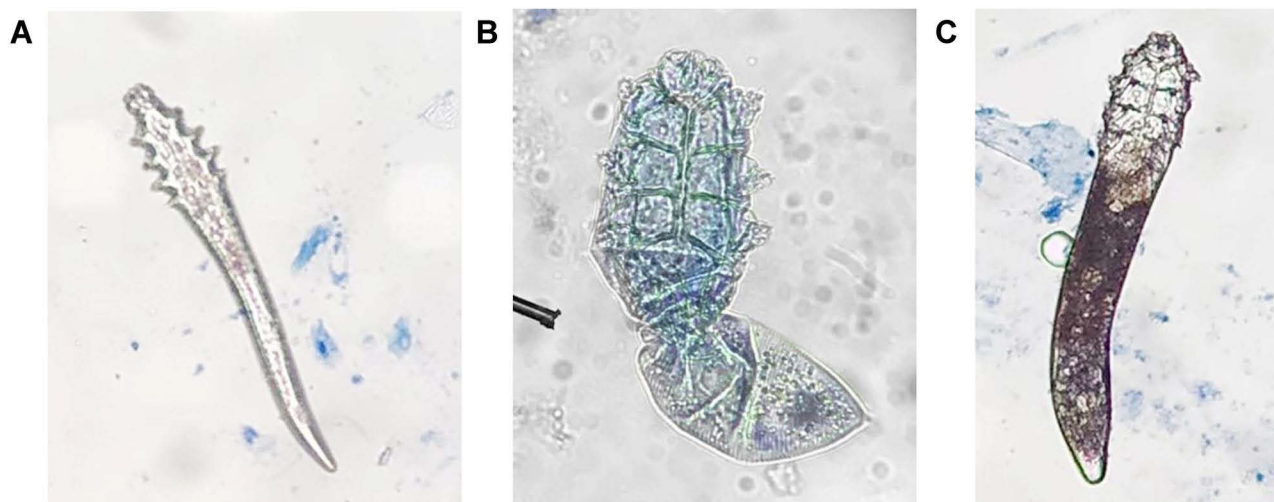


**Figure 2** Dry, patchy erythema on face and upper part of the neck combined with multiple small edematous erythematous papules and minute whitish papules, size 3–5 mm, discrete on the right cheek.

(SSSB) is commonly used to determine *Demodex* mite density from skin of the patients. Demodicosis is diagnosed when there is a high density of *Demodex* mites ( $>5$  *Demodex* mites/cm<sup>2</sup>).<sup>13</sup> A method for assessing *Demodex* mite density in papulopustular lesions, called “superficial needle-scraping” (SNS), is performed by scraping off 5 small pustules with the tip of a needle for microscopic examination. *Demodex* mite density was reported as “mites per 5 pustules” for SNS. Demodicosis is diagnosed when there is a high density of *Demodex* mites, at  $\geq 3$  *Demodex* mites per 5 pustules.<sup>14</sup> In this patient, the results of microscopic examination revealed an abnormal increase in the number of *Demodex* mites from both SSSB and SNS methods and, combined with the relevant clinical presentations, led to the



**Figure 3** Multiple *Demodex* mites are detected by standardized skin surface biopsy from the rash on the right cheek.



**Figure 4 (A–C)** *Demodex* mites are detected by superficial needle-scraping with methylene blue staining from pustular lesions on both cheeks.

diagnosis of folliculitis-like demodicosis. Treatment with acaricides for demodicosis is expected to reduce the excessive number of *Demodex* mites and recover the patients from clinical symptoms. The following topical medications have been reported to be effective for demodicosis: metronidazole, permethrin, benzoyl benzoate, crotamiton, lindane, tea tree oil and ivermectin. All topical treatments should be used with caution, because of the sensitive skin in demodicosis patients, and many topical therapies have also been associated with mild irritation.<sup>15</sup> Oral medication should be considered in patients with severe symptoms or not responding to topical therapy. Oral metronidazole has shown efficacy in reducing *Demodex* mite density and improving clinical symptoms of demodicosis.<sup>16</sup> Ivermectin and fluralaner can inhibit overlapping molecular pathways regulating neuron activity, causing paralysis, lack of feeding and indirect killing effect on the *Demodex* mite, so they can be used to treat demodicosis without side effects to the human body.<sup>17,18</sup> Last year, this patient had a history of pityriasis folliculorum type demodicosis and successful treatment with oral ivermectin. This time, the patient still responded well to oral ivermectin and metronidazole gel treatment despite the changes in clinical type of demodicosis from pityriasis folliculorum type to folliculitis-like type, which imitated acne vulgaris.

## Conclusion

Demodicosis is not an uncommon skin disease and can show a variety of clinical symptoms that dermatologists are not familiar with, making it often misdiagnosed or underdiagnosed. This is a case report of demodicosis presenting with multiple edematous erythematous papules and pustules on both cheeks, misdiagnosed as acne vulgaris. After reassessment based on clinical presentation and laboratory examination that found multiple *Demodex* mites from pustules and rash on both cheeks, the patient was diagnosed with folliculitis-like demodicosis imitating acne vulgaris. Demodicosis can occur whenever there is an imbalance between microenvironment, density of *Demodex* mites and host immunity. Moreover, the clinical presentation of demodicosis can change from one type to another, as in this patient, changing from pityriasis folliculorum type to folliculitis-like type.

## Statement of Ethics

The author states that the patient gave written informed consent for the case to be published (including publication of images). This research complies with all Ethical Guidelines for human studies in accordance with the World Medical Association Declaration of Helsinki. This paper is exempt from The Mae Fah Luang Ethics Committee on Human Research approval, with reference number COE 224/2021. Since it is a case report with no more than three cases, the



report is derived from a review of medical records and cannot be linked to an individual unless the written consent of the patient is obtained.

## Acknowledgments

The author would like to thank School of AntiAging and Regenerative Medicine, Mae Fah Luang University for research facilities.

## Funding

This study did not receive any funding.

## Disclosure

The author reports no conflicts of interest in this work.

## References

1. Karıncaoglu Y, Bayram N, Aycan O, Esrefoglu M. The clinical importance of *Demodex folliculorum* presenting with nonspecific facial signs and symptoms. *J Dermatol*. 2004;31(8):618–626. doi:10.1111/j.1346-8138.2004.tb00567.x
2. Aktaş Karabay E, Aksu Çerman A. *Demodex folliculorum* infestations in common facial dermatoses: acne vulgaris, rosacea, seborrheic dermatitis. *An Bras Dermatol*. 2020;95(2):187–193. doi:10.1016/j.abd.2019.08.023
3. Forton F, De Maertelaer V. Rosacea-like demodicosis and papulopustular rosacea may be two phenotypes of the same disease, and pityriasis folliculorum may be their precursor: response to the comment of Tatu. *J Eur Acad Dermatol Venereol*. 2019;33(1):e47–e48. doi:10.1111/jdv.15162
4. Hsu CK, Hsu MM, Lee JY. Demodicosis: a clinicopathological study. *J Am Acad Dermatol*. 2009;60(3):453–462. doi:10.1016/j.jaad.2008.10.058
5. Akçınar UG, Ünal E, Doğruman A. *Demodex* spp. as a possible aetiopathogenic factor of acne and relation with acne severity and type. *Postepy Dermatol Alergol*. 2018;35(2):174–181. doi:10.5114/ada.2018.75239
6. Yun CH, Yun JH, Baek JO, Roh JY, Lee JR. *Demodex* mite density determinations by standardized skin surface biopsy and direct microscopic examination and their relations with clinical types and distribution patterns. *Ann Dermatol*. 2017;29(2):137–142. doi:10.5021/ad.2017.29.2.137
7. Özer TT, Akyürek Ö, Durmaz S. Association between *Demodex folliculorum* and Metabolic syndrome. *J Cosmet Dermatol*. 2020;19(11):3145–3149. doi:10.1111/jocd.13721
8. Karıncaoglu Y, Seyhan ME, Bayram N, Aycan O, Taskapan H. Incidence of *Demodex folliculorum* in patients with end stage chronic renal failure. *Ren Fail*. 2005;27(5):495–499. doi:10.1080/08860220500198037
9. Ivy SP, Mackall CL, Gore L, Gress RE, Hartley AH. Demodicidosis in childhood acute lymphoblastic leukemia: an opportunistic infection occurring with immunosuppression. *J Pediatr*. 1995;127(5):751–754. doi:10.1016/s0022-3476(95)70168-0
10. Fujiwara S, Okubo Y, Irisawa R, Tsuboi R. Rosaceiform dermatitis associated with topical tacrolimus treatment. *J Am Acad Dermatol*. 2010;62(6):1050–1052. doi:10.1016/j.jaad.2009.01.029
11. Demirdağ HG, Özcan H, Gürsoy Ş, Beker Akbulut GT. The effects of sebum configuration on *Demodex* spp. Density. *Turk J Med Sci*. 2016;46(5):1415–1421. doi:10.3906/sag-1504-77
12. Zhao YE, Hu L, Wu LP, Ma JX. A meta-analysis of association between acne vulgaris and *Demodex* infestation. *J Zhejiang Univ Sci B*. 2012;13(3):192–202. doi:10.1631/jzus.B1100285
13. Forton F, Seys B. Density of *Demodex folliculorum* in rosacea: a case-control study using standardized skin-surface biopsy. *Br J Dermatol*. 1993;128(6):650–659. doi:10.1111/j.1365-2133.1993.tb00261.x
14. Huang HP, Hsu CK, Lee JY. A new superficial needle-scraping method for assessing *Demodex* density in papulopustular rosacea. *J Cosmet Dermatol*. 2020;19(4):896–900. doi:10.1111/jocd.13082
15. Sarac G. A comparison of the efficacy and tolerability of topical agents used in facial *Demodex* treatment. *J Cosmet Dermatol*. 2019;18(6):1784–1787. doi:10.1111/jocd.12986
16. Salem DA, El-Shazly A, Nabih N, El-Bayoumy Y, Saleh S. Evaluation of the efficacy of oral ivermectin in comparison with ivermectin-metronidazole combined therapy in the treatment of ocular and skin lesions of *Demodex folliculorum*. *Int J Infect Dis*. 2013;17(5):e343–347. doi:10.1016/j.ijid.2012.11.022
17. da Rocha MC, Travassos AR, Uva L, Sequeira H, Filipe P. Demodicosis Treatment with Systemic Ivermectin. *Skinmed*. 2017;15(4):293–295.
18. Nakata Y, Fuse T, Yamato K, et al. A single amino acid substitution in the third transmembrane region has opposite impacts on the selectivity of the parasitocides fluralaner and ivermectin for ligand-gated chloride channels. *Mol Pharmacol*. 2017;92(5):546–555. doi:10.1124/mol.117.109413

Clinical, Cosmetic and Investigational Dermatology

Dovepress

Publish your work in this journal

Clinical, Cosmetic and Investigational Dermatology is an international, peer-reviewed, open access, online journal that focuses on the latest clinical and experimental research in all aspects of skin disease and cosmetic interventions. This journal is indexed on CAS. The manuscript management system is completely online and includes a very quick and fair peer-review system, which is all easy to use. Visit <http://www.dovepress.com/testimonials.php> to read real quotes from published authors.

Submit your manuscript here: <https://www.dovepress.com/clinical-cosmetic-and-investigational-dermatology-journal>