

Ultrasound-Guided Thoracic Paravertebral Block Enhances the Quality of Recovery After Modified Radical Mastectomy: A Randomized Controlled Trial

Fudong Rao^{1,*}
Zongjie Wang^{2,*}
Xijuan Chen³
Linwei Liu⁴
Bin Qian¹
Yanhua Guo⁴

¹Department of Anesthesiology, People's Hospital Affiliated to Fujian University of Traditional Chinese Medicine, Fuzhou, Fujian, People's Republic of China;

²Department of Anesthesiology, Longyan First Hospital Affiliated to Fujian Medical University, Longyan, Fujian, People's Republic of China; ³Department of Nephrology, Hematology and Pediatrics, People's Hospital Affiliated to Fujian University of Traditional Chinese Medicine, Fuzhou, Fujian, People's Republic of China; ⁴Department of Anesthesiology, Shengli Clinical Medical College of Fujian Medical University, Fuzhou, Fujian, People's Republic of China

*These authors contributed equally to this work

Correspondence: Bin Qian
Department of Anesthesiology, People's Hospital Affiliated to Fujian University of Traditional Chinese Medicine, No. 602, Middle of Baiyiqi Road, Fuzhou, 350004, People's Republic of China
Tel +86-158800 5016
Fax +86-591-86250061
Email 1547945960@qq.com

Yanhua Guo
Department of Anesthesiology, Shengli Clinical Medical College of Fujian Medical University, No. 134, Dongjie, Fuzhou, 350001, People's Republic of China
Tel +86-8050333902
Fax +86-591-88217841
Email guoyanhua19@126.com

Purpose: Ultrasound-guided thoracic paravertebral block (TPVB) has become increasingly popular for postoperative analgesia after breast surgery. We designed this prospective, randomized, double-blind, placebo-controlled trial to test the hypothesis that TPVB is superior to placebo in improving the patient quality of recovery following modified radical mastectomy.

Patients and Methods: Sixty-eight female patients undergoing elective unilateral modified radical mastectomy were enrolled. Patients were randomized to receive preoperative ultrasound-guided TPVB with 0.5% ropivacaine (TPVB group, n=34) or 0.9% saline (Control group, n=34). The primary outcome was quality of recovery, measured 24 h after surgery using the 40-item Quality of recovery questionnaire (QoR-40). Secondary outcomes were the area under the curve of the visual analog scale pain scores over 24 h, postoperative 24-h morphine consumption, time to first rescue analgesia, length of post-anesthesia care unit stay, postoperative nausea and vomiting, and patient satisfaction.

Results: The global QoR-40 score 24 h postoperatively (median [interquartile range]) was 173 [170–177] in the TPVB group and 161 [160–164] in the control group ($P<0.001$), respectively, with a median difference (95% confidence interval) of 11 (9–14). Compared with the control group, preoperative TPVB decreased the area under the curve of the visual analog scale pain scores over 24 h, reduced postoperative 24-h morphine consumption, prolonged the time to first rescue analgesia, shortened the length of post-anesthesia care unit stay, lessened postoperative nausea and vomiting, and improved the patient satisfaction.

Conclusion: A single preoperative injection of TPVB with ropivacaine enhances the quality of recovery and postoperative analgesia in patients following modified radical mastectomy.

Keywords: ultrasonography, thoracic paravertebral block, quality of recovery, regional anesthesia, pain management, breast cancer surgery

Introduction

Breast cancer is the most commonly diagnosed malignancy and the second leading cause of cancer deaths in women.¹ Surgical removal of the cancer is the mainstay of current treatment. However, breast cancer surgery is frequently associated with moderate to severe postoperative pain.² Acute postoperative pain is not adequately addressed in everyday clinical practice, which may impair functional recovery, increase the risk of postoperative complications, and prolong the length of hospital stay.³ Optimal analgesia is an integral part of enhanced recovery after surgery

pathway to improve patients' outcomes.⁴ Opioids may pose the risk of opioid-related side effects (ie, nausea, vomiting, dizziness, urinary retention, ileus, and respiratory depression) and ongoing opioid use more extended term.⁵ Consequently, clinicians are striving to reduce perioperative opioid consumption, and regional anesthesia is rapidly gaining interest.

Thoracic paravertebral block (TPVB) is a regional nerve block technique that involves injecting a local anesthetic close to the spinal nerves emerging from the intervertebral foramina. The benefits of TPVB have been well established, including reduced postoperative pain scores, decreased analgesic consumption, and lower risks of chronic postsurgical pain.⁶ In addition, the risk of TPVB-related complications is low when ultrasound guidance is used.⁷ As a result, ultrasound-guided TPVB has become increasingly popular and is considered the gold standard for alleviating breast surgical pain. However, pain is an incomplete measure to detect the efficacy of an intervention on postoperative recovery.⁸ More recently, there has been a shift of emphasis towards defining recovery from the patient's perspective.⁹ The 40-item quality of recovery questionnaire (QoR-40) is a reliable patient-reported measurement tool incorporating multiple postoperative domains to assess the quality of recovery after surgery.¹⁰ Nevertheless, do the analgesic properties of TPVB translate into improved quality of recovery in patients undergoing breast surgery has yet not been fully elucidated.

Our goal was to improve patient-perceived quality of recovery and postoperative analgesia while minimizing perioperative opioid consumption. Therefore, we undertook this randomized controlled study to examine the hypothesis that preoperative ultrasound-guided TPVB is associated with improved quality of recovery in patients following modified radical mastectomy, as characterized by the global QoR-40 scores measured 24 h after surgery.

Materials and Methods

Design and Patients

The study was a prospective, single-center, parallel-group, randomized, double-blind clinical trial. Our study protocol was approved by the Institutional Review Board of Fujian Provincial Hospital (identifier: K2014-11-008) and registered at the Chinese Clinical Trial Registry (www.chictr.org.cn, identifier: ChiCTR-INR-16007874). We conducted this study following the Consolidated Standards of Reporting Trials (CONSORT) statement¹¹ and the

principles of the Declaration of Helsinki. After obtaining written informed consent, we enrolled patients with American Society of Anesthesiologists physical status I or II, aged 18 to 60 years old, scheduled to undergo elective unilateral modified radical mastectomy. Exclusion criteria included contradictions to paravertebral block such as coagulopathy, infection at the puncture site, trauma or history of thoracic spine surgery; a history of allergy to any study drugs; a history of opioid abuse or chronic pain, and any other conditions that were not appropriate for this study.

Patients were randomized to receive preoperative single-injection of ultrasound-guided TPVB with 20 mL of 0.5% ropivacaine (TPVB group, n=34) or 0.9% saline (Control group, n=34). The randomization was performed in a 1:1 ratio according to a computer-generated table. Group assignments were enclosed in sealed, opaque, sequentially numbered envelopes opened only on the morning of the surgery day. In addition, a single independent research nurse not involved in the study prepared identical syringes containing study injectate (0.5% ropivacaine or 0.9% saline). The patients, attending anesthesiologists, surgeons, and data collectors were blinded to group assignments throughout the entire study period.

Ultrasound-Guided Thoracic Paravertebral Block

Upon arrival in the operating room, all patients received the standard American Society of Anesthesiologists monitoring and were intravenously administered 2 mg midazolam as premedication. The TPVB intervention was performed 30 min before the induction of anesthesia. A single experienced anesthetist performed all TPVBs under ultrasound guidance (Model Edge, FUJIFILM SonoSite, Inc. Washington, USA). The patients were placed in the lateral decubitus position. A 6–13 MHz linear array (HFL38; FUJIFILM SonoSite, Inc., Bothell, WA, USA) ultrasound transducer was placed longitudinally at the midline of the third thoracic vertebra level. A 21 gauge, 80-mm Uniplex Nanoline needle (Pajunk Medical System, Geisingen, Germany) was introduced using an in-plane approach toward the target paravertebral space. Briefly, the probe was administered in a cephalad orientation and moved to identify the transverse process and parietal pleura. Then, the needle was introduced to puncture the superior costotransverse ligament. Once the correct needle tip position was confirmed by hydrolocation

using 1 mL of 0.9% saline, 20 mL of 0.5% ropivacaine or 0.9% saline was injected into the target paravertebral space.

Anesthetic Procedure

All patients received a standardized general anesthesia regimen. General anesthesia was induced with propofol 2 mg kg^{-1} and sufentanil $0.5 \text{ } \mu\text{g kg}^{-1}$. Upon loss of verbal response, rocuronium 0.6 mg kg^{-1} was administered to facilitate laryngeal mask airway (LMA) insertion. All patients received ondansetron 4 mg and dexamethasone 8 mg immediately after induction of anesthesia. We maintained general anesthesia with sevoflurane (0.8 age-corrected minimum alveolar concentration) in the air and oxygen mixture. Supplemental analgesia was provided by intravenous remifentanyl infusion titrated as necessary to maintain hemodynamic parameters (heart rate and blood pressure) fluctuate within 20% of the baseline values. Patients were ventilated using pressure-controlled ventilation to maintain an end-tidal carbon dioxide partial pressure (PaCO_2) between 35 to 45 mmHg. At the end of the surgery, neuromuscular blockade was antagonized with neostigmine 1 mg and atropine 0.5 mg, if necessary. After removing the LMA, the patients were then transferred to the post-anesthesia care unit (PACU) for observation. The postoperative analgesic regimen consisted of regular intravenous administered parecoxib 40 mg every 12 h and patient-controlled intravenous analgesia (PCIA) with morphine. We set the PCIA pump to deliver a bolus dose of 2 mg morphine (1 mg mL^{-1}) on-demand, with a lockout interval of 10 min and without basal infusion. If the visual analog scale (VAS) pain score exceeded 3 cm or the patient required, intravenous morphine 2 mg was administered as a rescue analgesic by the patient using the PCIA device (DDB-I-B, Aipu Medical Corporation, Jiangsu, China). If postoperative nausea or vomiting occurred, ondansetron 4 mg and metoclopramide 10 mg were administered intravenously every 8 h as rescue antiemetics.

Primary and Secondary Outcomes

We aimed to determine whether preoperative single-injection TPVB is superior to placebo in improving the quality of recovery following modified radical mastectomy. The primary outcome was quality of recovery, measured 24 h postoperatively using the Chinese version of the QoR-40 questionnaire.¹² The global QoR-40 score ranges from 40 (poor quality) to 200 (excellent quality).¹³

Secondary outcomes were the area under the curve (AUC) of VAS pain scores over 24 h, 24-h morphine consumption postoperatively, time to the first rescue analgesia, length of PACU stay, the incidence of postoperative nausea and vomiting (PONV), and patient's satisfaction with pain management. Postoperative pain intensity at rest and on movement was evaluated using a 10-cm horizontal VAS from "no pain" (0 cm) to "worst pain imaginable" (10 cm) and calculated as the AUC of VAS pain scores during the first 24 h. We defined time to first rescue analgesia as the time between emergence from general anesthesia and the VAS pain score exceeded 3 cm. We determined the length of PACU stays as the interval from PACU admission to the Modified Aldrete score reached 9. Patient satisfaction with pain management was self-reported using an 11-point numerical rating scale at postoperative 24 h (range 0–10, 0 equals entirely unsatisfied; 10 equals fully satisfied).

Statistical Analysis

The sample size was calculated based on the global QoR-40 score 24 h after surgery. We considered a 10-difference in the global QoR-40 score as a clinically significant improvement in QoR after surgery and anesthesia.¹⁴ According to the pilot study, the global QoR-40 score measured at 24 h after surgery was equivalent to 142 (12.1) in the control group. Assuming a two-tailed alpha of 0.05 and a power (1-beta) of 90%, 31 patients in each group were required. To account for withdrawal and loss for follow-up, we finally recruited 68 patients in this study.

We tested the normality of continuous variable distribution using the Shapiro–Wilk test. Normally distributed variables are presented as mean (standard deviation, SD) and were compared using the independent samples *t*-test. Non-normally distributed variables are expressed as median [interquartile range, IQR] and were compared using the Mann–Whitney *U*-test. Categorical variables are summarized as numbers (percentage) and were compared by Fisher's exact or chi-square test where appropriate. The AUCs of VAS pain scores over postoperative 24 h were calculated using GraphPad Prism 8.0 (GraphPad Software, California, USA) and analyzed by the Mann–Whitney *U*-test. Time-to-event data (time to first request of rescue analgesia) were analyzed using Kaplan–Meier curves and Log rank tests. We performed statistical analysis using IBM SPSS Statistics for Windows, Version 25.0 (IBM Corp., Armonk, NY, USA). Differences were considered significant if $P < 0.05$ (two-tailed).

Result

The CONSORT flow diagram for this study is shown in Figure 1. A total of 71 patients were assessed for eligibility. One did not meet the inclusion criteria, two declined to participate, and the remaining 68 patients were randomly assigned to receive TPVB either with 0.5% ropivacaine or 0.9% saline. All patients enrolled received the allocated intervention, and no patients were lost to follow-up. The two groups were similar concerning demographics, duration of surgery, and preoperative global QoR-40 score (Table 1).

The global QoR-40 scores assessed at 24 h after surgery, the primary outcome, is shown in Figure 2. Coincided with our expectation, the global QoR-40 scores on POD 1 were significantly higher in the TPVB group (median 173; IQR 170–177) than in the control group (161; 160–164; $P<0.001$), with a median difference of 11 (95% CI, 9 to 14). A single injection of TPVB reduced VAS pain scores at rest and on movement within 12 h after surgery (all $P<0.001$, Figure 3). However, there was no significant

difference 24 h postoperatively at rest ($P=0.065$) or on movement ($P=0.076$). As presented in Table 2, TPVB decreased the AUCs of VAS pain scores at rest during the first 24 h postoperatively (36.9 [28.8–42.0] vs 54.0 [46.7–61.3], $P<0.001$). Similarly, TPVB decreased the AUCs of VAS pain scores on movement during the first 24 h after surgery (55.3 [51.6–61.6] vs 72.1 [66.8–82.9], $P<0.001$).

The median time to first rescue analgesia after surgery was 9.7 h (95% CI, 8.3 to 11.1 h) in the TPVB group and 1.7 h (95% CI, 1.4 to 2.0 h) in the control group, respectively ($P<0.001$, Figure 4). Compared with the control group, postoperative cumulative morphine consumption (median [IQR]) during the initial 24 h postoperatively was also lower in the TPVB group (12 mg [8–14] vs 28 mg [24–32], $P<0.001$). The difference in morphine consumption equals –16 mg (95% CI, –18 to –14 mg). Furthermore, preoperative TPVB shortened PACU length of stay, decreased the occurrence of PONV, and improved patient satisfaction with pain management (Table 2). None

CONSORT 2010 Flow Diagram

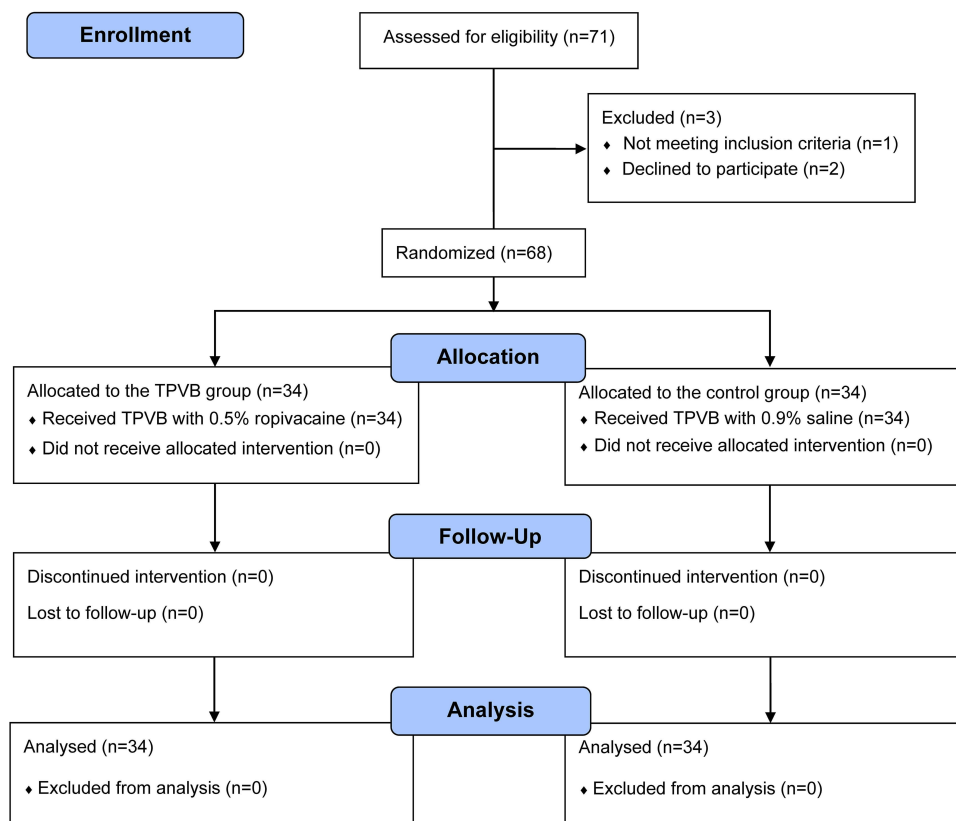


Figure 1 Consolidated standards of reporting trials (CONSORT) flowchart describing patient progress through the study.

Abbreviation: TPVB, thoracic paravertebral block.

Table 1 Patient Demographic and Clinical Parameters in the Study

	Group TPVB (n = 34)	Group Control (n = 34)	P-value
Age, years	53.6 (6.2)	53.4 (6.6)	0.925
Height, cm	163 [158–169]	165 [159–170]	0.288
Weight, kg	59.8 (7.9)	62.2 (9.3)	0.251
ASA physical status, n (%)			0.417
I	8 (26.5)	11 (41.2)	
II	26 (73.5)	23 (58.8)	
Duration of surgery, min	110.6 (10.6)	113.9 (11.1)	0.218
Preoperative QoR-40 score	182.2 (4.8)	182.9 (4.0)	0.509

Note: Data are presented as mean (SD), median [interquartile range], or number (percentage).

Abbreviations: ASA, American Society of Anesthesiologists; QoR-40, 40-item quality of recovery questionnaire; SD, standard deviation; TPVB, thoracic paravertebral block.

of the TPVB-related adverse events (eg, pleural puncture, pneumothorax, or local anesthetic systemic toxicity) was identified during the study.

Discussion

This randomized, double-blind, placebo-controlled study demonstrated that compared with saline injection, a single-

injection TPVB with ropivacaine was associated with higher global QoR-40 scores in patients after a modified radical mastectomy. Furthermore, ropivacaine TPVB provided superior pain relief in the early postoperative period, prolonged time to first rescue analgesia, lower morphine consumption up to 24 h postoperatively, and fewer opioid-related side effects than general anesthesia alone. Taken together, these findings indicate that preoperative administration of TPVB might be a promising strategy for postoperative analgesia, facilitating early recovery and minimizing medical resource consumption.

Recovery from surgery is a complex process dependent on the patient, surgical, and anesthetic factors. Regional anesthesia technique has provided excellent postoperative analgesia and improved the quality of recovery after surgery.^{15–17} The QoR-40 score, a validated patient-reported outcome measurement, has recently been recommended as one of six endpoints in perioperative medicine to assess patient comfort and pain after surgery.⁸ In this study, preoperative ultrasound-guided single-injection TPVB with 0.5% ropivacaine resulted in a change of 11 for the QoR-40 score, signifying a clinically relevant improvement in patients' early postoperative health status,¹⁸ which indicates the use of TPVB for enhancing recovery after breast surgery.

Postoperative pain remains the challenge for patients undergoing breast surgery; strategies to limit pain have been increasingly expounded.¹⁹ Regional anesthesia techniques that suit breast surgery include TPVB, erector spinal plane block (ESPB), and pectoral nerve block. Swisher and colleagues propose that TPVB is superior to ESPB for short-term analgesias and opioid-sparing after non-mastectomy breast surgery.²⁰ A systematic review also suggests that pectoral nerve block and TPVB are comparable in postoperative analgesia efficacy for mastectomy.²¹ Consequently, the choice of regional anesthesia technique will depend on physician experience and institutional policy. The TPVB provides potent analgesia via blockade of the dorsal rami, and ventral rami emerge from the spinal canal. Preoperative TPVB with ropivacaine may provide preventive analgesia by reducing central sensitization and opioid-induced hyperalgesia, decreasing AUCs of the VAS pain scores over 24 h, reducing postoperative 24-h morphine consumption, prolonging the time first to request rescue analgesia, and reducing the incidence of PONV, consistent with the literature.^{22,23}

Our findings indicate that TPVB might be the cornerstone of the multimodal analgesia regimen for breast surgery

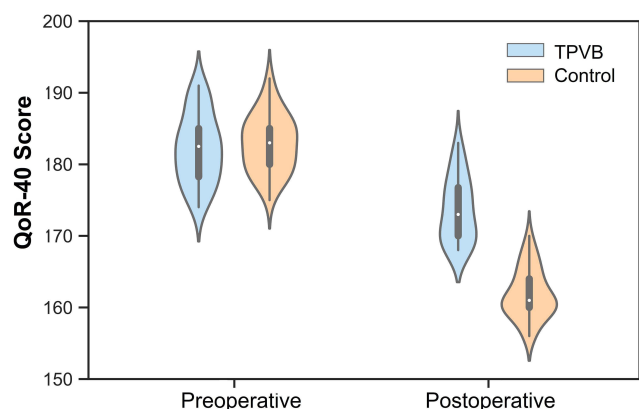


Figure 2 Violin plots of the global QoR-40 scores before surgery and 24 h after surgery. The global QoR-40 scores in the TPVB group were higher than the control group ($P < 0.001$ by the Mann–Whitney U -test), with a median difference of 11 (95% confidence interval, 9 to 14).

Notes: The violin plots feature a kernel density estimation of the underlying distribution. The white dot represents the median and the thick bar represents the interquartile range.

Abbreviations: TPVB, thoracic paravertebral block; QoR-40, 40-item of quality of recovery questionnaire.

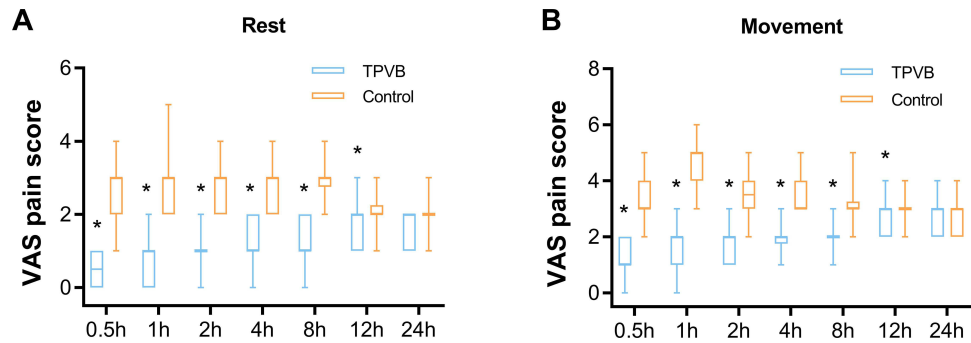


Figure 3 Box plots of postoperative visual analog scale pain scores at rest (A) and on movement (B) in patients receiving TPVB with 0.5% ropivacaine or 0.9% saline during the first 24 h postoperatively.

Notes: Boxes indicate 25th, 75th percentiles; lines indicate median; whiskers indicate the range (minimum to maximum). *Indicate statistically significant ($P<0.001$) between-group differences.

Abbreviations: VAS, visual analog scale; TPVB, thoracic paravertebral block.

patients. Furthermore, regional analgesia may offer some advantages in tumor extension and recurrence following breast cancer surgery.²⁴ Nevertheless, a single injection of TPVB only with 0.5% ropivacaine did not produce long-term analgesia. Therefore, further research is required to determine whether an adjuvant (such as dexmedetomidine and dexamethasone) to local anesthetic agents increases the quality and duration of analgesia.

In this trial, no TPVB-related complications such as pleural puncture, pneumothorax, or local anesthetic systemic toxicity were identified. Additionally, no clinically significant bradycardia or hypotension was noted in this study. This may be because TPVB produces only unilateral and limited sympathetic blockade. In contrast to thoracic epidural analgesia, TPVB can be safely performed on patients with marginal coagulation.²⁵ Ultrasound-guided

single-injection TPVB results in a similar analgesic profile compared with multiple-injection TPVB.²⁶ Besides, ultrasound-guided single-injection TPVB takes less time to perform and might be associated with minor patient discomfort. Thus, we would prefer to perform a single-injection TPVB rather than multiple-injection TPVB in this study.

The study is subject to several limitations. First, we did not map the sensory block area before surgery because the trial was designed to minimize bias using placebo and blinding. Previous studies have indicated that single-injection TPVB achieves loss of sensation at the T2 to T6 levels.^{27,28} Additionally, all TPVBs were performed by a single experienced anesthesiologist under the guidance of ultrasound. Second, parecoxib and dexamethasone might cause underestimation of the difference in

Table 2 Secondary Outcomes During the Study Period

	Group TPVB (n = 34)	Group Control (n = 34)	P-value
Remifentanyl consumption, mg	0.05 [0–0.12]	0.28 [0.20–0.34]	<0.001
Postoperative 24-h morphine consumption, mg	12 [8–14]	28 [24–32]	<0.001
AUC of VAS Pain Scores Over 24 h			
At rest	36.9 [28.8–42.0]	54.0 [46.7–61.3]	<0.001
On movement	55.3 [51.6–61.6]	72.1 [66.8–82.9]	<0.001
Length of PACU stay, min	15 [10–15]	30 [30–35]	<0.001
Occurrence of PONV, n (%)	2 (5.9)	8 (23.5)	0.040
Occurrence of pruritus, n (%)	0	2 (5.9)	0.493
Patient satisfaction score	9 [8–9]	8 [7–8]	<0.001

Note: Data are presented as mean (SD), median [interquartile range], or number (percentage).

Abbreviations: AUC, area under the curve; PACU, post-anesthesia care unit; PONV, postoperative nausea and vomiting; TPVB, thoracic paravertebral block; SD, standard deviation; VAS, numeric rating scale.

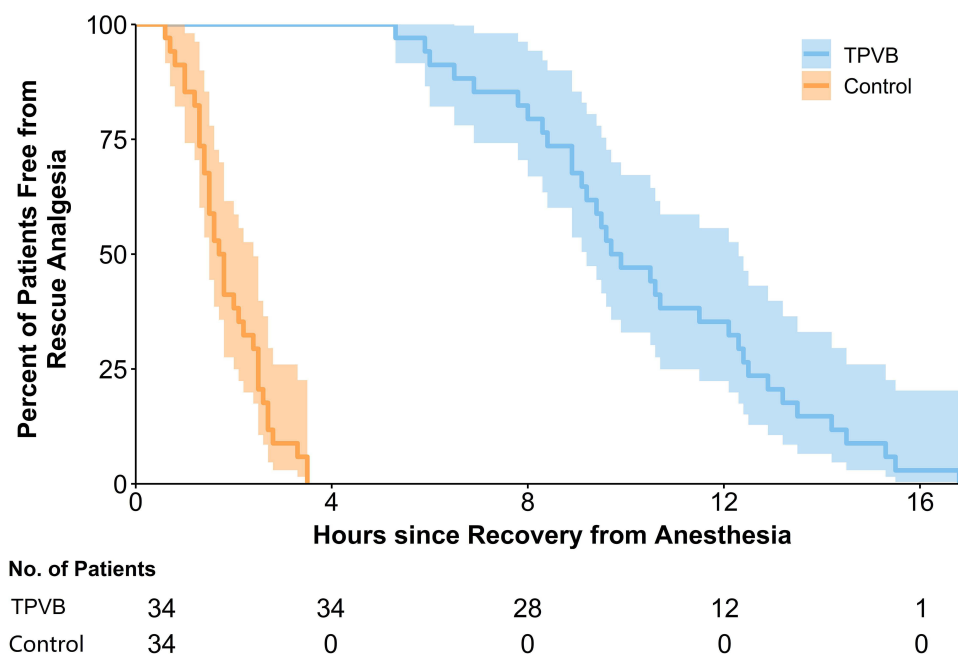


Figure 4 Kaplan-Meier survival plot of time to first rescue analgesia, defined as the time from emergence from general anesthesia until the VAS pain score exceeded 3 cm. **Abbreviations:** TPVB, thoracic paravertebral block; VAS, visual analog scale.

postoperative opioid consumption between the two groups, even if all the patients receive a standardized perioperative multimodal analgesic regimen. Lastly, the generalizability of our results may be limited, considering that the essential condition of our population was relatively healthy.

Conclusion

In summary, for patients undergoing modified radical mastectomy, preoperative ultrasound-guided single-injection TPVB with 0.5% ropivacaine, as a part of a multimodal postoperative analgesic regimen, is a feasible and effective strategy for improving the quality of recovery and postoperative analgesia during the early postoperative period.

Data Sharing Statement

The individual de-identified participant data underlying published results can be accessed upon reasonable request from the corresponding author (Dr. Bin Qian, 1547945960@qq.com) after publication. The study protocol, statistical analysis plan, and clinical study report will also be available.

Acknowledgments

This study was partly supported by Fujian Medical Innovation Project (grant number 2015-CXB-24) and Fujian Medical University Startup Fund for Scientific Research

(grant number 2019QH1171). We gratefully acknowledge Prof. Yusheng Yao for his support and cooperation.

Author Contributions

All authors made substantial contributions to conception and design, acquisition of data, or analysis and interpretation of data; took part in drafting the article or revising it critically for important intellectual content; gave final approval of the version to be published in the current journal; and agree to be accountable for all aspects of the work. Fudong Rao and Zongjie Wang are equal first authors.

Disclosure

The authors report no conflicts of interest in this work.

References

1. Siegel RL, Miller KD, Fuchs HE, et al. Cancer statistics. *CA Cancer J Clin*. 2021;71:7–33. doi:10.3322/caac.21654
2. Fecho K, Miller NR, Merritt SA, et al. Acute and persistent postoperative pain after breast surgery. *Pain Med*. 2009;10:708–715. doi:10.1111/j.1526-4637.2009.00611.x
3. McCartney CJL, Abdallah F. Pain relief and recovery after breast cancer surgery: translating best evidence into practice. *Anaesthesia*. 2020;75:1136–1138. doi:10.1111/anae.15033
4. Memtsoudis SG, Fiasconaro M, Soffin EM, et al. Enhanced recovery after surgery components and perioperative outcomes: a nationwide observational study. *Br J Anaesth*. 2020;124:638–647. doi:10.1016/j.bja.2020.01.017

5. Marcusa DP, Mann RA, Cron DC, et al. Prescription opioid use among opioid-naïve women undergoing immediate breast reconstruction. *Plast Reconstr Surg.* 2017;140:1081–1090. doi:10.1097/PRS.0000000000003832
6. Karmakar MK. Thoracic paravertebral block. *Anesthesiology.* 2001;95:771–780. doi:10.1097/0000542-200109000-00033
7. Niesen AD, Jacob AK, Law LA, et al. Complication rate of ultrasound-guided paravertebral block for breast surgery. *Reg Anesth Pain Med.* 2020;45:813–817. doi:10.1136/rapm-2020-101402
8. Myles PS, Boney O, Botti M, et al. Systematic review and consensus definitions for the standardised endpoints in perioperative medicine (STEP) initiative: patient comfort. *Br J Anaesth.* 2018;120:705–711. doi:10.1016/j.bja.2017.12.037
9. Moonesinghe SR, Jackson AIR, Boney O, et al. Systematic review and consensus definitions for the standardized endpoints in perioperative medicine initiative: patient-centered outcomes. *Br J Anaesth.* 2019;123:664–670. doi:10.1016/j.bja.2019.07.020
10. Myles PS. Measuring quality of recovery in perioperative clinical trials. *Curr Opin Anaesthesiol.* 2018;31:396–401. doi:10.1097/ACO.0000000000000612
11. Schulz KF, Altman DG, Moher D, et al. CONSORT 2010 statement: updated guidelines for reporting parallel group randomized trials. *BMJ.* 2010;340:c332. doi:10.1136/bmj.c332
12. Chen Y, Wang J, Liu S, et al. Development and validation of the Chinese version of the quality of recovery-40 questionnaire. *Ther Clin Risk Manag.* 2020;16:1165–1173. doi:10.2147/TCRM.S281572
13. Myles PS, Weitkamp B, Jones K, et al. Validity and reliability of a postoperative quality of recovery score: the QoR-40. *Br J Anaesth.* 2000;84:11–15. doi:10.1093/oxfordjournals.bja.a013366
14. Gornall BF, Myles PS, Smith CL, et al. Measurement of quality of recovery using the QoR-40: a quantitative systematic review. *Br J Anaesth.* 2013;111:161–169. doi:10.1093/bja/aet014
15. Moller JF, Nikolajsen L, Rodt SA, et al. Thoracic paravertebral block for breast cancer surgery: a randomized double-blind study. *Anesth Analg.* 2007;105:1848–1851. doi:10.1213/01.ane.0000286135.21333.f0
16. Wu J, Buggy D, Fleischmann E, et al. Thoracic paravertebral regional anesthesia improves analgesia after breast cancer surgery: a randomized controlled multicentre clinical trial. *Can J Anaesth.* 2015;62:241–251. doi:10.1007/s12630-014-0285-8
17. Woodworth GE, Ivie RMJ, Nelson SM, et al. Perioperative breast analgesia: a qualitative review of anatomy and regional techniques. *Reg Anesth Pain Med.* 2017;42:609–631. doi:10.1097/AAP.0000000000000641
18. Myles PS, Myles DB, Gallagher W, et al. Minimal clinically important difference for three quality of recovery scales. *Anesthesiology.* 2016;125:39–45. doi:10.1097/ALN.0000000000001158
19. Jacobs A, Lemoine A, Joshi GP, et al. PROSPECT guideline for oncological breast surgery: a systematic review and procedure-specific postoperative pain management recommendations. *Anesthesia.* 2020;75:664–673. doi:10.1111/anae.14964
20. Swisher MW, Wallace AM, Sztain JF, et al. Erector spinae plane versus paravertebral nerve blocks for postoperative analgesia after breast surgery: a randomized clinical trial. *Reg Anesth Pain Med.* 2020;45:260–266. doi:10.1136/rapm-2019-101013
21. Jin Z, Durrands T, Li R, et al. Pectoral block versus paravertebral block: a systematic review, meta-analysis and trial sequential analysis. *Reg Anesth Pain Med.* 2020;45:727–732. doi:10.1136/rapm-2020-101512
22. Abdallah FW, Morgan PJ, Cil T, et al. Ultrasound-guided multilevel paravertebral blocks and total intravenous anesthesia improve the quality of recovery after ambulatory breast tumor resection. *Anesthesiology.* 2014;120:703–713. doi:10.1097/ALN.0000436117.52143.bc
23. Gürkan Y, Aksu C, Kuş A, et al. Erector spinae plane block and thoracic paravertebral block for breast surgery compared to IV-morphine: a randomized controlled trial. *J Clin Anesth.* 2020;59:84–88. doi:10.1016/j.jclinane.2019.06.036
24. Sekandarzad MW, van Zundert AAJ, Lirk PB, et al. Perioperative anesthesia care and tumor progression. *Anesth Analg.* 2017;124:1697–1708. doi:10.1213/ANE.0000000000001652
25. Schnabel A, Reichl SU, Kranke P, et al. Efficacy and safety of paravertebral blocks in breast surgery: a meta-analysis of randomized controlled trials. *Br J Anaesth.* 2010;105:842–852. doi:10.1093/bja/aeq265
26. Uppal V, Sondekoppam RV, Sodhi P, et al. Single-injection versus multiple-injection technique of ultrasound-guided paravertebral blocks: a randomized controlled study comparing dermatomal spread. *Reg Anesth Pain Med.* 2017;42:575–581. doi:10.1097/AAP.0000000000000631
27. Kulhari S, Bharti N, Bala I, et al. Efficacy of pectoral nerve block versus thoracic paravertebral block for postoperative analgesia after radical mastectomy: a randomized controlled trial. *Br J Anaesth.* 2016;117:382–386. doi:10.1093/bja/aew223
28. Fujii T, Shibata Y, Ban Y, et al. A single paravertebral injection via a needle vs. a catheter for the spreading to multiple intercostal levels: a randomized controlled trial. *J Anesth.* 2020;34:72–78. doi:10.1007/s00540-019-02713-6

Journal of Pain Research

Publish your work in this journal

The Journal of Pain Research is an international, peer reviewed, open access, online journal that welcomes laboratory and clinical findings in the fields of pain research and the prevention and management of pain. Original research, reviews, symposium reports, hypothesis formation and commentaries are all considered for publication. The manuscript

management system is completely online and includes a very quick and fair peer-review system, which is all easy to use. Visit <http://www.dovepress.com/testimonials.php> to read real quotes from published authors.

Submit your manuscript here: <https://www.dovepress.com/journal-of-pain-research-journal>

Dovepress