

Idiopathic Hepatic Portal Venous Gas in a Healthy Young Man

This article was published in the following Dove Press journal:
International Journal of General Medicine

Hong Jun Kim ¹
Hong-Kyu Kim ²

¹Division of Hematology-Oncology, Department of Internal Medicine, Kyung Hee University School of Medicine, Seoul, Republic of Korea; ²Department of Surgery, Seoul National University College of Medicine, Seoul, Republic of Korea

Background: Hepatic portal venous gas (HPVG) is a pathological condition characterized by gas in the portal venous system and its branches. The clinical manifestations of HPVG range from benign to life-threatening conditions. Here, we present a rare case of HPVG accompanied by free air in a healthy young patient without any suspicious etiology.

Case Presentation: A 28-year-old man without any specific medical history complained of sudden-onset dyspnea. On admission, his vital signs were stable, and the laboratory tests and physical examinations were within normal range. A plain chest and abdominal film revealed subphrenic free air and HPVG. Contrast-enhanced computed tomography (CT) showed extensive portal venous gas throughout the liver; however, there were no abnormal findings indicative of the etiology. Considering the stable vital signs and the lack of physical findings suggesting a surgical acute abdomen, the patient was managed conservatively. On admission day 3, the subphrenic free air and HPVG shown in the initial study had almost resolved, with no new symptoms. He was discharged on the fourth day after admission without any complications. Esophagogastroduodenoscopy, colonoscopy, and colonography protocol CT scan showed no significant abnormalities.

Conclusion: This case suggests that idiopathic HPVG could appear in healthy patients complaining only of vague symptoms. Initial conservative management could be considered if HPVG does not result from a life-threatening condition that needs immediate management, and if the patient is stable.

Keywords: hepatic portal venous gas, pneumoperitoneum, pneumoretroperitoneum, idiopathic

Introduction

Hepatic portal venous gas (HPVG) was first reported as a pathological condition by Wolfe and Evans in 1955, in infants with necrotizing enterocolitis.¹ It is a relatively rare disease, defined by the presence of gas in the portal venous system and its branches.² The diagnosis of HPVG implies various underlying clinical conditions, ranging from benign etiologies to severe clinical conditions that need immediate surgical treatment.³⁻⁵ Historically, it was commonly found in patients with bowel necrosis with very poor outcome; however, with the advancement of imaging technology, more cases are being diagnosed due to various other benign conditions.^{6,7} We present a rare case of HPVG accompanied by free air which appeared in a healthy young patient without any suspicious etiology.

Correspondence: Hong-Kyu Kim
Department of Surgery, Seoul National University College of Medicine, 101, Daehak-ro, Jongno-gu, Seoul 03080, Republic of Korea
Tel +82-2-958-8188
Email limittango@gmail.com

Case Presentation

A 28-year-old man presented to the emergency room complaining of sudden-onset dyspnea, with no predisposing factors. The dyspnea lasted less than two hours and had almost resolved upon arrival at the emergency room, and there were no accompanying symptoms. He revealed no medical history other than two operations related to trauma, namely, a right anterior cruciate ligament reconstruction four years earlier, and nasal fracture reduction 13 years earlier. He denied any history of medication, and underlying diseases including connective tissue disease. The patient had never smoked, and drank a bottle of beer with 4.5% alcohol twice a week.

On admission, he did not complain of fever, cold sensation, diarrhea, or abdominal pain. His vital signs on presentation demonstrated a temperature of 36.2°C, a heart rate of 72 beats per minute, a respiratory rate of 19 breaths per minute, a blood pressure of 120/80 mm Hg, and an oxygen saturation of 97% on room air. He presented with a soft abdomen with normoactive bowel sounds, and no abdominal tenderness to palpation on physical examination. A plain chest and abdominal film showed subphrenic free air and an unremarkable bowel gas pattern (Figure 1). The laboratory tests presented the following results: serum total bilirubin, 1.67 mg/dL (normal, 0.3–1.2 mg/dL); alanine aminotransferase, 24 IU/L (normal, <50 U/L); aspartate aminotransferase, 25 IU/L (normal,

<50 U/L); amylase, 47 U/L (normal, 28–100 U/L); and C-reactive protein, 0.48 mg/dL (normal, < 0.5 mg/dL). Given the free air finding on the chest X-ray, we were highly suspicious of bowel perforation. We therefore performed contrast-enhanced computed tomography (CT) of the abdomen.

A CT scan revealed a pneumoperitoneum in the right upper quadrant, pneumoretroperitoneum, and gas in the entire portal venous system, without bowel wall thickening, bowel dilatation, bowel perforation, intramural gas, or any abnormal findings in the mesenteric arteries (Figure 2). The diagnosis of HPVG accompanied by free air was made by CT scan; however, no underlying etiology was identified. The patient denied a recent history of trauma, endoscopic procedures, asphyxia, or heavy lifting activity, or any symptoms suggestive of an infectious disease.

Considering the stable vital signs and the lack of physical findings suggesting a surgical acute abdomen, the patient was conservatively managed with fluid resuscitation and antibiotics, including cefotaxime 2 g every 8 hours and metronidazole 500 mg every 8 hours, and was kept nil-per-os. On admission day 3, the follow-up simple erect abdominal X-ray revealed resolving free air (Figure 3A), and no new symptoms appeared. Oral feeding was initiated, after confirming that there were no abnormalities on esophago-gastroduodenoscopic examination (Figure 3B). The patient

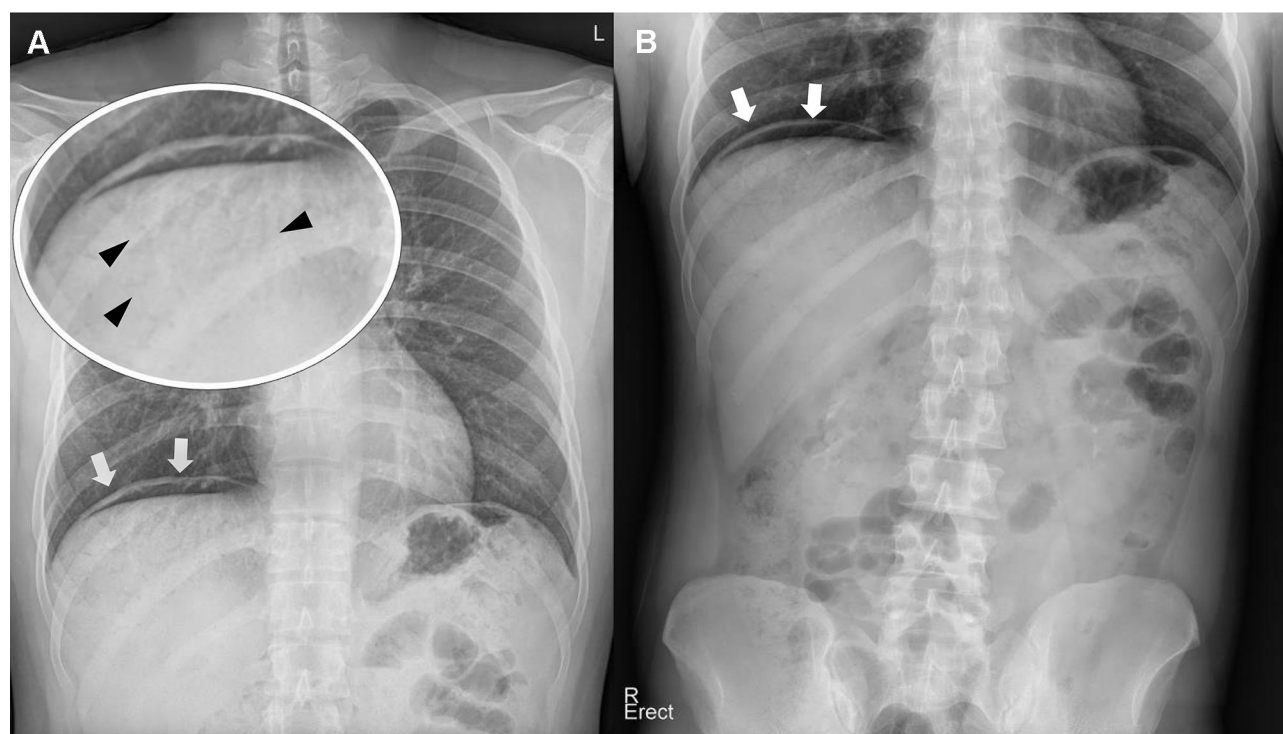


Figure 1 Plain chest (A) and abdominal (B) radiograph showing subphrenic free air (white arrow) and hepatic portal venous gas (arrowhead).

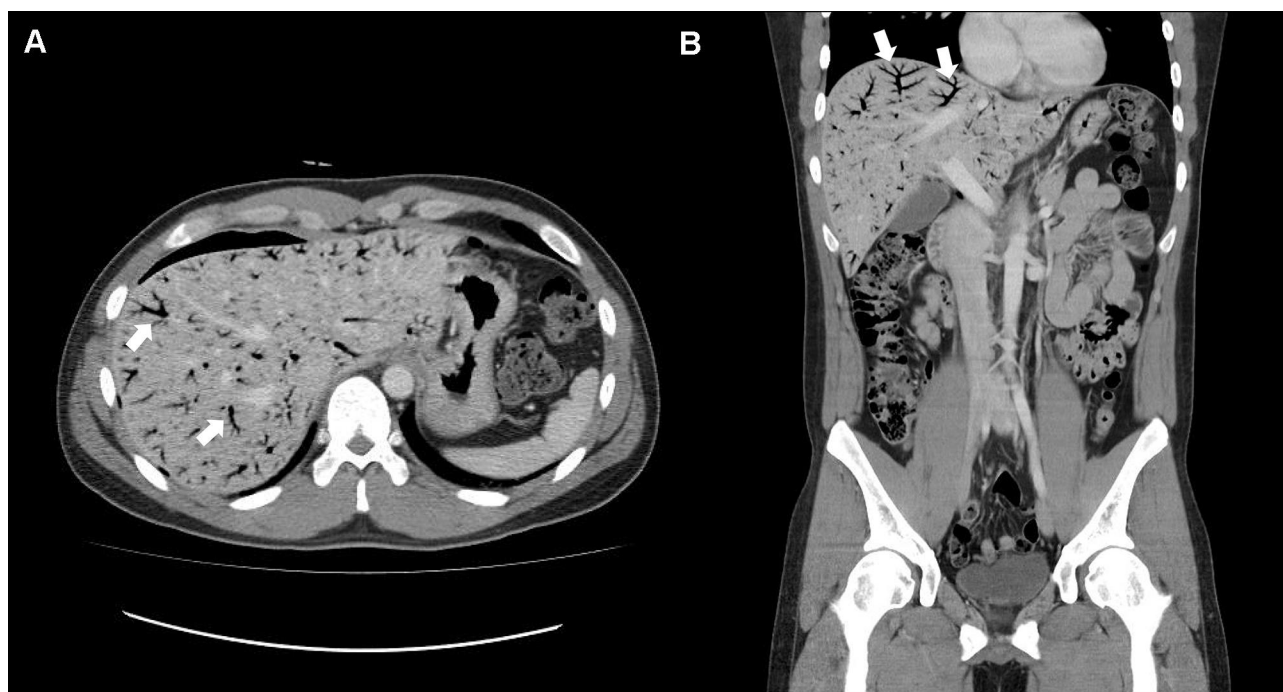


Figure 2 Contrast-enhanced computed tomography showing extensive portal venous gas of the entire liver (white arrow). Axial (A) and coronal (B) view.

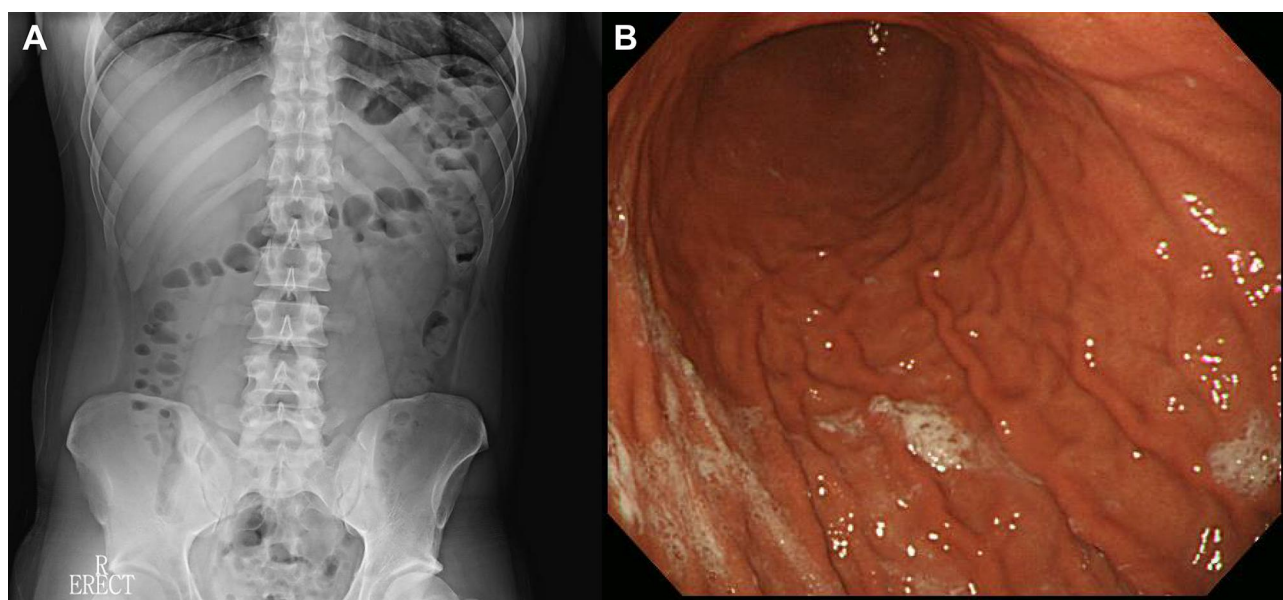


Figure 3 Follow-up plain abdominal radiograph (A) and esophagogastroduodenoscopy (B). The subphrenic free air and hepatic portal venous gas identified in the initial study had almost resolved. Esophagogastroduodenoscopy showed no abnormal findings.

was able to tolerate oral food intake without any complications, and was later discharged.

The follow-up CT scan, performed two weeks after discharge, showed that the diffuse air density in the portal venous system, the pneumoperitoneum, and the pneumoretroperitoneum had resolved, and the colonoscopy and the colonography protocol CT scan revealed no significant

abnormalities (Figure 4). The patient has been on follow-up observation at an outpatient clinic for four years, and has experienced no recurrence of symptoms.

Discussion

This is a rare case of HPVG accompanied by free air without any detected etiology in a young male patient.

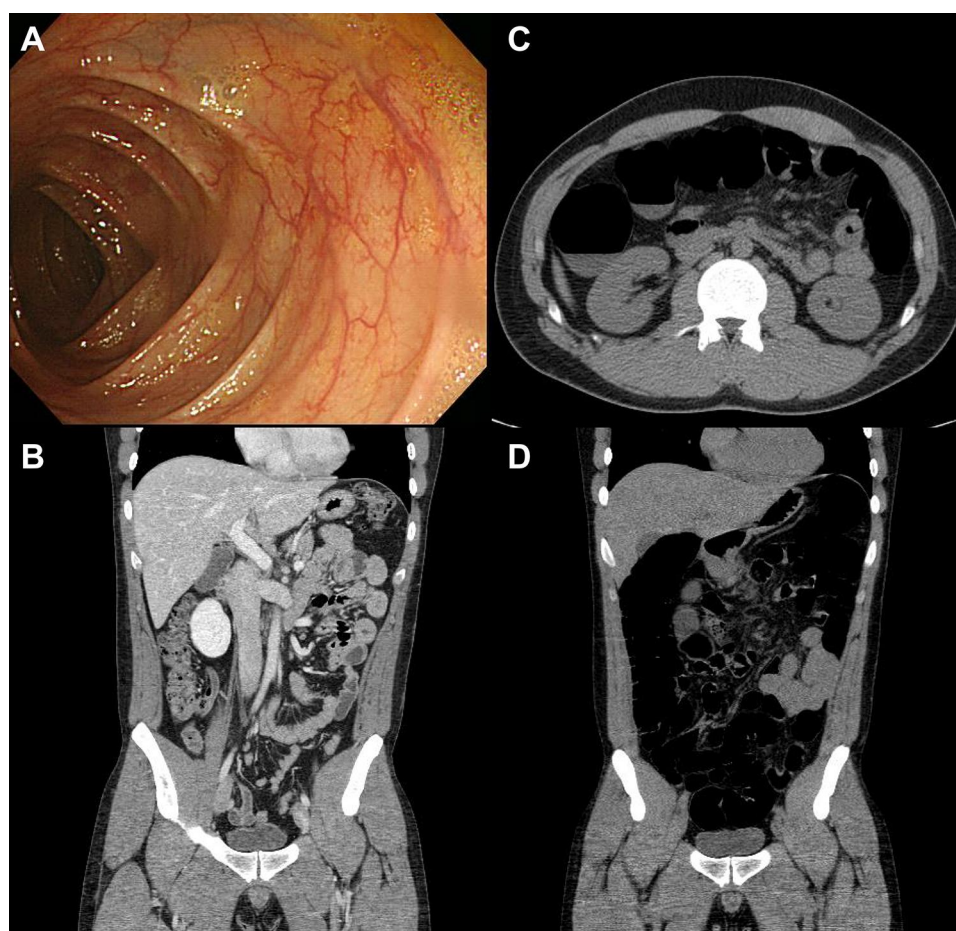


Figure 4 Colonoscopy (A), follow-up computed tomography (CT) scan (B), and colonography protocol CT scan (C and D), performed two weeks after discharge, showed no significant abnormalities.

The CT scan did not reveal any possible underlying pathology related to HPVG, and there was no history of abdominal blunt trauma, endoscopic procedures, or acute infectious diseases that could have caused HPVG. Regardless of the cause, given the stable vital signs, and the lack of physical signs of surgical acute abdomen, the patient was managed conservatively, and improved without any sequelae.

HPVG is defined as peripheral gas radiolucency that spreads to within 2 cm of the liver parenchyma, in addition to gas in the root of the portal vein.⁸ HPVG was first described in six neonates who demised due to necrotic bowels in 1955,¹ followed by similar reports of five adult patients,^{9,10} and the first survivor of HPVG was reported in 1965.¹¹ In the 1970s, the mortality rate of patients with HPVG was reported as approximately 75%;¹² however, due to radiological advancements, the diagnosis of HPVG related to benign conditions is increasing.¹³ Recently, the overall mortality rate of HPVG has dropped to approximately 39%,

but the mortality of HPVG resulting from lethal conditions, such as bowel necrosis, remains at 75%.³

Although various etiologies of HPVG, including bowel necrosis, intra-abdominal abscess, ulcerative colitis, bowel obstruction, peptic ulcer disease, endoscopic procedures, and gastric dilatation, have been identified, the exact mechanism needs to be clarified.^{3–5,13} The proposed mechanisms include disruption of the mucosal barrier, increased intraluminal pressure, and gas-producing organisms, all of which displace air from the bowel lumen to the venous system.¹³ In the current case, the CT scan and medical history revealed no potential etiology of the HPVG. The authors speculate that subserosal cysts of the bowel wall, or early pneumatosis intestinalis, may have resolved spontaneously after causing HPVG.

For several decades, HPVG was a dismal radiological diagnosis, but now represents a confounding factor in patient management. Nelson et al concluded that clinical or surgical treatment should not be determined by the detection of

HPVG by CT, but rather by the disease severity, and proposed an algorithm for HPVG management.¹³ They also recommended that patients with HPVG who present asymptotically should be treated conservatively.¹³ The current case represents nearly asymptomatic HPVG, and was successfully managed conservatively, despite the fact that HPVG was previously an indication for laparotomy.

Conclusion

In conclusion, the current case suggests that idiopathic HPVG may also appear in healthy patients only complaining of vague symptoms. As the prognosis is not determined by the existence of HPVG, but rather by the severity of the associated pathology, it is crucial to rule out fatal etiologies. Initial conservative management could be considered if HPVG is not due to life-threatening-pathology requiring immediate correction, and the patient is stable.

Abbreviations

CT, computed tomography; HPVG, hepatic portal venous gas.

Ethics Approval and Informed Consent

Based on the regulation of the department of research of the Kyung Hee University of Medical Science, institutional review board approval is not required for case reports. Written informed consent was obtained from the patient.

Consent for Publication

Written informed consent was obtained from the patient for publication of this case report and any accompanying images.

Author Contributions

All authors made substantial contributions to conception and design, acquisition of data, or analysis and interpretation of data; took part in drafting the article or revising it critically for important intellectual content; agreed to submit to the current journal; gave final approval of the version to be published; and agree to be accountable for

all aspects of the work. All authors issued final approval for the version to be submitted.

Funding

The authors declare that this case has received no financial support.

Disclosure

The authors have no conflicts of interest to declare for this work.

References

1. Wolfe JN, Evans WA. Gas in the portal veins of the liver in infants; a roentgenographic demonstration with postmortem anatomical correlation. *Am J Roentgenol Radium Ther Nucl Med.* 1955;74:468–486.
2. Sebastià C, Quiroga S, Espin E, et al. Portomesenteric vein gas: pathologic mechanisms, CT findings, and prognosis. *Radiographics.* 2000;20(5):1213–1224; discussion 1224–1226. doi:10.1148/radiographics.20.5.g00se011213
3. Kinoshita H, Shinozaki M, Tanimura H, et al. Clinical features and management of hepatic portal venous gas: four case reports and cumulative review of the literature. *Arch Surg.* 2001;136:1410–1444. doi:10.1001/archsurg.136.12.1410
4. Hussain A, Mahmood H, El-Hasani S. Portal vein gas in emergency surgery. *World J Emerg Surg.* 2008;3(1):21. doi:10.1186/1749-7922-3-21
5. Alqahtani S, Coffin CS, Burak K, et al. Hepatic portal venous gas: a report of two cases and a review of the epidemiology, pathogenesis, diagnosis and approach to management. *Can J Gastroenterol.* 2007;21:309–313.
6. Hong JJ, Gadaleta D, Rossi P, et al. Portal vein gas, a changing clinical entity. Report of 7 patients and review of the literature. *Arch Surg.* 1997;132:1071–1075.
7. Peloponissios N, Halkic N, Pugnale M, et al. Hepatic portal gas in adults: review of the literature and presentation of a consecutive series of 11 cases. *Arch Surg.* 2003;138:1367–1370.
8. Abboud B, El Hachem J, Yazbeck T, et al. Hepatic portal venous gas: physiopathology, etiology, prognosis and treatment. *World J Gastroenterol.* 2009;15(29):3585–3590. doi:10.3748/wjg.15.3585
9. Susman N, Senturia HR. Gas embolization of the portal venous system. *Am J Roentgenol Radium Ther Nucl Med.* 1960;83:847–850.
10. Wiot J, Felson B. Gas in the portal venous system. *Am J Roentgenol Radium Ther Nucl Med.* 1961;86:920.
11. Lazar HP. Survival following portal venous air embolization. *Am J Dig Dis.* 1965;10(3):259–264. doi:10.1007/BF02233756
12. Lieberman PR, Patten MT, Manny J, et al. Hepatic–portal venous gas in adults: etiology, pathophysiology and clinical significance. *Ann Surg.* 1978;187:281–287. doi:10.1097/0000658-197803000-00012
13. Nelson AL, Millington TM, Sahani D, et al. Hepatic portal venous gas: the ABCs of management. *Arch Surg.* 2009;144:575–581. doi:10.1001/archsurg.2009.88

International Journal of General Medicine**Dovepress****Publish your work in this journal**

The International Journal of General Medicine is an international, peer-reviewed open-access journal that focuses on general and internal medicine, pathogenesis, epidemiology, diagnosis, monitoring and treatment protocols. The journal is characterized by the rapid reporting of reviews, original research and clinical studies

across all disease areas. The manuscript management system is completely online and includes a very quick and fair peer-review system, which is all easy to use. Visit <http://www.dovepress.com/testimonials.php> to read real quotes from published authors.

Submit your manuscript here: <https://www.dovepress.com/international-journal-of-general-medicine-journal>