

Hyperbaric oxygen therapy to improve cognitive dysfunction and encephalatrophy induced by N₂O for recreational use: a case report

Dan Luo*

Jiajun Xu*

Li Hu

Liangming Yu

Leling Xie

Jing Li

Department of Psychiatry, Mental Health Center, West China Hospital of Sichuan University, Chengdu, Sichuan, People's Republic of China

*These authors contributed equally to this work

Abstract: N₂O, or laughing gas, is generally used for anesthesia, especially in stomatology and pediatrics but is also commonly used recreationally. Cognitive dysfunction induced by the recreational use of N₂O is rare. Here, we present the case of an 18-year-old female with a history of having used N₂O recreationally for 5 months who suffered from encephalatrophy and severe cognitive dysfunction. All of the symptoms gradually subsided with ~20 days of treatment by hyperbaric oxygenation. We hypothesize that the long-term use of N₂O may have induced a chronic state of systemic hypoxia that further induced cerebral atrophy with impaired cognitive function. Hyperbaric oxygen therapy (HBOT) is reported here for the first time as an important therapeutic element for treating N₂O toxicity due to recreational use.

Keywords: N₂O, recreational use, cognitive dysfunction, encephalatrophy, hyperbaric oxygen therapy

Introduction

Nitrous oxide (N₂O) is a colorless, nonflammable, inorganic volatile gas with psychedelic effects that is commonly referred to as laughing gas.¹ It is widely used for anesthesia and as an analgesic; it is also commonly used recreationally. The effects of N₂O were first reported in 1799 as consisting of a brief but vivid intoxication, accompanied by a powerful euphoria that may distort sensation, as well as temporal and spatial perceptions.² During the 19th century, N₂O was a popular recreational drug used in theater halls to relieve pain during performances. The recreational use of N₂O re-emerged during the 1960s, and it is now widely used and available via a variety of different manners of administration, including inhalation via canisters, balloons, respirators, and airtight bags.² The side effects of N₂O include transient dizziness, dissociation, disorientation, loss of balance, impaired memory and cognition, and weakness in the legs.³ It was previously reported that N₂O might induce cognitive impairment when used as an anesthetic.^{4,5} We present a case report in which a patient presented with encephalatrophy with cognitive dysfunction caused by the recreational use of N₂O. Encephalatrophy with impaired cognitive function caused by N₂O recreational use has not been reported previously. This case report is the first to report encephalatrophy accompanied by altered cognitive functioning apart from peripheral neuropathy following intense N₂O abuse. The benefits of hyperbaric oxygen therapy (HBOT) are extensive, and chief among them is the capacity to improve cognitive functioning with delayed encephalopathy after acute carbon monoxide poisoning.⁶

Correspondence: Jing Li
Mental Health Center, West China Hospital of Sichuan University, Dianxin Nan Jie 28#, Wuhou District, Chengdu, Sichuan 610041, People's Republic of China
Tel +86 189 8060 1715
Email joana028@163.com

Additionally, we tried to use HBOT to relieve the symptoms N_2O toxicity caused by recreational use.

Case report

An 18-year-old female who studied abroad in Australia and recently returned presented at our inpatient department with numbness and weakness in all four limbs, disturbance of orientation, and memory impairment for 5 days. She also presented with abnormal sensation in the lower limbs, difficulty walking, trouble speaking, and irritation. She was found lying on the ground in her house in Sydney and was unable to identify her brother. They also found thousands of steel bulbs³ (each of which contained 10 mL of pressurized N_2O) in the house. She admitted that she had used N_2O bulbs recreationally for >5 months. She used at least 50 bulbs during the past 5 months, one bulb every other day. During the last 4 days, she used more frequently than before, but she could not remember the exact number of bulbs she used.

Vital signs (temperature [T] 36.6°C, pulse [P] 80/min, respiratory rate [R] 20/min, and blood pressure [BP] 112/62 mmHg) were normal, and the physical examination was notable for a weakly positive Babinski sign, enhanced sensation in all four limbs, and ataxia. The upper limbs exhibited stage 4 muscle strength, while the lower limbs exhibited stage 3 muscle strength. The patient's past history of medical and psychiatric diseases were unremarkable, and there was no family history of psychiatric disorders. A full blood examination showed hemoglobin (Hb) 112 g/L, platelet count $174 \times 10^9/L$, white cell count $7.95 \times 10^9/L$, and mean corpuscular volume (MCV) 93.2 fL. Vitamin B_{12} was <1,500 pmol/L. The results of a urine toxicology screen were all negative, including methylamphetamine, heroin, morphine, ketamine, and methylenedioxymethylamphetamine. Blood gas (arterial blood) analysis showed partial pressure of oxygen in the alveolar (PAO_2) 97.5 mmHg, partial pressure of oxygen in the artery (PaO_2) 80.0 mmHg, PCO_2 37.0 mmHg, pH 7.48, and base excess (BE) 3.4 mmol/L. Liver function, renal function, and electrolyte tests showed total bilirubin (TBIL) 4.2 $\mu\text{mol/L}$, direct bilirubin (DBIL) 2.4 $\mu\text{mol/L}$, indirect bilirubin (IBIL) 1.8 $\mu\text{mol/L}$, alanine aminotransferase (ALT) 21 IU/L, aspartate aminotransferase (AST) 20 IU/L, AST/ALT 0.95, total protein (TP) 66.0 g/L, albumin (ALB) 41.8 g/L, glucose (GLU) 4.96 mmol/L, alkaline phosphatase (ALP) 40 IU/L, lactate dehydrogenase (LDH) 380 IU/L, amylase (AMY) 83 IU/L, lipase (LIP) 36 IU/L, creatinine (CREA) 46.0 $\mu\text{mol/L}$, sodium (Na) 142.7 mmol/L, potassium (K)

4.43 mmol/L, and chlorine (Cl) 104.0 mmol/L. Due to concerns regarding a potential spinal cord compromise and cerebral disease, an enhanced spinal and cerebral magnetic resonance imaging (MRI) was implemented. Figure 1A shows gyrus atrophy and broadened anfractuosity compared to the normal state on a T1-weighted image. Table 1 (before the treatment) shows the results of motor nerve conduction velocity (MCV). The motor conduction amplitude of bilateral tibial nerves, peroneal nerves, median nerves, and ulnar nerves decreased, and motor conduction velocity of bilateral median nerves and ulnar nerves similarly slowed down. Table 2 (before the treatment) shows the result of sensory nerve conduction velocity (SCV). Sensory conduction amplitude of bilateral peroneal nerves decreased, and sensory conduction velocity of bilateral median nerves, ulnar nerves, and peroneal nerves slowed down. Bilateral anterior tibial muscles showed a large amount of spontaneous potential (positive sharp wave and fibrillation wave), and the right abductor hallucis brevis showed multiple spontaneous potential (positive sharp wave and fibrillation wave), small contraction, and huge motor unit action potentials (MUAPs) in a quiet state. The patient was unable to complete the Montreal Cognitive Assessment (MoCA) and the Mini-Mental State Examination (MMSE) due to the poor medical condition.

The patient did not use N_2O recreationally again, and we prescribed vitamin B_{12} to improve neurological symptoms and an atypical antipsychotic drug, quetiapine, to help control irritation. The patient also received HBOT with a treatment pressure of 2 atm in an air-pressurized chamber and was given 100% oxygen for a period of 90–120 minutes at a time, a procedure that was repeated three times a session for 20 sessions. The dysfunction in sensory ataxia,

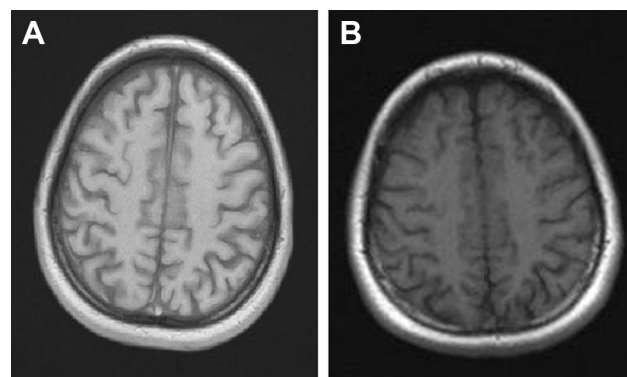


Figure 1 (A) Before the HBOT and (B) after the HBOT.
Abbreviation: HBOT, hyperbaric oxygen therapy.

Table 1 Motor nerve conduction in a patient with a history of N₂O abuse

Motor nerves	Lat SD (ms)		Amp SD (mV)		CV SD (m/s)		Amp% SD		F SD (ms)	
	Before	After	Before	After	Before	After	Before	After	Before	After
Right medianus	–	–	–	–	–	–	–	–	22.5	27.5
Wrist–APB	3.7	3.7	8.0	4.7	–	–	–	–	–	–
Bel Elb–wrist	8.6	8.4	7.5	3.1	43.9	50.0	–6	–33	–	–
Left medianus	–	–	–	–	–	–	–	–	22.5	29.0
Wrist–APB	4.1	3.6	4.0	3.0	–	–	–	–	–	–
Bel Elb–wrist	9.2	7.3	2.3	2.2	43.1	51.4	–43	–28	–	–
Right ulnaris	–	–	–	–	–	–	–	–	27.3	28.7
Wrist–ADM	2.4	2.4	8.2	8.3	–	–	–	–	–	–
Bel Elb–wrist	7.9	7.2	7.6	7.8	43.6	51.0	–7	–6	–	–
Left ulnaris	–	–	–	–	–	–	–	–	27.7	26.3
Wrist–ADM	2.2	2.6	8.2	6.6	–	–	–	–	–	–
Bel Elb–wrist	8.2	7.5	7.2	5.9	42.5	52.0	–13	–10	–	–
Right tibialis	–	–	–	–	–	–	–	–	–	–
Ankle–AHB	2.8	2.8	0.1	0.1	–	–	–	–	–	–
Left tibialis	–	–	–	–	–	–	–	–	–	–
Ankle–AHB	–	–	–	–	–	–	–	–	–	–
Right peroneus	–	–	–	–	–	–	–	–	–	–
Ankle–EDB	–	–	–	–	–	–	–	–	–	–
Left peroneus	–	–	–	–	–	–	–	–	–	–
Ankle–EDB	–	–	–	–	–	–	–	–	–	–

Notes: Before indicates that the patient was not treated. After indicates that the patient was treated.

Abbreviations: ADM, abductor digiti minimi; AHB, abductor hallucis brevis; Amp, amplitude; APB, abductor pollicis brevis; Bel Elb, below elbow; CV, conduction velocity; EDB, extensor digitorum brevis; F, F-wave; Lat, latency.

numbness, and impaired cognitive functioning gradually improved with treatment by hyperbaric oxygenation. The MoCA and MMSE scores after treatment were in the normal range. A subsequent MRI to re-examine the cranium showed (Figure 1B) improvement in the encephalopathy compared with the previous MRI. The results of motor (Table 1, after the treatment) and sensory (Table 2, after the treatment) NCV showed peripheral nerve impairment improved, as indicated by increased NCV values.

Ethics statement

Written informed consent for the publication of her clinical details and clinical images was obtained from the patient. A copy of the consent form is available for review from the editor of this journal.

Discussion

The patient met the diagnostic criteria for N₂O abuse-induced encephalopathy and cognitive impairment due to the history

Table 2 Sensory nerve conduction in a patient with a history of N₂O abuse

Sensory nerves	Lat SD (ms)		Amp SD (mV)		CV SD (m/s)		Amp% SD	
	Before	After	Before	After	Before	After	Before	After
Right medianus	2.7	1.98	24	38	42.6	53.0	–	–
Dig III–wrist	4.9	0.7	–	–	–	–	–	–
Left medianus	2.6	1.81	28	33	42.3	55.2	–	–
Dig III–wrist	4.3	–0.2	–	–	–	–	–	–
Right unarius	2.0	1.62	13	17	45	55.6	–	–
Dig V–wrist	0.9	–1.3	–	–	–	–	–	–
Left unarius	1.79	1.58	15	21	50.3	53.8	–	–
Dig V–wrist	–0.3	–1.5	–	–	–	–	–	–
Right suralis	1.92	1.69	7.1	14	46.9	53.3	–	–
Ankle–foreleg	–	–	–	–	–	–	–	–
Left suralis	1.88	1.73	5.3	13	47.9	54.9	–	–
Ankle–foreleg	–	–	–	–	–	–	–	–

Notes: Before indicates that the patient was not treated. After indicates that the patient was treated.

Abbreviations: Amp, amplitude; CV, conduction velocity; Lat, latency; Dig, digit.

of N₂O abuse and MRI-determined encephalatrophy accompanied by impaired cognitive functioning and peripheral nerve conduction abnormalities. The patient recovered fully as a result of HBOT.

There were several reported cases of the recreational use of N₂O resulting in myelopathy and polyneuropathy.^{7–10} The neurological symptoms of these patients were commonly associated with the deficiency of vitamin B₁₂.¹¹ In this case, the reason why the level of vitamin B₁₂ was high was that the patient received vitamin B₁₂ treatment after she was found and sent to the Emergency Department of the local hospital in Sydney. However, there were no cases in which cognitive impairment was induced by N₂O and the mechanism by which N₂O induces encephalatrophy is not yet completely understood. As an anesthetic, N₂O can affect cognitive functioning after surgery by influencing brain activity¹² and the depth of the anesthesia is also related to cognitive functioning.¹³ The dose of N₂O that the patient used recreationally is much greater than that used in anesthesia, so it is not too difficult to understand why the patient exhibited cognitive dysfunction. However, we cannot determine if the cognitive dysfunction induced by the N₂O was acute or chronic. One study demonstrated that the most important safety consideration in the use of N₂O as an anesthetic is the prevention of hypoxia.¹⁴ A related study suggested that hypoxia may damage brain cells,¹⁵ and other studies also found that N₂O increases brain injury after ischemia or hypoxia in surgery.^{16–20} In this case, the cerebral atrophy induced by N₂O may be the result of chronic hypoxia because of the long-term recreational use of N₂O and the associated cognitive impairment.

Hyperbaric oxygen (HBO) provides 100% oxygen under high pressure, which significantly increases oxygen delivery to the mitochondria at the cellular level, reduces intracranial pressure, and has both anti-inflammatory and neuroplasticity effects in different types of brain injuries. According to the Henry law, maximizing tissue oxygenation, HBO increases the amount of oxygen carried in solutions and tissue by raising the external pressure, which is sufficient to support resting tissues without a contribution from the Hb, and induces rapid and significant vasoconstriction.^{21,22} Generation of oxygen-derived free radicals increased as a result of HBO, destroying DNA and inhibiting bacterial metabolic functions.²¹ HBOT not only accelerates collateral circulation to protect neurons from ischemic death but also repairs the damaged microvessels, thereby stimulating angiogenesis and neurogenesis.^{22,23} Additionally, HBOT can effectively counter ischemia and hypoxia, so all instances of hypoxia, ischemic diseases, or

a series of diseases caused by hypoxia and ischemia can be resolved successfully. There were a number of reports about the use of HBOT to treat hypoxia and ischemic diseases as a result of all kinds of causes, such as brain injury, cerebral palsy, stroke, and others,^{24,25} especially to improve cognitive dysfunction after brain injury.²⁶ In particular, HBOT can ameliorate cognitive functioning in someone suffering from anoxic brain damage.²⁷ In this case, we speculate that the high dosage of N₂O induced hypoxia and hypoxia induced cerebral atrophy and cognitive impairment. We tried to use HBOT to relieve the patient's cerebral atrophy and cognitive impairment, which we did successfully. After the HBOT treatment, the patient's cerebral atrophy and cognitive impairment improved, a strong confirmation of our initial hypothesis regarding pathophysiology.

There are important points to consider regarding this case report; for example, we could not conclusively determine whether the patient's cognitive impairment and cerebral atrophy caused by the N₂O was acute or chronic. Additionally, although we affirmed the effectiveness of HBOT for cognitive dysfunction caused by N₂O, there were no previous reports of the use of HBOT to treat cognitive impairment and brain atrophy caused by N₂O. As such, the use of HBOT as the standard therapy for ailments associated with laughing gas abuse still warrants further research.

Conclusion

This case report is the first to present encephalatrophy with severe cognitive impairment as a side effect of recreational abuse of N₂O. Symptoms such as numbness and weakness in all four limbs, disturbance of orientation, memory impairment, abnormal sensation in the lower limbs, and difficulty walking and speaking were relieved by the HBOT treatment, providing an important clue regarding the mechanism behind N₂O-induced encephalatrophy and the role of HBOT as a new treatment for this pathophysiology.

Disclosure

The authors report no conflicts of interest in this work.

References

1. Wong SL, Harrison R, Mattman A, Hsiung GY. Nitrous oxide (N₂O)-induced acute psychosis. *Can J Neurol Sci*. 2014;41(5):672–674.
2. Mike J. Nitrous oxide: recreational use, regulation and harm reduction. *Drugs Alcohol Today*. 2008;8(3):22–25.
3. van Amsterdam J, Nabben T, van den Brink W. Recreational nitrous oxide use: prevalence and risks. *Regul Toxicol Pharmacol*. 2015;73(3):790–796.
4. Zou YQ, Li XB, Yang ZX, et al. Impact of inhalational anesthetics on postoperative cognitive function: study protocol of a systematic review and meta-analysis. *Medicine (Baltimore)*. 2018;97(1):e9316.

5. Samur Ergüven S, Delilbaşı EA, Işık B, Öktem F. The effects of conscious sedation with nitrous oxide/oxygen on cognitive functions. *Turk J Med Sci*. 2016;46(4):997–1003.
6. Xiang W, Xue H, Wang B, et al. Efficacy of N-butylphthalide and hyperbaric oxygen therapy on cognitive dysfunction in patients with delayed encephalopathy after acute carbon monoxide poisoning. *Med Sci Monit*. 2017;23:1501–1506.
7. Stockton L, Simonsen C, Seago S. Nitrous oxide-induced vitamin B12 deficiency. *Proc (Bayl Univ Med Cent)*. 2017;30(2):171–172.
8. Richardson PG. Peripheral neuropathy following nitrous oxide abuse. *Emerg Med Australas*. 2010;22(1):88–90.
9. Hsu CK, Chen YQ, Lung VZ, His SC, Lo HC, Shyu HY. Myelopathy and polyneuropathy caused by nitrous oxide toxicity: a case report. *Am J Emerg Med*. 2012;30(6):e3–e6.
10. Rheinboldt M, Harper D, Parrish D, Francis K, Blase J. Nitrous oxide induced myeloneuropathy: a case report. *Emerg Radiol*. 2014;21(1):85–88.
11. Hathout L, El-Saden S. Nitrous oxide-induced B12 deficiency myelopathy: perspectives on the clinical biochemistry of vitamin B12. *J Neurol Sci*. 2011;301(1–2):1–8.
12. Mandal PK, Schifilliti D, Mafra F, Fodale V. Inhaled anesthesia and cognitive performance. *Drugs Today (Barc)*. 2009;45(1):47–54.
13. Farag E, Chelune GJ, Schubert A, Mascha EJ. Is depth of anesthesia, as assessed by the Bispectral Index, related to postoperative cognitive dysfunction and recovery? *Anesth Analg*. 2006;103(3):633–640.
14. Donaldson M, Donaldson D, Quarnstrom FC. Nitrous oxide-oxygen administration: when safety features no longer are safe. *J Am Dent Assoc*. 2012;143(2):134–143.
15. Geddes R, Vannucci RC, Vannucci SJ. Delayed cerebral atrophy following moderate hypoxia-ischemia in the immature rat. *Dev Neurosci*. 2001;23(3):180–185.
16. Baughman VL, Hoffman WE, Thomas C, Albrecht RF, Miletich DJ. The interaction of nitrous oxide and isoflurane with incomplete cerebral ischemia in the rat. *Anesthesiology*. 1989;70(5):767–774.
17. Matta BF, Lam AM. Nitrous oxide increases cerebral blood flow velocity during pharmacologically induced EEG silence in humans. *J Neurosurg Anesthesiol*. 1995;7(2):89–93.
18. Baughman VL, Hoffman WE, Miletich DJ, Albrecht RF, Thomas C. Neurologic outcome in rats following incomplete cerebral ischemia during halothane, isoflurane, or N2O. *Anesthesiology*. 1988;69(2):192–198.
19. Sakabe T, Kuramoto T, Inoue S, Takeshita H. Cerebral effects of nitrous oxide in the dog. *Anesthesiology*. 1978;48(3):195–200.
20. Pelligrino DA, Miletich DJ, Hoffman WE, Albrecht RF. Nitrous oxide markedly increases cerebral cortical metabolic rate and blood flow in the goat. *Anesthesiology*. 1984;60(5):405–412.
21. Gill AL, Bell CN. Hyperbaric oxygen: its uses, mechanisms of action and outcomes. *QJM*. 2004;97(7):385–395.
22. Sánchez EC. Mechanisms of action of hyperbaric oxygenation in stroke: a review. *Crit Care Nurs Q*. 2013;36(3):290–298.
23. Wang Y, Chen D, Chen G. Hyperbaric oxygen therapy applied research in traumatic brain injury: from mechanisms to clinical investigation. *Med Gas Res*. 2014;4:18.
24. McDonagh M, Carson S, Ash J, et al. Hyperbaric oxygen therapy for brain injury, cerebral palsy, and stroke. *Evid Rep Technol Assess (Summ)*. 2003;(85):1–6.
25. Michalski D, Härtig W, Schneider D, Hobohm C. Use of normobaric and hyperbaric oxygen in acute focal cerebral ischemia – a preclinical and clinical review. *Acta Neurol Scand*. 2011;123(2):85–97.
26. Liu S, Shen G, Deng S, Wang X, Wu Q, Guo A. Hyperbaric oxygen therapy improves cognitive functioning after brain injury. *Neural Regen Res*. 2013;8(35):3334–3343.
27. Hadanny A, Golan H, Fishlev G, et al. Hyperbaric oxygen can induce neuroplasticity and improve cognitive functions of patients suffering from anoxic brain damage. *Restor Neurol Neurosci*. 2015;33(4):471–486.

Neuropsychiatric Disease and Treatment

Publish your work in this journal

Neuropsychiatric Disease and Treatment is an international, peer-reviewed journal of clinical therapeutics and pharmacology focusing on concise rapid reporting of clinical or pre-clinical studies on a range of neuropsychiatric and neurological disorders. This journal is indexed on PubMed Central, the 'PsycINFO' database and CAS,

Submit your manuscript here: <http://www.dovepress.com/neuropsychiatric-disease-and-treatment-journal>

Dovepress

and is the official journal of The International Neuropsychiatric Association (INA). The manuscript management system is completely online and includes a very quick and fair peer-review system, which is all easy to use. Visit <http://www.dovepress.com/testimonials.php> to read real quotes from published authors.