

First-episode psychosis as the initial presentation of multiple sclerosis: a case report

Athena Enderami¹

Rose Fouladi²

Seyed Hamzeh Hosseini³

¹Department of Psychiatry, School of Medicine, Mazandaran University of Medical Sciences, Mazandaran, Sari, Iran; ²Sport Injuries and Corrective Exercise, University of Mazandaran, Mazandaran, Babolsar, Iran; ³Psychiatry and Behavioral Sciences Research Center, Addiction Institute, Mazandaran University of Medical Sciences, Sari, Iran

Background: Multiple sclerosis (MS) is an inflammatory disease that affects the central nervous system (CNS). MS with episode of psychosis is a rare entity, and to the best of our knowledge, no case has been reported from Iran till date.

Case presentation: We report a case of MS with first-episode psychosis in a 27-year-old single man with no history of psychiatric disorder or drug abuse. The patient developed neurological symptoms after 3 months and was finally diagnosed as a case of MS. His symptoms started with behavioral dysfunctions and progressively resulted in depression. Subsequently, treatment was performed with citalopram 20 mg daily, risperidone 2 mg three times a day, and biperiden 2 mg three times a day; however, no improvements in the symptoms were observed. T2-weighted magnetic resonance imaging has demonstrated periventricular and white matter multiple sclerotic plugs with lesions. Eventually, MS was diagnosed after the appearance of paresthesia, upper and lower limb muscle weakness, ataxia, and urinary incontinency as typical signs. Then, the medications were changed to methylprednisolone and interferon therapy, which resulted in improvements in the clinical conditions of the patient.

Conclusion: Based on the fact that organic disorders such as MS may sometimes appear with initial pure psychiatric symptoms without any neurological signs and symptoms, examinations for symptoms linked to CNS dysfunction, cognitive changes, atypical symptoms, detailed neurological examination, and limited response to conventional antipsychotic drugs are highly recommended to be carried out for patients with first-episode psychosis and even in the follow-up period.

Keywords: multiple sclerosis, MS, episode, psychotic disorders, case report, signs, symptoms

Introduction

Multiple sclerosis (MS) is a chronic inflammatory disease in the central nervous system (CNS) with a progressive demyelination of nerve cells and damage in sensory-motor pathway that cause specific neurological and psychological symptoms.¹ There are 2.5 million patients suffering from MS all over the world, and it has been the most common neurological disorder in young adults and middle-aged people.¹ According to the clinical and paraclinical findings, MS symptoms including muscle weakness, visual disorder, sensory and motor discoordination, depression, vertigo, functional cognition, and sexual disorder are different based on the location and severity of CNS involvement.² Cross-sectional studies have demonstrated that ~2/3 of patients have had detectable psychopathological conditions; however, only few did receive psychiatric treatment. Some of the disorders have been reported as the results of illnesses, while some were

Correspondence: Seyed Hamzeh Hosseini
Psychiatry and Behavioral Sciences Research Center, Imam Khomeini Hospital, Amir Mazandarani Street, Sari, Mazandaran, Iran
Tel/Fax +98 113 335 0672
Email Hosseinish20@gmail.com

side effects of the medication.² Among psychiatric illnesses, mood disorders, especially depression and cognitive disorder, are more common (at the rate of 2%–3%).² The presence of pure psychotic disorders such as anxiety, panic disorder, paranoid thoughts, aggressive and antisocial behavior, and also depression before neurological symptoms has been rarely reported as a feature of MS; thus, misdiagnosis may occur under this circumstance.²

Importantly, several studies have described a significant increase in plasma levels of interleukin-6 and C-reactive protein as inflammatory biomarkers in patients with psychotic disorders.³ Increased activation of inflammatory signaling pathways (such as NF- κ B pathways) and altered anti-inflammatory activity are common factors in the pathophysiology of MS⁴ and psychotic disorders.⁵ Therefore, psychotic disorders can be a distinct clinical disorder or can be an initial presentation of MS. Furthermore, other neurological conditions including encephalitis and encephalomyelitis should be considered, as each could be responsible for psychotic disorders.⁶

Psychosis has been basically reported to occur in periventricular involvement – especially in temporal region – usually after the neurological features while it is reported less frequently as a primary phase as in this study.⁷ The current paper studies a case of a 27-year-old man in whom acute psychosis was the initial presenting feature of MS. The patient developed neurological symptoms after 3 months and was finally diagnosed as a case of MS.

Case presentation

In this study, we report a 27-year-old single man with no history of psychiatric disorder or drug abuse. His illness initiated with some pure psychiatric symptoms; for 3 years, the case

had a fear with the feeling of being followed by others, without any external stressor. His symptoms were then exacerbated to hesitation and muttering, irritability, anger outbursts, bad tempering, and antisocial behavior. He thought his colleagues at work are likely to harm him due to his good skills at his job. His symptoms gradually tended toward depression, severe fatigue and loss of energy, loss of appetite, and weight loss and were followed by joint stiffness and loss of movement control at upper and lower limbs. After 6 months from the appearance of symptoms, he was brought to a psychiatric office being uncertain of hallucinogenic drug abuse. The psychiatrist prescribed citalopram 20 mg daily, risperidone 2 mg three times a day, and biperiden 2 mg three times a day; however, no improvements in the symptoms were observed.

Although there was no history of psychiatric disorders and drug abuse, due to some motor neuron involvement, the patient was referred to carry out a brain imaging (magnetic resonance imaging [MRI] without contrast) to rule out organic disorders in a month. He was referred to psychiatrist after 6 months from the appearance of symptoms. The psychiatrist also asked the patient to carry out brain MRI following the medical treatment. The T2-weighted MRI demonstrated periventricular and white matter multiple sclerotic plugs with lesions (Figure 1A and B). Because of the presence of paresthesia, upper and lower limb muscle weakness, ataxia, and urinary incontinency, he was referred to a neurologist. MS diagnosis was made based on the patient's signs, symptoms, and imaging findings. He took methylprednisolone (5 mg three times a day/until remission) and interferon therapy, which resulted in improvements in sensory and motor neuron involvement and socio-occupational behavior and disappearance of hallucination in 40 days (by the time the treatment began).

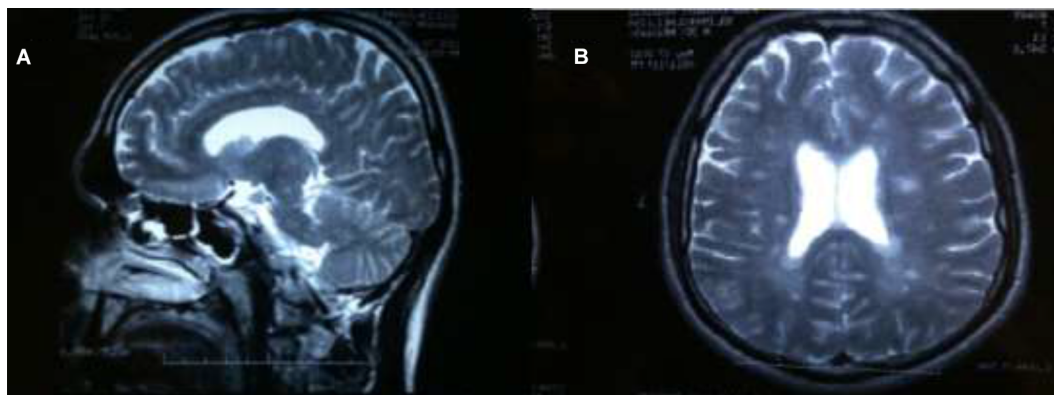


Figure 1 Brain magnetic resonance imaging (MRI) of the patient.

Notes: (A) T2-weighted sagittal images of periventricular plugs and (B) T2-weighted axial images of periventricular deep white matter plugs. T2-weighted MRI images show periventricular and white matter multiple sclerotic plugs with lesions.

Written informed consent was given by the patient for the publication of this case report.

Discussion

Our patient was a young man with initial psychotic disorders, and unlike others, he did not show any neurological signs and symptoms first. Therefore, there was a delay in diagnosis and management,⁷ since the appearance of neurological symptoms usually occurs prior to the psychotic ones.⁸ Moreover, there was some delay between the psychiatric symptoms and the neuroradiological examinations that could question concerning the relationship between the initial symptoms and the brain inflammation.

Psychotic disorders are usually followed by neurological symptoms or side effects of medication. Psychotic disorders of MS are classified into two subgroups: mood disorder and cognitive-behavioral disorder.² In fact, because of the involvement of neural fibers in MS, not only may the function of sensory-motor system disrupt but also psychotic symptoms can change the appearance of illness and cause an error in the initial diagnosis.¹

Although some psychotic disorders such as depression, irritability, severe fatigue, and loss of energy started initially in this subject, they are generally considered as common symptoms in MS patients. In the previous studies, the rate of depression in MS was reported to be 22.8% (unlike 16.2% in healthy society),⁹ and the rate of fatigue was 75% (unlike 23.7%).¹⁰ Some psycho-social factors and progression of illness can influence the presence of depression and its related mood fluctuation – suicide tendency, functional disability, and wrong thinking pattern. Psychosis was the other psychiatric disorder demonstrated in this case, which is not common in MS.¹⁰ The reported rate of psychosis in MS patients has been 2%–3% (unlike 0.5%–1% in normal people).¹¹ Some major disorders have been reported in this group, which generally start and appear in psychotic disorders.¹

A study described three patients who had psychotic symptoms as the initial presentation of MS (20% of all reported patients). These patients were admitted and were diagnosed with MS within 1-year period. One of the patients first experienced psychotic symptoms as a severe depressive episode with psychotic features such as gait ataxia, dysarthria, and tremor. Somatic delusions were the chief complaints in the second reported case of that study. This case had a history of schizotypal, personality disorder, autistic spectrum disorder, and social phobia in this case. She was diagnosed with hebephrenic schizophrenia. Another patient was diagnosed after emerging inattention and memory deficits as cognitive

impairments. Clinical conditions for this patient were worsened and finally had been led to the development of visual and auditory hallucinations.¹²

In previous studies,^{1,9} there was no distinct relationship between brain abnormality in MRI and depression. Maybe the inability of an MRI to distinguish rooted in the etiological limitation in those studies and the immunological disorders in hypothalamic–hypophysis–adrenal pathway disorder that may increase the risk of depression in these patients.¹

Similar to previous studies, in this study, plugs with lesions were seen around the brain ventricles. In MS patients with psychosis, commonly, there are multiple plugs on temporal horn and temporal lobes, and their pathological problems are more in temporoparietal region.⁸ Patients' MRI scans in a clinical case series were 1) dissemination in space and along with the presence of CSF oligoclonal bands, 2) T2 hyperintensities bilaterally with some periventricular lesions but predominance within the deep and subcortical white matter, and 3) multiple MRI white matter hyperintensities of both cerebral hemispheres, predominantly in the periventricular and juxtacortical regions.¹² Furthermore, a systematic review on the MS cases with psychotic symptoms showed that 60% of patients had predominantly fronto-temporal lesions and also contrast-enhancing lesions.¹³

According to previous studies, although psychotic symptoms could be exacerbated by steroids,¹⁴ anti-psychotic low-dose medications such as risperidone and clozapine were suggested to relieve symptoms.¹ However, neither did risperidone change the illness symptoms nor could methyl prednisolone pulse medication manage the illness. Ultimately, interferon and methylprednisolone were able to alleviate the psychotic symptoms, make gradual improvement in social and behavioral relationship, and remove the hesitation as well. A recent systematic review stated that MS could be associated with a variety of psychotic signs and symptoms. Moreover, 28.6% of patients were successfully treated with corticosteroid therapies in the acute phase of their psychotic symptoms.¹³

More investigations such as lumbar puncture could be helpful to further illustrate CNS inflammation. In addition, T1-weighted images with gadolinium could be considered to have information about active brain inflammation. Spinal cord MRI could be performed to support the diagnosis of MS and assess the myelitis (paresthesia).

Based on the fact that organic disorders such as MS may sometimes appear with initial pure psychiatric symptoms without any neurological signs and symptoms, examinations for symptoms linked to CNS dysfunction, cognitive changes,

atypical symptoms, detailed neurological examination, and limited response to conventional anti-psychotic drugs are highly recommended to be carried out for patients with first-episode psychosis and even in the follow-up period.

Conclusion

Diagnosis of MS must not preclude the use of other clinical, imaging, and paraclinical supportive features in the diagnosis phase, although it may require to lapse for a period of time until a definite diagnosis is established. Further studies are required to find the exact prevalence of MS patients showing initial pure psychiatric symptoms and to study the factors associated with such a condition.

Disclosure

The authors report no conflicts of interest in this work.

References

1. Haussleiter IS, Brüne M, Juckel G. Review: psychopathology in multiple sclerosis: diagnosis, prevalence and treatment. *Ther Adv Neurol Disord*. 2009;2(1):13–29.
2. Patten SB, Svenson LW, Metz LM. Psychotic disorders in MS: population-based evidence of an association. *Neurology*. 2005;65(7):1123–1125.
3. Hashimoto K. Abnormalities in the brain-immune system in psychotic disorders: from pathogenesis to prevention. *Eur Arch Psychiatry Clin Neurosci*. 2017;267(5):365–367.
4. Leibowitz SM, Yan J. NF- κ B pathways in the pathogenesis of multiple sclerosis and the therapeutic implications. *Front Mol Neurosci*. 2016;9:84.
5. Altinöz M, Ince B, Tek C, Srihari V, Guloksuz S. The NF- κ B signaling pathway: an important therapeutic target in psychiatric disorders. *Mol Psychiatry*. 2018;23(3):490–491.
6. Butler C, Zeman A. Neurological syndromes which can be mistaken for psychiatric conditions. *J Neurol Neurosurg Psychiatry*. 2005;76(Suppl 1):i31–i38.
7. Aggarwal A, Sharma D, Kumar R, Sharma R. Acute psychosis as the initial presentation of MS: a case report. *Int MS J*. 2011;17(2):54–57.
8. Ghaffar O, Feinstein A. The neuropsychiatry of multiple sclerosis: a review of recent developments. *Curr Opin Psychiatry*. 2007;20(3):278–285.
9. Patten S, Beck C, Williams J, Barbui C, Metz L. Major depression in multiple sclerosis: a population-based perspective. *Neurology*. 2003;61(11):1524–1527.
10. Tellez N, Rio J, Tintore M, Nos C, Galan I, Montalban X. Fatigue in multiple sclerosis persists over time. *J Neurol*. 2006;253(11):1466–1470.
11. Lo Fermo S, Barone R, Patti F, et al. Outcome of psychiatric symptoms presenting at onset of multiple sclerosis: a retrospective study. *Mult Scler*. 2010;16(6):742–748.
12. Gilberthorpe TG, O'Connell KE, Carolan A, et al. The spectrum of psychosis in multiple sclerosis: a clinical case series. *Neuropsychiatr Dis Treat*. 2017;13:303.
13. Camara-Lemarroy CR, Ibarra-Yruegas BE, Rodriguez-Gutierrez R, Berrios-Morales I, Ionete C, Riskind P. The varieties of psychosis in multiple sclerosis: a systematic review of cases. *Mult Scler Relat Disord*. 2017;12:9–14.
14. West S, Kenedi C. Strategies to prevent the neuropsychiatric side-effects of corticosteroids: a case report and review of the literature. *Curr Opin Organ Transplant*. 2014;19(2):201–208.

International Medical Case Reports Journal

Publish your work in this journal

The International Medical Case Reports Journal is an international, peer-reviewed open-access journal publishing original case reports from all medical specialties. Previously unpublished medical posters are also accepted relating to any area of clinical or preclinical science. Submissions should not normally exceed 2,000 words or

4 published pages including figures, diagrams and references. The manuscript management system is completely online and includes a very quick and fair peer-review system, which is all easy to use. Visit <http://www.dovepress.com/testimonials.php> to read real quotes from published authors.

Submit your manuscript here: <https://www.dovepress.com/international-medical-case-reports-journal-journal>

Dovepress