

Preventive effect of *Oenothera rosea* on N-methyl-N-nitrosourea- (NMU) induced gastric cancer in rats

Yuan Almora-Pinedo¹
Jorge Arroyo-Acevedo²
Oscar Herrera-Calderon³
Víctor Chumpitaz-Cerrate⁴
Renán Hañari-Quispe⁵
Aldo Tinco-Jayo⁶
Cesar Franco-Quino⁴
Linder Figueroa-Salvador⁷

¹Department of Pharmacy, Hospital Nacional Hipólito Unanue, Lima,

²Laboratory of Experimental Pharmacology, Faculty of Medicine, Universidad Nacional Mayor de San Marcos, Lima, ³Faculty of Pharmacy and Biochemistry, Universidad Nacional San Luis Gonzaga de Ica, Ica, ⁴Laboratory of Physiology and Pharmacology, Faculty of Dentistry, Universidad Nacional Mayor de San Marcos, Lima, ⁵Laboratory of Animal Physiology, Universidad Andina Néstor Caceres Velasquez, Puno, ⁶Academic Department of Human Medicine, School of Pharmacy and Biochemistry, Universidad Nacional San Cristóbal de Huamanga, Ayacucho, ⁷School of Medicine, Faculty of Health Sciences, Universidad Peruana de Ciencias Aplicadas, Lima, Peru

Correspondence: Oscar Herrera-Calderon
Faculty of Pharmacy and Biochemistry,
Universidad Nacional San Luis Gonzaga de Ica, Av. Los Maestros S/N, Ica, Peru
Tel +51 95 6550510
Email oherrercalderon@gmail.com

Background: Currently, gastric cancer (GC) is considered a public health problem worldwide. Using medicinal plants for the prevention of chronic diseases such as cancer constitutes new alternatives in traditional medicine. *Oenothera rosea* (OR) could be an option, but it needs to be evaluated.

Aim: The main objective of this study was to evaluate the protective effect of OR extract on N-methyl-N-nitrosourea (NMU)-induced GC in rats.

Methods: In total, 80 male Holtzman rats were randomized into five groups. Group A received the saline solution (5mL/kg), group B received NMU 500 µg/kg (cancer inductor) by oral administration for 16 weeks, and groups C, D, and E were treated with OR extract (100, 200, and 300 mg/kg, respectively) and NMU in order to evaluate the preventive effect on cancer induced by NMU for 16 weeks. Blood and histological samples of stomachs were collected to determine histopathological, biochemical, and hematological parameters between different experimental groups.

Results: Groups C, D, and E presented less histopathological changes such as anaplastic and hyperplastic cells, compared with group B. Hematological and biochemical parameters were recorded, and superoxide dismutase, malondialdehyde, and nitric oxide levels were statistically less than those of NMU group ($P<0.05$, $P<0.01$, and $P<0.01$).

Conclusion: Considering the histopathological signs and the antioxidant activity in vivo as well as hematological and biochemical parameters of ethanolic extract of OR, we concluded that its administration in rats has a protective effect on GC, which is induced experimentally. This species could be studied in clinical trials for patients with GC in the future.

Keywords: carcinogenic, anticancer, gastroenterology, antioxidant, anaplasia

Introduction

Gastric cancer (GC) is the third leading cause of death worldwide. For example, Eastern Asian and Latin-American countries have a higher incidence of GC.¹ On the other hand, the annual incidence of GC in Peruvian population is ranked in the 20th position in the world, ~15.8 per 100,000 habitants, five times higher than that in the USA.^{2,3}

Surgical resection and chemotherapy are the only potentially curative treatments for GC. Currently, the major percentage of diagnosed cancer is determined in the final or advanced stage, representing 75% of all diagnosed cases. Furthermore, <5% of patients with advanced GC survive up to 5 years.⁴

Bioassays in animals play an important role in understanding GC pathophysiology. A high intake of salt, nitrates/nitrites, and nitrosamines is known as the main factor inducing GC.⁵ These synthetic N-nitroso compounds, such as N-methyl-N-nitrosourea

(NMU), have been used in experimental gastric carcinogenesis, inducing DNA mutations, and could modify the amino acids in histone proteins, leading to a chromatin remodeling.⁶

Many medicinal plants are used by the patients with cancer due to numerous positive effects of these plants on pain relief, vomiting, nausea, depression, and anxiety.⁷ The World Health Organization released a statement about the increased risk of GC with a large intake of salt-preserved foods. However, diets high in raw vegetables, fresh fruits, vitamin C, vitamin A, and antioxidants are associated with a decreased risk of GC.⁸ Polyphenols have antioxidant capacity with potential benefits for health and could reduce cancer risk, by blocking the initial stage of carcinogenesis, free radicals, activating glutathione peroxidase, and glutathione reductase and stopping the activation of glutathione S transferase.⁹

Oenothera rosea (OR; family: Onagraceae) is called “chupasangre,” and it is a species with therapeutic properties from Peruvian flora, especially from the high mountain. The infusion of this plant is used for its antibacterial and anticoagulant effects. Previous research has reported that OR presents flavonoids and steroids.¹⁰ The main objective of the present research was to determine the protective effect of OR on NMU-induced GC in Holtzman rats.

Materials and methods

Animals

A total of 80 male Holtzman rats (80±20 g) were obtained from the National Institute of Health (Lima, Peru). The rats were kept in plastic cages with access to pelletized food and water ad libitum and housed in an animal room at a controlled temperature (22–24°C) and 12-h light/dark cycle. The rats were randomized into five groups of 16 animals each and acclimatized 15 days prior to the experiments. All the experimental procedures involving animals were conducted in accordance with the guidelines established by the European Union on Animal Care (European Economic Community Council 86/609) and approved by the Institute for Ethics in Health of the Universidad Nacional Mayor de San Marcos (01414-R-12-UNMSM).

Chemicals

NMU, sodium nitroprusside, sulfanilic acid reagent, thiobarbituric acid, and trichloro acetic acid were purchased from Sigma-Aldrich (St Louis, MO, USA).

Plant material

OR was collected, in February 2016, from Valle del Mantaro, Huancayo, Peru. A voucher specimen (152-USM-2016) was deposited at the National Herbarium of UNMSM, Lima, Peru.

Extraction of plant material

The whole plant of OR (1000 g) was dried at room temperature and pulverized at the Pharmacology Laboratory, Faculty of Medicine, UNMSM; the powder material was exhaustively soaked with 96% ethanol and intermittently shaken every day for 7 days. The extract was filtered and evaporated by using a rotavap. The crude ethanolic extract obtained (50 g) was stored until further studies.

Phytochemical screening

The presence of phytochemical constituents, such as alkaloids, terpenoids, quinone, flavonoids, tannins, saponins, steroids, and phenolic compounds, was determined using the standard qualitative phytochemical methods described.¹¹

Protective effect on NMU-induced GC in rats

Tumor induction

In all groups, except negative control, tumor induction was carried out following the method of Tatematsu et al¹² with brief modifications. NMU was used as a carcinogenic agent for GC induction. Animals received a single dose of 500 µg/kg of NMU dissolved in saline solution (pH 5.0) by oral administration for 16 weeks.

Experimental design

The groups were placed according to the treatment and dose in mg/kg. OR refers to OR ethanolic extract. The negative control group received saline solution (10 mL/kg) orally. NMU group was induced with NMU 500 µg/kg orally for 16 weeks. NMU + OR-100, NMU + OR-200, and NMU + OR-300 groups received OR (100, 200, and 300 mg/kg, respectively) orally for 16 weeks with NMU inductor. Both solutions were administered by separate intervals to avoid interactions.

At the end of the experiment, the rats were weighed. Blood samples were collected to assess the biochemical parameters and hematological indicators. The animals were sacrificed by using pentobarbital anesthesia (100 mg/kg; intraperitoneally). The protective effect was determined evaluating weights, histopathological signs, and hematological and biochemical indicators, as well as superoxide dismutase (SOD),¹³ nitric oxide (NO),¹⁴ and malondialdehyde (MDA).¹⁵

Histological analysis

Stomachs were removed and fixed in 10% formalin, processed, and embedded into paraffin blocks. Sections were cut at 5 µm thickness and stained with hematoxylin and eosin. The slides were examined under a light microscope (Olympus BX51; Olympus Corporation, Tokyo, Japan).

Statistical analysis

Data are presented as mean \pm standard deviation and were analyzed for homogeneity of variance by the Levene test and normality by the Wilk–Shapiro *W*-statistics. One-way analysis of variance followed by Duncan multiple comparison method was carried out to compare the mean values of different groups. A *P*-value of 0.05 was considered statistically significant in all cases. Data were analyzed by using SPSS Version 21 (IBM Corporation, Armonk, NY, USA).

Ethical considerations

During the experimental process, international ethical principles for research using laboratory animals were respected. The rats were euthanized by intravenous injection of pentobarbital (100 mg/kg). This method leads to a quick and peaceful death, acceptable for rats.

Results

Phytochemical screening

The qualitative analysis revealed the presence of secondary metabolites in the ethanolic extract of OR such as terpenes, flavonoids, tannins, phenolic compounds, alkaloids, and saponins (Table 1).

Table 1 Phytochemical constituents of the ethanolic extract of *Oenothera rosea*

Constituents	Test	Result
Alkaloids	Mayer	+
	Dragendorff	+
	Wagner	+
Flavonoid	Shinoda	+
Quinone	Bornträger	+
Phenols compounds	Ferric chloride	+
Saponins	Frothing	+
Tannins	Gelatin	+
Terpenes and steroids	Liebermann–Burchard	+

Notes: +, positive; –, negative.

Effect of extract on the hematological indicators of rats

As shown in Table 2, hematological indicators show that triglycerides, cholesterol, leukocytes, high-density lipoprotein (HDL), glucose, urea, alanine aminotransferase (ALT), and alkaline phosphatase (PA) levels were significantly less in OR200 + NMU and OR300 + NMU groups ($P < 0.01$ and $P < 0.01$, respectively) than in NMU group. NMU administration at doses of 500 $\mu\text{g/kg}$ significantly increased the levels of ALT and PA ($P < 0.01$ and $P < 0.01$, respectively) compared with normal group.

Effect of extract on the biochemical indicators of the experimental animals

Biochemical indicators showed that the SOD, NO, and MDA levels were significantly less in NMU + OR100 and NMU + OR300 groups ($P < 0.05$ and $P < 0.01$) than in NMU group. Administration of OR at the dose of 200 mg/kg significantly reduced the SOD level ($P < 0.05$) as compared with NMU group (Table 3).

Effect of extract on body weight

The results showed that groups treated with 100, 200, and 300 mg/kg body weight extract had an increased body weight.

Table 3 Biochemical parameters of experimental treatment with *Oenothera rosea* on NMU-induced gastric cancer in rats

Group	SOD (U/mL)	MDA (10^{-6} mol/L)	NO ($\mu\text{mol/L}$)
SS 5 mL/kg	116.0 \pm 16.2 ^a	0.465 \pm 1.3 ^a	1.2 \pm 0.9 ^a
NMU 500 $\mu\text{g/kg}$	464.8 \pm 73.9	1.02 \pm 3.7	137.0 \pm 43.7
OR-100 mg/kg + NMU	261.2 \pm 26.5 ^a	0.179 \pm 0.4 ^a	74.8 \pm 33.6 ^b
OR-200 mg/kg + NMU	173.8 \pm 40.7 ^a	0.627 \pm 3.9 ^a	64.9 \pm 31.1 ^a
OR-300 mg/kg + NMU	128.2 \pm 34.6 ^a	0.695 \pm 2.3 ^a	104.7 \pm 25.2

Notes: Values are expressed as mean \pm standard deviation. $n=16$. ANOVA ($P < 0.01$).

^aTukey α ($P < 0.01$) versus ^bNMU β group ($P < 0.05$) versus NMU group.

Abbreviations: ANOVA, analysis of variance; MDA, malondialdehyde; NMU, N-methyl-N-nitrosourea; NO, nitric oxide; OR, ethanolic extract of *O. rosea* (mg/kg); SOD, superoxide dismutase; SS, saline solution.

Table 2 Hematological parameters of experimental treatment with *Oenothera rosea* on NMU-induced gastric cancer in rats

Group	Cholesterol (mg/dL)	Leukocytes	HDL (mg/dL)	Triglycerides (mg/dL)	Glucose (mg/dL)	Urea (mg/dL)	ALT (IU/dL)	PA (IU/dL)
SS 5 mL/kg	144.9 \pm 3.8	6424.3 \pm 304.5	43.4 \pm 1.0	150.4 \pm 10.8	88.6 \pm 2.8	20.4 \pm 1.4	15.2 \pm 1.4	96.7 \pm 2.5
NMU 500 $\mu\text{g/kg}$	180.6 \pm 3.5	9076.4 \pm 330.9	50.6 \pm 2.4	132.8 \pm 6.4	101.8 \pm 2.0	17.9 \pm 1.5	31.8 \pm 2.5	155.4 \pm 7.2
NMU + OR-100 mg/kg	168.6 \pm 6.0	7924.3 \pm 590.7*	46.5 \pm 1.8*	150.2 \pm 8.4*	89.5 \pm 2.4	17.8 \pm 1.5	19.4 \pm 2.6	140.5 \pm 6.0
NMU + OR-200 mg/kg	149.6 \pm 7.3*	7030.0 \pm 458.5*	52.2 \pm 2.6	124.4 \pm 9.9	85.3 \pm 2.7	18.1 \pm 1.4	16.7 \pm 3.6*	109.7 \pm 6.8*
NMU + OR-300 mg/kg	147.5 \pm 6.4*	7471.4 \pm 603.5*	53.8 \pm 2.4	128.6 \pm 7.5	85.6 \pm 2.2*	19.1 \pm 1.5*	10.1 \pm 0.7*	124.6 \pm 9.7*

Notes: Values are expressed as mean \pm standard deviation ($n=16$). Analysis of variance ($P=0.034$). *Tukey test ($P < 0.01$) versus NMU group.

Abbreviations: ALT, alanine aminotransferase; HDL, high-density lipoprotein; OR, ethanolic extract of *O. rosea* (mg/kg); NMU, N-methyl-N-nitrosourea; PA, alkaline phosphatase; SS, saline solution.

A significant increase in body weight was found in OR300 + NMU group (230.21 ± 18 g; $P < 0.01$; compared with NMU group). OR100 + NMU and OR200 + NMU groups also were effective during the experiment and presented significant values (168.55 ± 21 g, $P < 0.05$; 185.45 ± 12 g; $P < 0.01$, respectively) compared with NMU group (Figure 1).

Histological studies of rat stomach

Figure 2 shows the results of OR extract treatments on stomach histology. These results are in accordance with the results from hematological and biochemical level studies. It was found that the stomachs among the normal control rats had a normal histological appearance. However, stomachs in NMU group are abnormal with anaplastic and dysplastic cells. The rats treated with OR (OR200 + NMU and OR300 + NMU) had the improved histological appearances of stomachs.

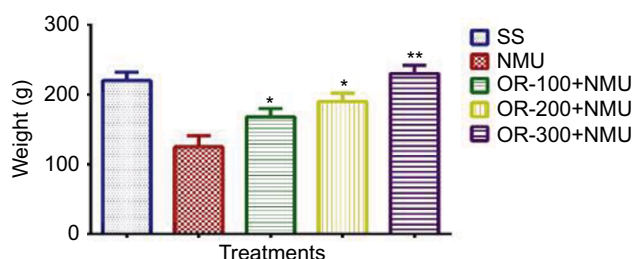


Figure 1 Body weights of rats of experimental groups at the end of the study. Values are expressed as mean \pm standard deviation ($n=16$). Analysis of variance ($P=0.024$). *Tukey test ($P < 0.05$) versus NMU group. **Tukey test ($P < 0.01$) versus NMU group.

Abbreviations: NMU, N-methyl-N-nitrosourea; OR, ethanolic extract of *Oenothera rosea* (mg/kg); SS, saline solution.

Discussion

Phytochemical analysis revealed the presence of different secondary metabolites (Table 1), and these compounds have not been identified until now. Phytochemicals are organic compounds that possess many medicinal properties; for instance, flavonoids have been associated with a reduced risk of GC, except for anthocyanidins and isoflavones.¹⁶

Otherwise, NMU is a tumor agent that has a high affinity by H_2 instead of H_1 receptors; furthermore, these receptors have different systems of second messengers, producing cell proliferation such as differentiated and transformed cells.¹⁷ NMU has mutagen and genotoxic properties, with a potent inducer of cellular stress, leading to chromosomal aberrations, point mutations, cell death, and DNA damage.¹⁸

GC induced by NMU in rats is located mainly in the gastric antrum with uniformly well-differentiated or moderately differentiated adenocarcinomas.¹⁹ In mice treated with NMU (500 μ g, weekly, intragastric intubation), after the removal of the forestomach, it has been evidenced well-differentiated adenocarcinoma in their glandular stomach with 100% incidence within 40 weeks.²⁰ In our experiment, the tumor induction was reproduced for 16 weeks.

Dysplasia is more biologically related to malignant transformation of gastric mucosa, and in this study, all animals that received the tumor-inducing agent showed a great quantity of anaplastic cells, especially in groups treated with OR. The age of animals possibly influenced that dysplasia was not the predominant pattern.²¹ In our study, the rats were 4 months old (young adults), which allowed their tissues respond less aggressively. The histological pattern found in the rats given

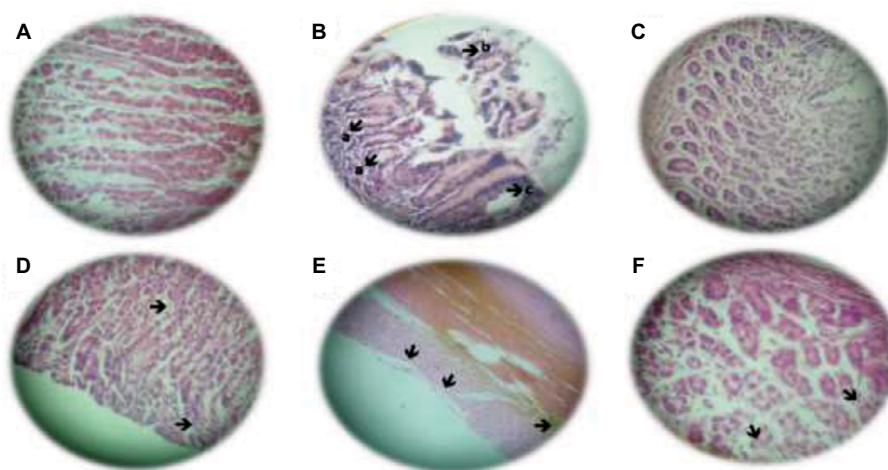


Figure 2 H&E staining of stomach of control and experimental animals. (A) Negative control: normal stomach $\times 400$. (B) NMU, as presented by arrows: (a) structural disorder, (b) anaplastic cells, (c) hyperplasia in apex, $\times 400$. (C) OR group: normal stomach, (H&E) $\times 400$. (D) NMU + OR-100: dysplasia and recovery (arrows), (H&E) $\times 400$. (E) NMU + OR-200: stomach with hypertrophy, no anaplastic figures (arrows); (H&E) $\times 400$. (F) NMU + OR-300: stomach with atrophy (arrows); (H&E) $\times 400$.

Abbreviations: H&E, hematoxylin and eosin; NMU, N-methyl-N-nitrosourea; OR, ethanolic extract of *Oenothera rosea*; SS, saline solution.

ethanol extract of OR showed discrete hyperplastic and anaplastic figures with fibrotic areas. Furthermore, the efficiency of tumor induction by NMU in other studies depended on its concentration rather than total intake.²²

Hematological parameters showed a significant increase in HDL level and a significant reduction in total cholesterol level in groups treated with OR. The lipid-lowering effect could directly influence the development of cancer.²³ It has been evidenced in preclinical studies that statins show promising results in pancreatic cancer, liver cancer, colorectal cancer, and GC.²⁴

MDA is a metabolite of the breakdown of unsaturated fatty acids into their essential chains through oxidative process.²⁵ The relationship between GC and MDA levels remains controversial. In our study, the groups that received the extract showed significantly lower values of MDA. However, Murugan et al²⁶ reported a significant reduction in MDA levels on N-methyl-N-nitro-N-nitrosoguanidine-induced gastric carcinogenesis in rats.

The effect of ethanol extract of OR on MDA, SOD, and NO levels could be due to the presence of flavonoids, which have the property of reducing the inflammatory mediators and significantly reduce the odds to develop a cancerous disease.²⁷ The levels of MDA and SOD were significantly less in treated groups compared with NMU group. MDA is related to oxidative stress and oxidative degeneration, which is closely linked to the genesis of neoplasms and dysplasias.²⁸

The limitations of this study include the lack of isolated metabolites present in the OR extract. In addition, its exact mechanism is unclear. This study includes an animal model that can be extrapolated to human beings in the future.

The data indicate the preventive potential in GC with a high therapeutic index. However, the complete mechanisms of those effects are unknown. Further studies are needed to identify more precisely the active molecules involved in the protective effect described.

Conclusion

In summary, the results obtained in this study confirmed that oxidative stress and histopathological, biochemical, and hematological changes are involved in GC; it can be inferred that bioactive metabolites of OR attenuated NMU-induced oxidative stress due to antioxidant activity on markers such as SOD, MDA, and NO. Considering the antitumorigenic, hypolipidemic, and antioxidant properties of OR, we concluded that it has a protective effect on NMU-induced GC in rats. There is a great potential to develop OR as a natural chemotherapeutic supplement in GC treatment.

Disclosure

The authors report no conflicts of interest in this work.

References

1. Newton AD, Datta J, Loaiza-Bonilla A, Karakousis GC, Roses RE. Neoadjuvant therapy for gastric cancer: current evidence and future directions. *J Gastrointest Oncol*. 2015;6(5):534–543.
2. Cocolini F, Montori G, Ceresoli M, et al. Advanced gastric cancer: what we know and what we still have to learn. *World J Gastroenterol*. 2016;22(3):1139–1159.
3. Pereira L, Zamudio R, Soares-Souza G, et al. Socioeconomic and nutritional factors account for the association of gastric cancer with Amerindian ancestry in a Latin American admixed population. *PLoS One*. 2012;7(8):e41200.
4. Suzuki M, Kiga K, Kersulyte D, et al. Attenuated CagA oncoprotein in *Helicobacter pylori* from Amerindians in Peruvian Amazon. *J Biol Chem*. 2011;286:29964–29972.
5. Abnet CC, Corley DA, Freedman ND, Kamangar F. Diet and upper gastrointestinal malignancies. *Gastroenterology*. 2015;148:1234–1243.
6. Bradbury KE, Appleby PN, Key TJ. Fruit, vegetable, and fiber intake in relation to cancer risk: findings from the European prospective investigation into cancer and nutrition (EPIC). *Am J Clin Nutr*. 2014;100(Suppl S1):394S–398S.
7. Torres MP, Rachagani S, Purohit V, et al. Graviola: a novel promising natural-derived drug that inhibits tumorigenicity and metastasis of pancreatic cancer cells in vitro and in vivo through altering cell metabolism. *Cancer Lett*. 2012;323(1):29–40.
8. Herrera-Calderon O, Enciso-Roca E, Pari-Olarte B, Arroyo-Acevedo J. Phytochemical screening, antioxidant activity and analgesic effect of *Waltheria ovata* Cav. roots in mice. *Asian Pac J Trop Dis*. 2016;6(12):1000–1003.
9. Joshi S, Gupta N, Khan R, et al. Interrelationship between angiogenesis, inflammation and oxidative stress in Indian patients with multiple myeloma. *Clin Transl Oncol*. 2016;18(2):132–137.
10. Gómez-Flores R, Reyna-Martínez R, Tamez-Guerra P, Quintanilla-Licea R. Antibacterial activity of *Oenothera rosea* (L 'Hér) leaf extracts. *Br J Med Med Res*. 2012;2(3):396–404.
11. Trease E, Evans WC. *Trease and Evans' Pharmacognosy*. 15th ed. San Diego: Harcourt Publishers Limited; 2002:343–345.
12. Tatematsu M, Ogawa K, Hoshiya T, et al. Induction of adenocarcinomas in the glandular stomach of BALB/c mice treated with N-methyl-N-nitrosourea. *Jpn J Cancer Res*. 1992;83:915–918.
13. Beauchamp C, Fridovich I. Superoxide dismutase: improved assays and an assay applicable to acrylamide gels. *Anal Biochem*. 1971;44:276–287.
14. Buege JA, Aust SD. Microsomal lipid peroxidation. *Methods Enzymol*. 1978;52:302–310.
15. Miranda KM, Espey MG, Wink DA. A rapid, simple spectrophotometric method for simultaneous detection of nitrate and nitrite. *Nitric Oxide*. 2001;5(1):62–71.
16. Lee JY, Kim N, Choi YJ, et al. Effect of N-methyl-N-nitrosourea on *Helicobacter*-induced gastric carcinogenesis in C57BL/6 mice. *J Cancer Prev*. 2016;21(3):182–186.
17. Tomita H, Takaishi S, Menheniott TR, et al. Inhibition of gastric carcinogenesis by the hormone gastrin is mediated by suppression of TFF1 epigenetic silencing. *Gastroenterology*. 2011;140:879–891.
18. Sintara K, Thong-Ngam D, Patumraj S, Klaikeaw N. Curcumin attenuates gastric cancer induced by N-methyl-N-nitrosourea and saturated sodium chloride in rats. *J Biomed Biotechnol*. 2012;2012:915380.
19. Berstein LM. Clinical usage of hypolipidemic and antidiabetic drugs in the prevention and treatment of cancer. *Cancer Lett*. 2005;224(2):203–212.
20. Deghrigue M, Lajili S, Turki M, Eltaief N, Bouraoui A. Evaluation of anti-inflammatory, analgesic and gastroprotective activities of Eunicella singularis fractions using in vivo assays. *Ann Med Biomed Sci*. 2015;1:23–28.
21. Corcos L, Le Jossic-Corcos C. Statins: perspectives in cancer therapeutics. *Dig Liver Dis*. 2013;45(10):795–802.

22. Li Q, Jia Z, Wang L, et al. Disruption of Klf4 in villin-positive gastric progenitor cells promotes formation and progression of tumors of the antrum in mice. *Gastroenterology*. 2012;142:531–542.
23. Herrera-Calderon O, Tinco-Jayo JA, Franco-Quino C, et al. Antioxidant activity and cytotoxic profile of *Chuquiraga spinosa* Lessing on human tumor cell lines: a promissory plant from Peruvian flora. *Asian Pac J Trop Dis*. 2017;7(5):304–308.
24. Pisanti S, Picardi P, Ciaglia E, D'Alessandro A, Bifulco M. Novel prospects of statins as therapeutic agents in cancer. *Pharmacol Res*. 2014;88:84–98.
25. Muhammad JS, Nanjo S, Ando T, et al. Autophagy impairment by *Helicobacter pylori*-induced methylation silencing of MAP1LC3Av1 promotes gastric carcinogenesis. *Int J Cancer*. 2017;140(10):2272–2283.
26. Murugan RS, Mohan KV, Uchida K, Hara Y, Prathiba D, Nagini S. Modulatory effects of black tea polyphenols on oxidant-antioxidant profile and expression of proliferation, apoptosis, and angiogenesis-associated proteins in the rat forestomach carcinogenesis model. *J Gastroenterol*. 2007;42(5):352–361.
27. Joshi S, Kumar S, Ponnusamy MP, Batra SK. Hypoxia-induced oxidative stress promotes MUC4 degradation via autophagy to enhance pancreatic cancer cells survival. *Oncogene*. 2016;35(45):5882–5892.
28. Zhao Y, Liu Y, Lan XM, et al. Effect of *Dendrobium officinale* Extraction on Gastric Carcinogenesis in Rats. *Evid Based Complement Alternat Med*. 2016;2016:1213090.

Clinical and Experimental Gastroenterology

Publish your work in this journal

Clinical and Experimental Gastroenterology is an international, peer-reviewed, open access, online journal publishing original research, reports, editorials, reviews and commentaries on all aspects of gastroenterology in the clinic and laboratory. This journal is included on PubMed. The manuscript management system is completely online

Submit your manuscript here: <https://www.dovepress.com/clinical-and-experimental-gastroenterology-journal>

Dovepress

and includes a very quick and fair peer-review system, which is all easy to use. Visit <http://www.dovepress.com/testimonials.php> to read real quotes from published authors.