

# Ingenol mebutate in low amounts for the treatment of actinic keratosis in Korean patients

Hyun Jae Joe  
Byung Ho Oh

Department of Dermatology,  
Keimyung University, College of  
Medicine, Daegu, Republic of Korea

**Background:** Ingenol mebutate (IM), a novel agent for field therapy of actinic keratosis (AK), has a drawback of inducing local skin reactions (LSRs), which may cause discomfort in patients. To reduce the LSRs, we tried the application of IM in low amounts.

**Objective:** The purpose of this study was to review Korean patients with AK being treated with IM and evaluate the LSRs and therapeutic outcomes of low amounts of IM.

**Methods:** We retrospectively reviewed 47 patients with AK on the face. A total of 20 and 27 patients were treated by applying recommended amount of 18.8 mg/cm<sup>2</sup> and the lower amount of 10 mg/cm<sup>2</sup>, respectively.

**Results:** The mean composite LSR score for the low amount group (LAG; 12.18±3.29) was significantly lower than that for the recommended amount group (RAG; 15.45±2.70) ( $P<0.01$ , independent sample *t*-test). The 2-month clearance rate calculated by the number of AKs before and after treatment in each patient was significantly higher for RAG (88.16%), compared with 75.56% for LAG ( $P<0.001$ ).

**Conclusion:** Low amount of IM for the treatment of facial AK significantly reduced LSRs in Korean patients. Minimizing LSRs may allow for a secondary targeting treatment of IM for the residual lesions, depending on initial treatment outcomes.

**Keywords:** actinic keratosis, field therapy, ingenol mebutate

## Background

Ingenol mebutate (IM) is a new topical drug for field therapy of actinic keratosis (AK).<sup>1,2</sup> The distinctive advantage of IM is its short treatment period consisting of once-daily application for two or three consecutive days, which generally leads to better adherence to treatment and can improve patients' quality of life, especially for patients who are easily deterred by long treatment periods.<sup>3-5</sup> However, there are inevitable local skin reactions (LSRs), such as erythema, flaking/scaling, and crusting, associated with the application of IM, which can reduce patient compliance, particularly when these LSRs are accompanied by severe pain. Furthermore, the development of LSR and LSR-related pain cannot be predicted before the start of the treatment, though LSR is hypothesized to be different according to the degree of lesional cell differentiation and the dose of IM.<sup>6,7</sup> Especially, among Asian patients with Fitzpatrick skin type III–IV, LSRs may be different from those of Caucasian patients, which may resolve within 2 weeks.<sup>8</sup>

The authors experienced several cases of patients with painful LSRs after applying the recommended amount of IM (one tube/25 cm<sup>2</sup>) in Korean patients with AK on the face. In an attempt to reduce LSRs and patients' complaints associated with

Correspondence: Byung Ho Oh  
Department of Dermatology,  
Keimyung University, College of  
Medicine, 56 Dalseong-ro, Jung-gu,  
Daegu, Republic of Korea  
Email obh505@gmail.com

pain, we tried to apply low amount of IM. In this research, we retrospectively reviewed these cases and evaluated the LSRs, pain score, and therapeutic outcomes of the low amount group (LAG) compared with the recommended amount group (RAG).

## Methods

### Patients and methods

We performed a retrospective review of 47 patients with a histopathological diagnosis of facial AK, who received IM treatment from December 2014 to December 2015 at the Dongsan Hospital in Keimyung University Health System, Daegu, Korea. All patients had not received previous treatment for their AKs.

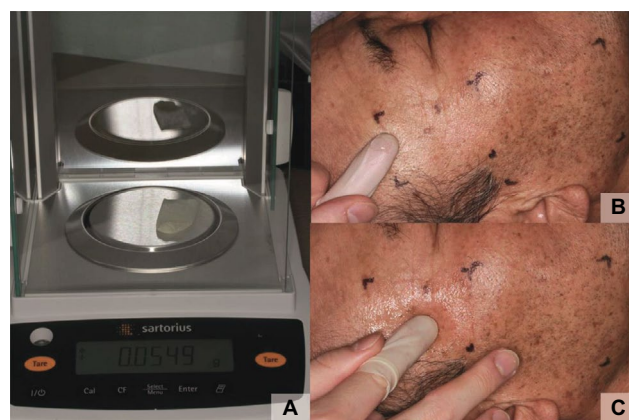A review of each patient's medical record, including age, sex, clinical stage,<sup>9</sup> pathologic report, and mode of IM treatment, number of AKs before and after treatment, LSRs, and the degree of pain was performed. Photographs were taken before the initial treatment and on every visit during follow-up periods. LSR is categorized into erythema, flaking/scaling, crusting, swelling (edema), vesiculation/pustulation, and erosion/ulceration and scored using the numeric grade of severity (0–4, with 4 being the highest grade of severity) on every visit.<sup>8</sup> The composite LSR score was calculated by adding the scores of each six LSRs. Pain scores were recorded by using the 10 cm visual analog scale (VAS), with 0 being “no pain” and 10 being “extremely painful.”<sup>10</sup>

### The application method of IM

Patients visited the outpatient department daily for three consecutive days to receive treatment using 0.015% IM (Picato®; Leo Pharma, Dublin, Ireland) by a single dermatologist. Twenty patients who were treated from December 2014 to April 2015 were given the manufacturer's recommended amount (one tube/25 cm<sup>2</sup>, 18.8 mg/cm<sup>2</sup>), whereas 27 patients who were treated from May 2015 to December 2015 were given a lower amount (10 mg/cm<sup>2</sup>). A precision balance (Analytical Balance: Sartorius Model “Entris224i-1S”) was used for accurate measurement of the IM amount for each patient (Figure 1).

### Evaluation of the therapeutic outcomes

Therapeutic outcomes were clinically evaluated 2 months after the initial IM application by using photographs and medical records. The following variables were included in the analysis: completion of three consecutive applications; composite LSR score; pain score; clearance rate of AK lesions. Each patient's clearance rate was calculated as: (the number of AK decreased after treatment/the number of AK before treatment) × 100 (%). Partial clearance was defined as



**Figure 1** An example of application: after measuring the area of application site, the amount of ingenol mebutate (IM) to be applied is measured using a precision balance (A). The amount of IM is then equally spread to the affected area with a gloved finger (B and C).

>75% clearance rate. If the size of the lesion was >0.25 cm<sup>2</sup>, the number of AK was counted as one per 0.25 cm<sup>2</sup> of area (ie, 3.7 cm<sup>2</sup> – number of AK: 15).

### Ethical approval

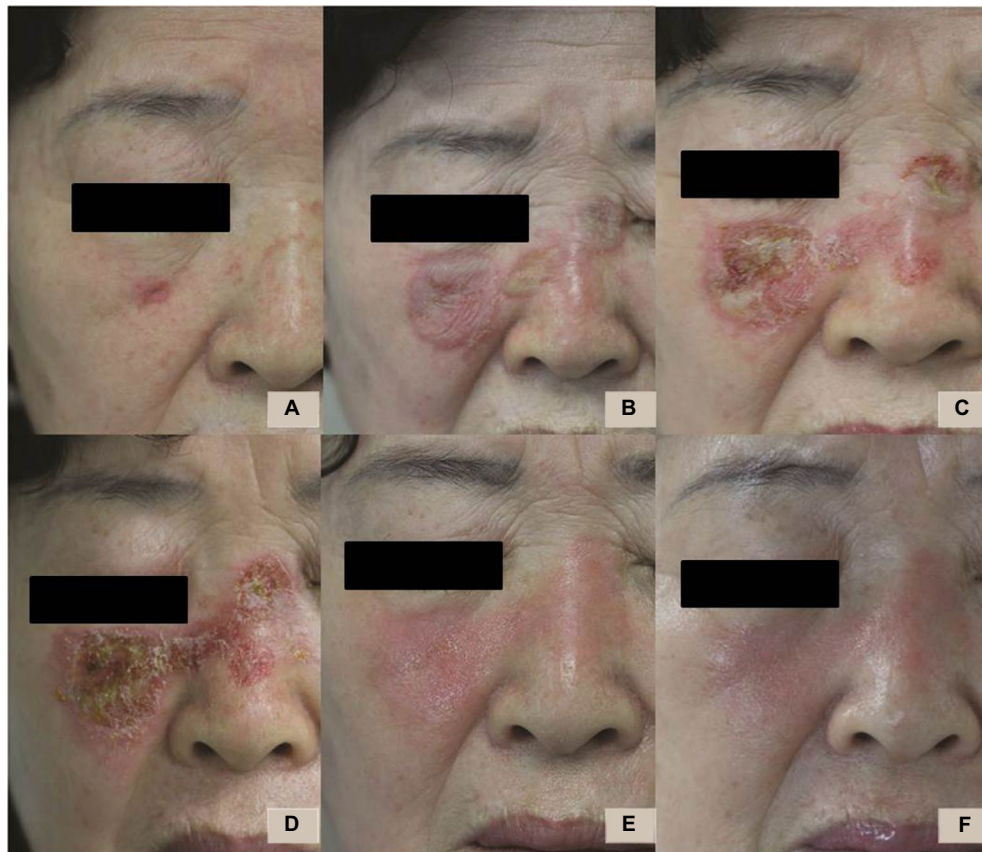
This study protocol was approved by the Institutional Review Board of Keimyung University (IRB No. 2015-09-025), Dongsan Medical Center, and was conducted according to the principles of Declaration of Helsinki. All patients signed a consent form to participate in the study, and further consent was received from patients whose photographs have been used for publication.

### Statistical analysis

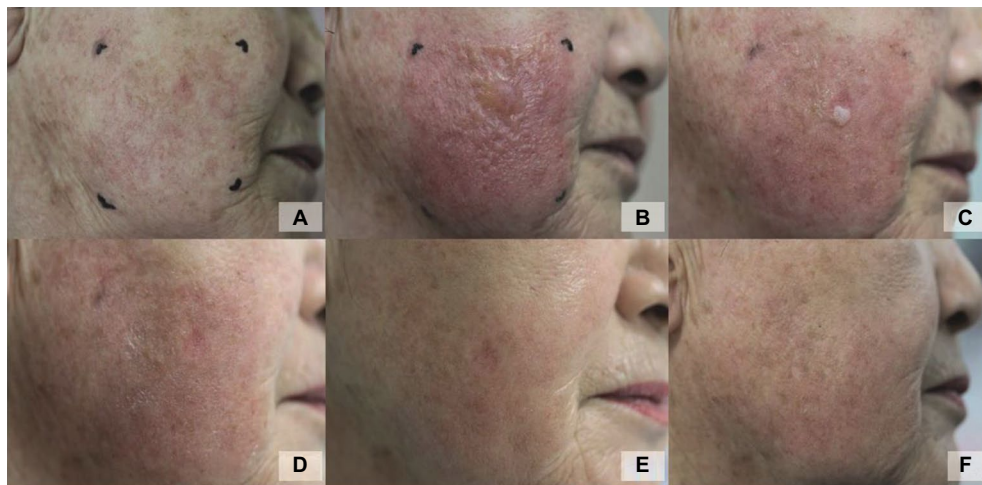Discrete variables were described with counts and percentages. For continuous variables, the median (range) or mean ± standard deviation was calculated, as appropriate for the distribution of the data. Between-group differences in age, clearance rate of AKs, maximum composite LSR score, and maximum pain score were evaluated using independent sample *t*-tests. Linear regression analysis was performed to evaluate the association between the incidence and severity of LSRs and pain score. All statistical analyses were performed with SPSS (version 19.0, IBM Corporation, Armonk, NY, USA), with the level of significance set at *P*<0.05.

### Results

The relevant characteristics of our study group are listed in Table 1. The group consisted of 31 women and 16 men, with a mean age of 75.93 years (range, 59–91 years). Seven and 21 patients had a concurrent diagnosis of diabetes and hypertension, respectively. Twenty patients received the manufacturer's recommended amount (18.8 mg/cm<sup>2</sup>), forming



**Figure 2** Local skin reactions (LSRs) after applying recommended amount ( $18.8 \text{ mg/cm}^2$ ) of ingenol mebutate in patient no. 1: (A) before application; (B) on day 1 after the first application; (C) on day 1 after the second application; (D) on day 1 after the third application (maximum composite LSR score: 19); (E) after 2 weeks from the first application; and (F) after 1 month from the first application (composite LSR score: 3).



**Figure 3** Local skin reactions (LSRs) after applying low amount ( $10 \text{ mg/cm}^2$ ) of ingenol mebutate in patient no. 23: (A) before application; (B) on day 1 after the first application (the application was discontinued due to the occurrence of bulla, maximum composite LSR score: 9); (C) after 2 days; (D) after 3 days; (E) after 2 weeks; and (F) after 1 month (composite LSR score: 1).

the RAG, and 27 received the lower amount ( $10 \text{ mg/cm}^2$ ), forming the LAG. The clinical stage was classified into three grades in RAG and LAG, respectively. There was no statistically significant difference in age and clinical stage distribution between the two groups.

The LSR score and clearance rate of our treatments are listed in Table 2. For the RAG, the maximum composite LSR score exceeded 10 points in all cases (mean score:  $15.45 \pm 2.70$ ) and remained above 3 points at 1 month posttreatment in eight cases (8/20, 40%) (Figure 2). In contrast, the mean maximum



**Table 1** Characteristics of patients in the RAG (18.8 mg/cm<sup>2</sup>) and the LAG (10 mg/cm<sup>2</sup>)

	RAG	LAG	P-value
Patients, n	20	27	NA
Sex, n (%)			
Male	3 (15.0)	13 (48.0)	NA
Female	17 (85.0)	14 (52.0)	NA
Age (range, years)	59–90	63–91	
Mean ± SD	75.65 ± 7.02	76.14 ± 7.79	0.820
Clinical stage, n (%)			
Stage I	8 (40.0)	9 (33.3)	NA
Stage II	9 (45.0)	14 (51.8)	NA
Stage III	3 (15.0)	4 (14.8)	NA

**Note:** P-value, independent samples t-test.

**Abbreviations:** RAG, recommended amount group; LAG, low amount group; NA, not applicable; SD, standard deviation

composite LSR score for the LAG was 12.18±3.29, with no cases remaining above a score of 3 points at the 1 month post-treatment (Figure 3). The difference in this score between the two groups was statistically significant ( $P<0.01$ , independent sample *t*-test) (Table 2). The groups also differed significantly in terms of maximum pain score, with a mean maximum pain score of 7.95±1.00 for the RAG and 6.55±1.42 for the LAG. In correlation analysis, there was a significant correlation between maximum pain score and maximum composite LSR score (maximum pain score =  $0.241 \times (\text{maximum composite LSR score}) + 4.342$ , linear regression analysis,  $P<0.001$ ).

In terms of therapeutic outcomes, complete clearance was achieved in nine cases (9/20, 45%) in the RAG, whereas there was one case of complete clearance in the LAG (Table 2). In addition, there was a significant difference of mean clearance rate (%) between the groups (RAG: 88.16±12.30, LAG: 75.56±9.44,  $P<0.001$ ). However, it is noteworthy that mean

**Table 2** LSR score and clearance rate of patients in the RAG (18.8 mg/cm<sup>2</sup>) and the LAG (10 mg/cm<sup>2</sup>)

	RAG (n = 20)	LAG (n = 27)	P-value
Maximum composite LSR score, mean ± SD	15.45 ± 2.70	12.18 ± 3.29	<0.01
Maximum pain score (VAS), mean ± SD	7.95 ± 0.99	6.55 ± 1.42	<0.001
Clearance rate (%), range	66.67 – 100	63.64 – 100	
Mean ± SD	88.16 ± 12.30	75.56 ± 9.44	<0.001
Cases of complete clearance (%)	9/20 (45.0)	1/27 (3.7)	
Cases of partial clearance (%)	18/20 (90.0)	12/27 (44.4)	
Reduction in total lesion count after 2 months (%)	134/157 (85.4)	283/373 (75.9)	

**Notes:** Clearance rate = (the number of AK decreased after treatment/the number of AK before treatment) × 100 (%); partial clearance, >75% clearance rate. P-value, independent samples t-test.

**Abbreviations:** LSR, local skin reaction; RAG, recommended amount group; LAG, low amount group; VAS, visual analog scale; SD, standard deviation; AK, actinic keratosis.

clearance rate was not significantly correlated with both maximum composite LSR score and pain score ( $P=0.509$  and 0.40, respectively, linear regression analysis).

## Discussion

Although ~60% of squamous cell carcinomas (SCCs) originate from AK,<sup>11</sup> the real progression rate from AK toward an invasive SCC has been reported to vary between 0.025% and 20%.<sup>12,13</sup> Nevertheless, the reason why AK should be treated is because we cannot predict which AK will transform into an invasive SCC. Various therapeutic approaches have been used for the treatment of AKs, including lesion-specific therapies, such as cryotherapy, laser therapy, and curettage, as well as field-directed therapies, such as imiquimod and topical photodynamic therapy.<sup>14–16</sup> While deciding on the treatment method, a number of factors should be considered. First, as the risk of SCC increases with the number of AK lesions,<sup>17</sup> treatment modalities should differ according to the number of AKs.<sup>18</sup> In particular, field treatment, which can treat both clinical and subclinical lesions, should be actively sought for multiple lesions. Second, patient preference and compliance should be taken into account because AK is a premalignant lesion, which requires continuous observation and treatment.

IM, a recently developed, novel agent for AK treatment, has a drawback of inducing LSRs, which may cause significant discomfort when self-administered by patients. Even though no case of scar formation after application of IM on AK lesions has been reported,<sup>3</sup> excessive inflammatory reaction may eventually lead to scarring,<sup>19,20</sup> and therefore an active prevention and intervention of severe LSRs may be required. The authors experienced severe LSRs in Korean patients with AK after applying the recommended amount of IM. The maximum composite LSR score was >10 in all patients of RAG, and contrary to previous literature,<sup>8</sup> the LSR score remained >3 points for 8/20 patients (40%) at 1 month after initial treatment. This could be related to the difference of race and skin thickness, and there is a need to reduce LSRs in Asian patients.

Interestingly, despite the high incidence of LSRs in our RAG, complete clearance of AK lesions in the treated area was achieved in only nine cases (45%). This low complete clearance rate could have resulted from inadequate absorption of the drug into the epidermis, due to hyperkeratosis, or due to subclinical AK lesions that might have emerged after partial removal of the epidermis. Therefore, a second cycle of IM treatment or application of a different treatment will eventually be necessary to treat residual lesions.

In fact, previous research has indicated that the development of LSRs after IM application is not correlated with

actual treatment efficacy,<sup>8</sup> and therefore, it would be ideal to minimize LSRs as much as possible. To reduce LSRs, we reduced the applied amount of IM, achieving a 75.56% mean clearance rate with a significant reduction in pain and LSRs. Although this clearance rate was significantly lower than the 88.16% for the RAG, it can be alleviated by a second cycle of treatment of IM. Since the risk for LSR has been shown to be lower with second cycles of IM treatment due to the reduced number of target cells,<sup>7</sup> treatment for residual lesions may be administered safely.

The present study is limited by its retrospective design. Therefore, follow-up cannot be performed until 6 months because the patient do not visit. Regardless, at 2 months, the treatment effect was positive and our results are clinically important, providing evidence of application of low amount of IM in reducing LSRs in Korean patients with facial AKs. Of course, it is necessary to estimate the treatment effect for >6 months in prospective study. Also, minimizing LSRs may allow for a secondary targeting treatment of IM for the residual lesions, depending on initial treatment outcomes.

## Conclusion

We carefully suggest that a repeated targeting treatment in residual lesion after the application of low amount may be safe and cost-effective treatment option in Asian populations. Future randomized controlled trials may be needed to determine the optimal amount and proper number of treatment cycle for the management of AK lesions in Asian populations.

## Acknowledgments

This research was supported by the Keimyung University Research Grant of 2016.

## Disclosure

The authors report no conflicts of interest in this work.

## References

- Ramsay JR, Suhrbier A, Aylward JH, et al. The sap from *Euphorbia pep- lus* is effective against human nonmelanoma skin cancers. *Br J Dermatol*. 2011;164:633–636.
- Keating GM. Ingenol mebutate gel 0.015% and 0.05%: in actinic keratosis. *Drugs*. 2012;72:2397–2405.
- Micali G, Lacarrubba F, Nasca MR, Schwartz RA. Topical pharmacotherapy for skin cancer: part I. Pharmacology. *J Am Acad Dermatol*. 2014;70:965.e1–965.e12; quiz 977–978.
- Augustin M, Tu JH, Knudsen KM, Erntoft S, Larsson T, Hanke CW. Ingenol mebutate gel for actinic keratosis: the link between quality of life, treatment satisfaction, and clinical outcomes. *J Am Acad Dermatol*. 2015;72:816–821.
- Jubert-Esteve E, Del Pozo-Hernando LJ, Izquierdo-Herce N, Bauza-Alonso A, Martin-Santiago A, Jones-Caballero M. Quality of life and side effects in patients with actinic keratosis treated with ingenol mebutate: a pilot study. *Actas Dermosifiliogr*. 2015;106(8):644–650.
- Stahlhut M, Bertelsen M, Hoyer-Hansen M, et al. Ingenol mebutate: induced cell death patterns in normal and cancer epithelial cells. *J Drugs Dermatol*. 2012;11:1181–1192.
- Jim On SC, Haddican M, Yaroshinsky A, Singer G, Lebwohl M. Reduced degree of irritation during a second cycle of ingenol mebutate gel 0.015% for the treatment of actinic keratosis. *Cutis*. 2015;95:47–51.
- Rosen R, Marmur E, Anderson L, Welburn P, Katsamas J. A new, objective, quantitative scale for measuring local skin responses following topical actinic keratosis therapy with ingenol mebutate. *Dermatol Ther (Heidelb)*. 2014;4:207–219.
- Zalaudek I, Piana S, Moscarella E, et al. Morphologic grading and treatment of facial actinic keratosis. *Clin Dermatol*. 2014;32:80–87.
- Banos JE, Bosch F, Canellas M, Bassols A, Ortega F, Bigorra J. Acceptability of visual analogue scales in the clinical setting: a comparison with verbal rating scales in postoperative pain. *Methods Find Exp Clin Pharmacol*. 1989;11:123–127.
- Goldenberg G, Perl M. Actinic keratosis: update on field therapy. *J Clin Aesthet Dermatol*. 2014;7:28–31.
- Feldman SR, Fleischer AB Jr. Progression of actinic keratosis to squamous cell carcinoma revisited: clinical and treatment implications. *Cutis*. 2011;87:201–207.
- Werner RN, Sammain A, Erdmann R, Hartmann V, Stockfleth E, Nast A. The natural history of actinic keratosis: a systematic review. *Br J Dermatol*. 2013;169:502–518.
- Chetty P, Choi F, Mitchell T. Primary care review of actinic keratosis and its therapeutic options: a global perspective. *Dermatol Ther (Heidelb)*. 2015;5:19–35.
- Jang YH, Lee DJ, Shin J, Kang HY, Lee ES, Kim YC. Photodynamic therapy with ablative carbon dioxide fractional laser in treatment of actinic keratosis. *Ann Dermatol*. 2013;25:417–422.
- Ko DY, Kim KH, Song KH. Comparative study of photodynamic therapy with topical methyl aminolevulinate versus 5-aminolevulinic acid for facial actinic keratosis with long-term follow-up. *Ann Dermatol*. 2014;26:321–331.
- Green A, Battistutta D. Incidence and determinants of skin cancer in a high-risk Australian population. *Int J Cancer*. 1990;46:356–361.
- Stockfleth E, Ferrandiz C, Grob JJ, Leigh I, Pehamberger H, Kerl H. Development of a treatment algorithm for actinic keratoses: a European Consensus. *Eur J Dermatol*. 2008;18:651–659.
- Gauglitz GG, Korting HC, Pavicic T, Ruzicka T, Jeschke MG. Hypertrophic scarring and keloids: pathomechanisms and current and emerging treatment strategies. *Mol Med*. 2011;17:113–125.
- Nguyen NM, Tremaine AM, Zachary CB. A scarring reaction to the treatment of basal cell carcinoma with ingenol mebutate. *Skinmed*. 2014;12:317–318.

**Clinical, Cosmetic and Investigational Dermatology****Dovepress****Publish your work in this journal**

Clinical, Cosmetic and Investigational Dermatology is an international, peer-reviewed, open access, online journal that focuses on the latest clinical and experimental research in all aspects of skin disease and cosmetic interventions. This journal is included on PubMed. The manuscript management system is completely online

and includes a very quick and fair peer-review system, which is all easy to use. Visit <http://www.dovepress.com/testimonials.php> to read real quotes from published authors

Submit your manuscript here: <https://www.dovepress.com/clinical-cosmetic-and-investigational-dermatology-journal>