

Complex regional pain syndrome: medical and legal ramifications of clinical variability and experience and perspective of a practicing clinician

RP Lazaro

Department of Neurology, Albany
Medical College, Albany, NY, USA

Objective: The aim of this study was to demonstrate the ramifications of clinical variability of complex regional pain syndrome (CRPS) and how they can affect the various aspects of this condition, favorably or unfavorably, for both patients and participating medical and legal professionals.

Methods: Twelve patients diagnosed with CRPS at different times in the past 25 years were followed up, and their signs and symptoms were reviewed for variability. None had preexisting or ongoing medical disorders and prior injury to the peripheral nerves or musculoskeletal tissues. None had been involved in litigation. Physical traumas that triggered CRPS were job-related, vehicular accidents, and personal injuries. The presence of vasomotor symptoms (eg, swelling, skin discoloration, and temperature changes) and allodynia in the affected extremity was the basis for clinical diagnosis in all the patients. The need for imaging studies was precluded in some patients owing to the presence of vasomotor symptoms, which either fluctuated or were steady. Seven of the patients had type 1 CRPS, and five patients had type 2 CRPS.

Results: Most patients encountered delay in diagnosis and treatment and legal obstacles owing to the lack of “typical” objective signs of CRPS. The patients’ symptoms fluctuated at different times of the day. Eight patients experienced spread of vasomotor symptoms and varying degree of allodynia in the opposite extremity. One patient, who developed signs and symptoms of rheumatoid arthritis, 2 months after the injury, continued to have CRPS symptoms in the injured hand. Treatment modalities administered in all the patients were essentially ineffective. All the patients, except one, were unable to return to their original line of work, and their symptoms persisted regardless of the outcome of their legal claims.

Conclusion: It is likely that patients who continue to complain of pain and vasomotor symptoms followed by a physical injury have CRPS. The complex interaction between the peripheral, autonomic, and central nervous system in this condition makes it challenging to diagnose, treat, and prognosticate.

Keywords: vasomotor symptom, hyperalgesia, trophic changes, temperature asymmetry, skin discoloration, muscle pain, swelling

Introduction

Complex regional pain syndrome (CRPS), formerly known as reflex sympathetic dystrophy, is a chronic disabling painful condition that persists long after the initial injury to the affected limb. Vasomotor symptoms, consisting of a cool or warm sensation, purplish discoloration, and swelling with or without sweating, occur in the injured limb. Exposure to cool temperature, leg dependency, and emotional

Correspondence: RP Lazaro
Neurology and Electroneuromyography
Clinic, 41-45, Dietz Street, Oneonta, NY
13820, USA
Tel +1 607 432 8272
Fax +1 607 441 5051
Email aacmbilling@gmail.com

stress usually intensify the pain. Movement disorder, focal or generalized, and systemic complications have also been known to occur.^{1,2} The vasomotor signs and symptoms are usually evident at the time of initial encounter with the patient, but they may not be so obvious at certain times of the day, especially when they fluctuate. Regardless, the patient continues to complain of pain in and beyond the original site on injury. The pain is associated with allodynia, a painful sensation of varying degrees that can be evoked even by light touch on the skin.

Although it has been subdivided into type 1 and type 2, the clinical symptoms may be identical, but electrophysiologically, the latter is associated with and triggered by injury to the peripheral nerve, whereas the former is triggered by injury to the musculoskeletal tissues. Traditionally, the clinical diagnosis of CRPS is established when all these objective findings, including trophic changes in the joints and integument that occur in later stages, are present. However, when the criteria essential for the diagnosis are not met, the patient is treated merely as a chronic pain sufferer without clear etiology.

This can be disconcerting and frustrating to someone in pain, regardless of the causative injury, especially when the treating physician attaches little importance to the symptoms. Such a scenario can have profound medicolegal ramifications, not to mention the effect on the psychological state of the patient. There is no laboratory procedure capable of yielding findings specific to CRPS.

Therefore, diagnosis is based on a good clinical history and examination and an understanding of the phenomenology of this

condition. This study highlights the medicolegal challenges that patients with CRPS have encountered while making an effort to prove the validity of their case.

Methods

Twelve patients (11 females and 1 male), aged 30–78 years (Table 1), were followed up for 3–30 years by the author, a board-certified neurologist and electroneuromyographer, having been previously evaluated by various health care providers. They were selected from a group of 25 patients clinically diagnosed with CRPS. At the time of injury, none of the patients reported chronic pain, gout, diabetes, malignancy, connective tissue diseases, previous injuries, prior history of CRPS, and any systemic and endocrine disorders. None were involved or had been involved in an ongoing litigation process, prior to the injury. Musculoskeletal and neural trauma that triggered CRPS was job-related in eight patients, related to a motor vehicular accident in two patients, and related to personal injury in another two patients. A clinical diagnosis was made based on the presence of vasomotor symptoms and allodynia in the affected extremity that manifested within 2 weeks of the injury.

A positive three-phase bone scan was reported for three patients (Patients 1, 2, and 7) and a negative study for one patient (Patient 3). A cooler right upper extremity, consistent with sympathetic nerve overactivity, was demonstrated in Patient 4 following liquid crystal thermography. As the clinical signs and symptoms were already evident in the remaining patients, it was deemed unnecessary to perform radiologic or thermographic studies.

Table 1 Summary of patient profiles

Patient number/gender/age at the time of injury/length of follow-up	Site/etiology of injury/type of CRPS/spread of vasomotor symptoms	Malingering initially suspected/presence of depression or anxiety after CRPS onset	Disability status
1/female/38 years/30 years	Right lower limb/job-related/type 2/yes	No/yes	Disabled
2/female/55 years/25 years	Left lower limb/job-related/type 2/yes	No/yes	Disabled
3/female/58 years/3 years	Left ankle and leg/vehicle accident-related/type 2/yes	Yes/yes	Disabled
4/female/20 years/20 years	Right upper limb/vehicle accident-related/type 1/yes	Yes/yes	Able to work part-time
5/female/52 years/3 years	Right lower limb/job-related/type 1/no	Yes/yes	Disabled
6/male/57 years/3 years	Right hand/job-related/type 1/no	Yes/yes	Disabled
7/female/36 years/4 years	Right ankle/personal injury/type 2/no	Yes/yes	Able to work part-time
8/female/36 years/3 years	Right hand/job related/type 1/yes	Yes/yes	Disabled
9/female/28 years/3 years	Left upper limb and shoulder/job-related/type 1/yes	Yes/yes	Disabled
10/female/52 years/3 years	Left hand/job-related/type 1/yes	Yes/yes	Disabled
11/female/58 years/5 years	Left upper limb and shoulder/job-related/type 1/yes	Yes/yes	Disabled
12/female/46 years/22 years	Left upper limb/personal injury/type 2/no	No/no	Able to work full-time

Abbreviation: CRPS, complex regional pain syndrome.

Peripheral nerve injury, documented electrophysiologically, was demonstrated in Patient 1, (sciatic nerve), in Patient 2 (fifth lumbar nerve root), in Patients 3 and 7 (superficial peroneal sensory nerve), and in Patient 12 (median nerve). The remaining patients sustained various musculoskeletal and soft tissue injuries to the upper and lower extremities that triggered type 1 CRPS. None (except for a fracture to the left humerus of Patient 11) had bone fractures that initiated CRPS.

The prior failure of sympathetic nerve blocks, given to Patients 1, 2, and 9, led to the institution of oral pharmacotherapy in the remaining patients only. Gabapentin, pregabalin, muscle relaxants, various antidepressants, and analgesic and lidocaine patches together with physical therapy were administered to all the patients. The patients felt minimal and temporary pain relief. Some patients took oral narcotic analgesics prescribed by their primary care providers, but none developed drug dependence as they were able to discontinue them without consequences. Oral steroids were offered to some patients, but all of them, with the exception of Patient 12, declined, after they learned the potentially adverse side effects of the steroids. A trial of alternative therapies in all the patients was prevented owing to financial and health insurance issues.

The Chesapeake Institutional Review Board (IRB) in Columbia, MD, USA, had determined that the present study does not constitute human subject research and, therefore, does not require IRB oversight and it was deemed unnecessary to obtain written informed consent from patients described in this study. The author of this paper was one of the deponents in legal proceedings held at various times for the patients and various parties involved.

Results and clinical course

Patients 1 and 2 became wheelchair-bound 2 years after sustaining unilateral injury to the lower extremity. Their vasomotor symptoms eventually spread to the opposite side. Both the patients developed intermittent dystonic posturing of the injured side (Figure 1). A computerized axial tomography scan of the brain in both of them was normal. Neither encountered protracted bureaucratic impediments in their job-related claims.

Patient 3, who developed type 2 CRPS secondary to injury of the superficial peroneal nerve, in a motor vehicle accident, experienced persistent swelling in the affected leg, skin fragility, and allodynia that spread to the uninjured side. A year and a half after the symptoms were diagnosed, an independent medical examiner (IME) recommended that further treatment should be discontinued. It was the opinion of the examiner that

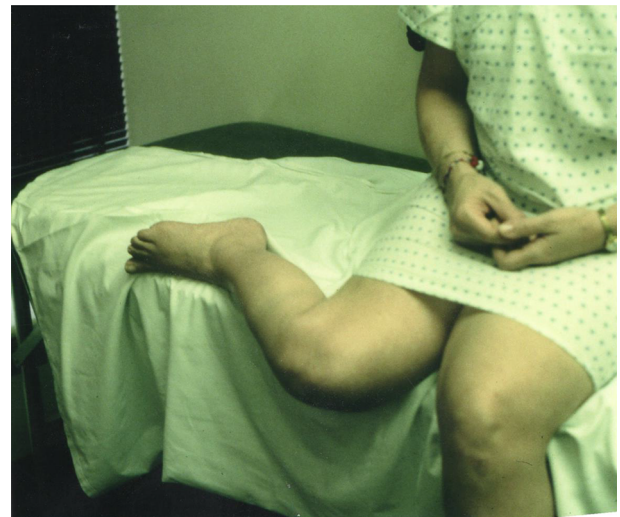


Figure 1 Patient 1 with dystonia of the right lower extremity.

Note: In order to reduce pain, the dystonic lower extremity was kept elevated because leg dependency intensified the pain.

there were “no detectable signs” of CRPS and that the patient had achieved maximum medical improvement.

Patient 4 developed recurrent vasomotor symptoms and allodynia in the affected extremity that lasted for several years but was able to work on a limited basis. Interestingly, she developed transient symptoms of CRPS every time she sustained a minor injury or infection in other parts of her body.

Patient 5, who experienced some legal difficulties that were resolved following the presentation of photographic evidence of her intermittent vasomotor symptoms, demonstrated at the height of pain exacerbation, in the right lower extremity.

Patient 6 developed signs of rheumatoid arthritis (RA) 2 months after the injury and the onset of CRPS. He was treated accordingly for RA by the rheumatologist, using methotrexate, adalimumab, and prednisone. The symptoms related to CRPS in the right hand persisted and remain unresolved. A causal relationship between CRPS and the onset of CRPS was disputed.

Patient 7 continued to experience recurrent vasomotor symptoms and pain related to injury to the superficial nerve at the ankle, even after her case had been settled.

The IME questioned the diagnosis of CRPS in Patients 8–11, leading to a denial of their claims. However, the ruling was given in their favor in the subsequent legal proceedings, after the necessary clinical documents from the treating physicians were submitted into evidence. The vasomotor symptoms and allodynia of Patients 8–11 became more evident in subsequent months following the injury. All of them, except Patient 12, were unable to return to their original line of work. The degree of disability for those with fluctuating

vasomotor symptoms, for example, Patients 4, 5, and 7–11, was initially controverted but later affirmed, following the corroboration of the objective clinical findings.

Patient 8 attempted to return to work owing to financial issues, but after 3 weeks, she was forced to resign when the pain and vasomotor symptoms worsened in her hands and began to affect her legs and feet. Patients 9–11 never attempted to return to work due to unrelenting pain and the spread of vasomotor symptoms to contralateral extremity. Patient 12, who developed type 2 CRPS secondary to median nerve injury and hematoma formation during intravenous administration of dihydroergotamine for migraine, was able to return to her original line of work after surgical decompression of the median nerve at the antecubital fossa. Her symptoms recurred 10 years later, after years of performing repetitive activities at the workplace. A 1-week course of oral prednisone therapy together with the application of analgesic cream resulted in modest pain relief. She was able to continue working. Legal obstacles were not encountered when making her claims.

Discussion

The criteria set forth in the previous study,³ although useful in the diagnosis and management of CRPS, may have been too restrictive and may not have taken into account the varying degree and protean manifestations of this condition. The difficulties encountered by some patients in the present study are just a few examples of medicolegal challenges encountered. Many medical and surgical specialists, each with their own special interest, were called upon to provide a second or third opinion on injured patients suffering from this condition. Following set guidelines for the diagnosis of CRPS is not feasible. Health care providers need to be cognizant of the variable manifestations of CRPS and to adopt an open-minded and multidisciplinary approach to the treatment of this condition without prejudice. It is a syndrome and not a disease with specific or pathognomonic signs and symptoms. It is imperative that within the confines of cost consciousness in the present health care system, a proper assessment of certain symptoms and objective findings are necessary to justify the treatments that patients deserve. When the examiner fails to recognize the signs or symptoms of CRPS, or when malingering is suspected as a possible reason for the persistence of pain, the resulting emotional upheaval and sympathetic overactivity can complicate matters for the pain sufferers who have developed a second debilitating and persistent painful condition as a result of the original injury.

The clinical symptomatology of CRPS is pathophysiologically linked to complex interactions among the peripheral nociceptors and neuropeptides excreted by them, immune cells that mediate inflammation via proinflammatory cytokines, and the central and autonomic nervous system.⁴

It has been indicated in numerous studies that they are the main participants in the generation of pain in CRPS, despite debatable correlation between pain and sympathetic overactivity. Heightened perception of pain in CRPS during a stressful situation or in the event of emotional tension is a frequent occurrence. The patients described in the present study had similar experiences. Some health care professionals may view them as malingerers or compensation seekers especially when the symptoms are disproportionate to objective findings, although both the exacerbation of pain and autonomic dysregulation occur *pari passu* (on an equal footing) in most patients. Similarly, the same mechanism may play a role in the augmentation of pain when the affected limb is exposed to cool temperatures. Some physicians may not be aware of this phenomenon and consequently provide a misleading legally sensitive opinion, thereby jeopardizing the validity of patient's symptomatology.

The sequence of events that occurred in Patient 6 was quite intriguing. Following an initial injury to the right hand and the subsequent development of signs and symptoms of CRPS, he went on to develop polyarthralgia 2 months later, which affected the upper and lower extremities. The results of an extensive rheumatological evaluation were consistent with RA. It is worthy of note that cytokines and peptides, together with immune cells, have been demonstrated in both CRPS and RA.^{4,5} Although a clear conclusion could not be drawn from this sequence of events, the temporal association between physical trauma and the onset of RA has been reported previously and may be significant.⁶

The spontaneous spread of CRPS, without new trauma, is a well-known phenomenon possibly mediated by spinal or supraspinal mechanisms.⁷ The spread of vasomotor symptoms occurred in most of the patients studied. Some health care providers may not find this spread credible, leading them to make a diagnosis other than CRPS, resulting in diagnostic and therapeutic obfuscation.

One limitation of the present study is lack of laboratory findings to corroborate the presence of ongoing pain in some patients. The legal system is preoccupied with the demonstration of objective evidence that correlates with the subjective aspect of a patient's symptomatology and, particularly, pain.

However, the presence of associated and discernible clinical signs of autonomic dysregulation in the affected limb

(and movement disorder or trophic changes in some cases) is remarkably convincing, diagnostically. In addition, there is no CRPS-specific laboratory procedure. The cost of the procedures followed is high, and they have poor sensitivity.⁸ Thus, the demonstration of clinical abnormalities remains the gold standard in the diagnosis of CRPS.

In the past years, some patients with CRPS were told by their physicians that their pain was being imagined or fabricated. However, currently, it is known that the central nervous system plays a major role in the pathogenesis of the condition. A recent study, using functional magnetic resonance imaging of the brain,⁹ have shown reorganization of the somatosensory and motor neuronal networks in CRPS, in response to persistent nociceptive inputs from peripheral neurogenic inflammation.

Changes in motor and sensory cortical plasticity have also been shown, by using motor cortical mapping¹⁰ and magnetoencephalography.¹¹ The occurrence of changes in the cortex¹² and abnormal gray–white matter interactions in emotional, autonomic, and pain-related regions in the brain^{13,14} and the spread of symptoms through spinal or supraspinal mechanisms⁷ are sound reasons for the adoption of a multidisciplinary approach to the treatment of this painful condition.

The treatment of CRPS, evaluations by multiple health care professionals, and costly legal proceedings can drain the financial resources of the health care system. It is difficult to treat because of a constellation of symptoms referable to peripheral, autonomic, and central nervous system and all acting in conjunction with one another following a physical injury. Unlike other physical disabilities with clear demonstrable laboratory findings, there are no clear unifying guidelines for the diagnosis, treatment, and disability determination of CRPS. Perhaps when functional imaging studies^{9–11} become routine in clinical practice (health insurance cost notwithstanding), controversies besetting the current medical and legal system will be avoided. In addition, the disability determination in all the patients must be guided by the natural history of this condition because several variables can either worsen or stabilize as time passes.¹⁵

Scientific understanding of this perplexing condition continues to evolve and will continue to generate controversies in future until the health care providers become more familiar with the pathophysiology and variability of the manifestations

of CRPS. Birklein et al¹⁶ stated, “One avenue for progress will be to abandon categorizations that lump together too many pathophysiologies and introduce too many variations into scientific studies; CRPS research must be more specific.”

Acknowledgments

The author did not receive funding from any organization, insurance companies, members of the legal professions, and patient advocacy groups.

Disclosure

The author reports no conflicts of interest in this work.

References

- Schwartzman RJ, Kerrigan J. The movement disorder of reflex sympathetic dystrophy. *Neurology*. 1990;40(1):57–61.
- van Hilten JJ, van de Beek WJ, Vein AA, Dijk JG, Middelkoop HA. Clinical aspect of multifocal or generalized tonic dystonia in reflex sympathetic dystrophy. *Neurology*. 2001;56(12):1762–1765.
- Harden RN, Oaklander AL, Burton AW, Perez RS. Complex regional pain syndrome: practical diagnostic and treatment guidelines, 4th edition. *Pain Med*. 2013;14(2):180–229.
- De Mos M, Sturkenboom M, Huygen F. Current understandings on complex regional pain syndrome. *Pain Pract*. 2009;9(2):86–99.
- Green PG. Gastrin-releasing peptide, substance P and cytokines in rheumatoid arthritis. *Arthritis Res Ther*. 2005;7(3):111–113.
- Al-Allaf AW, Sanders PA, Ogston SA, Marks JS. A case-control study examining the role of trauma in the onset of rheumatoid arthritis. *Rheumatology (Oxford)*. 2001;40(3):262–266.
- van Rijn MA, Marinus J, Putter H, Bosselaar SR, Moseley GJ, van Hilten JJ. Spreading of complex regional pain syndrome: not a random process. *J Neural Transm (Vienna)*. 2011;118(9):1301–1309.
- Schurman M, Zaspel J, Lohr P, et al. Imaging in early posttraumatic complex regional pain: a comparison of diagnostic methods. *Clin J Pain*. 2011;23(5):449–457.
- Schwenkreis R, Maier C, Tegenthoff M. Functional imaging of central nervous system involvement in complex regional pain syndrome. *AJNR Am J Neuroradiol*. 2009;30(7):1279–1284.
- Maihöfner C, Handwerker HO, Neundörfer B, Birklein F. Patterns of cortical reorganization in complex regional pain syndrome. *Neurology*. 2003;61(12):1707–1715.
- Krause P, Forderreuther S, Straube A. TMS motor cortical brain mapping in patients with complex regional pain syndrome type 1. *Clin Neurophysiol*. 2006;117(1):169–176.
- Swart CMA, Stins JF, Beek PJ. Cortical changes in complex regional pain syndrome (CRPS). *Eur J Pain*. 2009;13(9):902–907.
- Geha PY, Baliki MN, Harden RN, Bauer W, Parrish TB, Apkarian AV. The brain in chronic CRPS pain: abnormal gray–matter interactions in emotional and autonomic regions. *Neuron*. 2008;60(4):570–581.
- Barad MJ, Ueno T, Younger J, Chatarjee N, Mackey S. Complex regional pain syndrome is associated with structural abnormalities in pain-related regions of the human brain. *J Pain*. 2014;15(2):197–203.
- Schwartzman RJ, Erwin KL, Alexander GM. The natural history of complex regional pain. *Clin J Pain*. 2009;25(4):273–280.
- Birklein F, O'Neill D, Schlereth T. Complex regional pain: an optimistic perspective. *Neurology*. 2015;84(1):89–96.

Journal of Pain Research**Dovepress****Publish your work in this journal**

The Journal of Pain Research is an international, peer reviewed, open access, online journal that welcomes laboratory and clinical findings in the fields of pain research and the prevention and management of pain. Original research, reviews, symposium reports, hypothesis formation and commentaries are all considered for publication.

The manuscript management system is completely online and includes a very quick and fair peer-review system, which is all easy to use. Visit <http://www.dovepress.com/testimonials.php> to read real quotes from published authors.

Submit your manuscript here: <https://www.dovepress.com/journal-of-pain-research-journal>