

Angiographic results of retinal-retinal anastomosis and retinal-choroidal anastomosis after treatments in eyes with retinal angiomatous proliferation

Masaaki Saito¹
Tomohiro Iida^{1,2}
Mariko Kano¹
Kanao Itagaki¹

¹Department of Ophthalmology, Fukushima Medical University School of Medicine, Fukushima, ²Department of Ophthalmology, Tokyo Women's Medical University School of Medicine, Tokyo, Japan

Background: The purpose of this study was to evaluate the angiographic results of retinal-retinal anastomosis (RRA) and retinal-choroidal anastomosis (RCA) for eyes with retinal angiomatous proliferation (RAP) after treatment with intravitreal bevacizumab injections as monotherapy or intravitreal bevacizumab combined with photodynamic therapy.

Methods: In this interventional, consecutive case series, we retrospectively reviewed five naïve eyes from four patients (mean age 80 years) treated with three consecutive monthly intravitreal bevacizumab (1.25 mg/0.05 mL) injections as initial treatment, and followed up for at least 3 months. In cases with over 3 months of follow-up and having recurrence of RAP or leakage by fluorescein angiography, retreatment was performed with a single intravitreal bevacizumab injection and photodynamic therapy.

Results: Indocyanine green angiography showed RRA in three eyes with subretinal neovascularization and RCA in two eyes with choroidal neovascularization at baseline. At 3 months after baseline (month 3), neither the RRA nor RCA was occluded in any eye on indocyanine green angiography. Retreatment with intravitreal bevacizumab plus photodynamic therapy was performed in three eyes at months 3 (persistent leakage on fluorescein angiography), 6, and 7 (recurrence of RAP lesion), which achieved obvious occlusion of the RRA and RCA. Mean best-corrected visual acuity improved from 0.13 to 0.21 at month 3 ($P = 0.066$). No complications or systemic adverse events were noted.

Conclusion: Although intravitreal bevacizumab for RAP was effective in improving visual acuity during short-term follow-up, intravitreal bevacizumab could not achieve complete occlusion of RRA and RCA, which could lead to recurrence of a RAP lesion and exudation. Retreatment with intravitreal bevacizumab plus photodynamic therapy ultimately achieved complete occlusion of the RRA and RCA.

Keywords: retinal angiomatous proliferation, retinal-retinal anastomosis, retinal-choroidal anastomosis, bevacizumab, photodynamic therapy, ranibizumab

Introduction

Yannuzzi et al first described retinal angiomatous proliferation (RAP), which consists of three stages based on clinical and angiographic observations, ie, stage 1, intraretinal neovascularization; stage 2, subretinal neovascularization; and stage 3, choroidal neovascularization.¹ Choroidal neovascularization often consolidates a retinal-choroidal anastomosis (RCA), which is newly called stage 4.² RAP is well known to have a different natural course and response to therapies as compared with typical exudative age-related macular degeneration.^{3–5}

Retinal-retinal anastomosis (RRA) and RCA are important signs of RAP lesions.^{1,2} RRA and RCA contribute to a high blood supply to RAP lesions. Surgical lysis

Correspondence: Masaaki Saito
Department of Ophthalmology,
Fukushima Medical University School
of Medicine, 1 Hikarigaoka, Fukushima
960-1295, Japan
Tel +812 4547 1303
Fax +812 4548 2640
Email smasaaki@fmu.ac.jp

of feeding arterioles and draining venules has been reported to eliminate blood flow to RAP lesions, causing resolution of intraretinal edema and flattening of retinal pigment epithelial detachment,⁶ but recurrence of exudation occurs with recanalization or new development of retinal feeding and draining vessels.⁷ Therefore, complete occlusion of the RRA or RCA is important for reducing RAP lesions.

Vascular endothelial growth factor (VEGF) is well known to be closely associated with choroidal neovascularization complexes.^{8–10} The major clinical trials first reported that ranibizumab (Lucentis, Genentech Inc, South San Francisco, CA) was effective in improving visual acuity for patients with age-related macular degeneration.^{11,12} Intravitreal ranibizumab has become one of the evidence-based therapies for age-related macular degeneration all over the world.¹³ Recently, anti-VEGF therapy using intravitreal ranibizumab or bevacizumab has been reported to be a useful treatment for improving or maintaining visual acuity for patients with RAP.^{14,15} Nevertheless, intravitreal bevacizumab injections could not achieve complete occlusion of feeder vessels in eyes with RAP.¹⁶ We have reported in previous studies that combined photodynamic therapy with intravitreal bevacizumab or ranibizumab achieved complete occlusion of RRA on indocyanine green angiography.^{17–19} However, no reports have clarified the angiographic results of RRA or RCA in detail after treatment.

The purpose of the current study was to show the angiographic results of RRA or RCA after three consecutive monthly intravitreal bevacizumab injections or combined treatment of intravitreal bevacizumab and photodynamic therapy for eyes with RAP.

Materials and methods

We retrospectively reviewed five consecutive eyes from four Japanese patients (two men, two women, mean age 80.0 ± 4.8 , range 64–90 years) with naïve RAP treated using intravitreal bevacizumab as initial therapy from August to December 2006 at different stages of the disease. The patients were followed up for at least 3 months at Fukushima Medical University Hospital. The exclusion criteria were previous treatment for RAP, such as laser photocoagulation, submacular surgery, transpupillary thermotherapy, photodynamic monotherapy, or a combination of photodynamic therapy with intravitreal triamcinolone acetonide, and maculopathies, such as diabetic maculopathy, retinal vascular occlusion, or idiopathic macular telangiectasia.

The institutional review board/ethics committee at Fukushima Medical University approved the bevacizumab,

retrospective chart review of patients with age-related macular degeneration, and retrospective comparative analysis performed in this study. After the potential risks and benefits were explained in detail, all patients provided their written informed consent.

We used best-corrected visual acuity (BCVA) measured using a standard Japanese decimal visual acuity chart and calculated the mean BCVA using the logarithm of the minimum angle of resolution (logMAR) scale. We converted decimal BCVA into Early Treatment Diabetic Retinopathy Study (ETDRS) visual acuity letter scores using a previously reported mathematical method.^{20,21} All patients underwent a standardized examination, including slit-lamp biomicroscopy with a contact lens, color or red-free fundus photography, fluorescein angiography, indocyanine green angiography with a fundus camera (TRC-50 FA/IA/IMAGEet H1024 system, Topcon, Tokyo, Japan), and confocal scanning laser ophthalmoscopy (Heidelberg Retina Angiograph 2, Heidelberg Engineering, Heidelberg, Germany). All optical coherence tomography (OCT) examinations were performed using spectral-domain optical coherence tomography (3D-OCT, Topcon, Tokyo, Japan). Fluorescein angiography was performed to determine the lesion type, location, and choroidal neovascularization activity of the RAP lesions, ie, the degree or extent of leakage. Indocyanine green angiography was performed to diagnose RAP and identify RRA and RCA.

All patients had documented visual loss at baseline. The method used to administer intravitreal bevacizumab (1.25 mg/0.05 mL) was according to past reports.^{17,18} After the three monthly intravitreal bevacizumab injections, fluorescein and indocyanine green angiography was performed for all eyes. In cases with over 3 months of follow-up and having recurrence of RAP or leakage on fluorescein angiography, we performed retreatment with a single intravitreal bevacizumab injection and photodynamic therapy, as reported previously.^{17,18}

Statistical analysis was performed using the Student's paired *t*-test to compare visual acuity at one and 3 months after treatment. *P* values ≤ 0.05 were considered to be statistically significant. We used logMAR visual acuity scores for the statistical analysis.

Results

Table 1 shows the characteristics and clinical data for the consecutive four patients (representing five eyes). All patients were Japanese and were observed for at least 3 months (range 4–10 months, mean 7.4 ± 2.2 months). One eye had stage 2 RAP without retinal pigment epithelial detachment, two eyes

Table 1 Clinical profiles of patients

Case no	Age (years)	Gender	Eye	RAP stage	Baseline		Month 3				From month 3 onwards				
					VA (logMAR) (ETDRS letters)	RRA or RCA	Hot spot	VA (logMAR) (ETDRS letters)	RRA or RCA	CME	PED	Hot spot	Leakage on FA findings	Retreatment	RRA or RCA after retreatment
1	64	F	Left	3	0.1 (1.00) (35)	RCA	Yes	0.2 (0.70) (50)	Yes	Di	Di	No	No	IVB + PDT (month 6)	No
2	89	M	Left	2 + PED	0.1 (1.00) (35)	RRA	Yes	0.3 (0.52) (58)	Yes	De	NC	De	Minimal	No	–
3	77	M	Right	2	0.3 (0.52) (58)	RRA	Yes	0.5 (0.30) (70)	Yes	Di	–	No	No	IVB + PDT (month 7)	No
4	90	F	Right	3	0.06 (1.22) (24)	RCA	Yes	0.07 (1.15) (27)	Yes	De	NC	De	Minimal	No	–
5	90	F	Left	2 + PED	0.2 (0.70) (50)	RRA	Yes	0.2 (0.70) (50)	Yes	De	De	De	Yes	IVB + PDT (month 3)	No
Mean	80.0				0.13 (0.89) (40)			0.21 (0.68) (51)							

Abbreviations: F, female; M, male; RAP, retinal angiomatous proliferation; ETDRS, Early Treatment Diabetic Retinopathy Study; VA (logMAR) (ETDRS), decimal visual acuity (logMAR equivalent) (convert decimal value to an approximate ETDRS); RRA, retinal-retinal anastomosis; RCA, retinal-choroidal anastomosis; CME, cystoid macular edema; PED, pigment epithelial detachment; FA, fluorescein angiography; PDT, photodynamic therapy; Di, disappeared; De, decreased; NC, no change; IVB, intravitreal bevacizumab injection; PDT, photodynamic therapy.

had stage 2 RAP with pigment epithelial detachment, and two eyes had stage 3 RAP.

Early-phase indocyanine green angiography identified RRA in three eyes and RCA in two eyes at baseline (Figures 1 and 2). At month 3, neither the RRA nor RCA was occluded in any of the eyes (Table 1, Figures 1 and 2). Late-phase indocyanine green angiography showed a hot spot in all five eyes at baseline (Table 1 and Figure 1). The hot spot resolved completely in two eyes and decreased in three eyes at month 3 (Table 1). At baseline, all five eyes had cystoid macular edema and four eyes had pigment epithelial detachment on OCT. Cystoid macular edema resolved in two (40%) eyes at a mean of one week after baseline and decreased in three eyes (Table 1). The pigment epithelial detachment resolved in one (25%) eye 4 weeks after baseline and remained in three eyes (Table 1). At month 3, OCT showed cystoid macular edema remaining in the three eyes and the remaining pigment epithelial detachment in the one eye had decreased from baseline (Table 1).

Fluorescein angiography showed resolution of leakage in two (40%) of the five eyes at month 3. In the remaining three eyes, two eyes had minimal leakage and one eye had persistent leakage by fluorescein angiography.

Retreatment using intravitreal bevacizumab plus photodynamic therapy was performed in one eye with persistent leakage on fluorescein angiography at month 3 (Table 1). Two eyes with minimal leakage on fluorescein angiography showed decreased cystoid macular edema and unchanged pigment epithelial detachment at month 3; improving visual acuity was observed at this time and the patient did not consent to retreatment. In the remaining two eyes without a hot spot on indocyanine green angiography, leakage by fluorescein angiography, or exudation by OCT at month 3, indocyanine green angiography showed recurrence of the RAP lesion with exudation on OCT at months 6 and 7 (Table 1, Figures 1 and 2). Retreatment was performed with intravitreal bevacizumab plus photodynamic therapy in both eyes. Of the three eyes retreated with intravitreal bevacizumab plus photodynamic therapy, obvious resolution of RRA and RCA was seen on indocyanine green angiography in all three eyes 3 months after retreatment (Figures 1 and 2).

The mean decimal BCVA (logMAR equivalent, decimal value converted to an approximate ETDRS) levels at baseline and months 1 and 3 were 0.13 (0.89) (40), 0.22 (0.66) (52), and 0.21 (0.68) (51), respectively. There was no statistically significant difference in mean BCVA at months 1 and 3 ($P = 0.058$ and $P = 0.066$, respectively, paired t -test). The mean changes in BCVA at months 1 and 3 were improvements

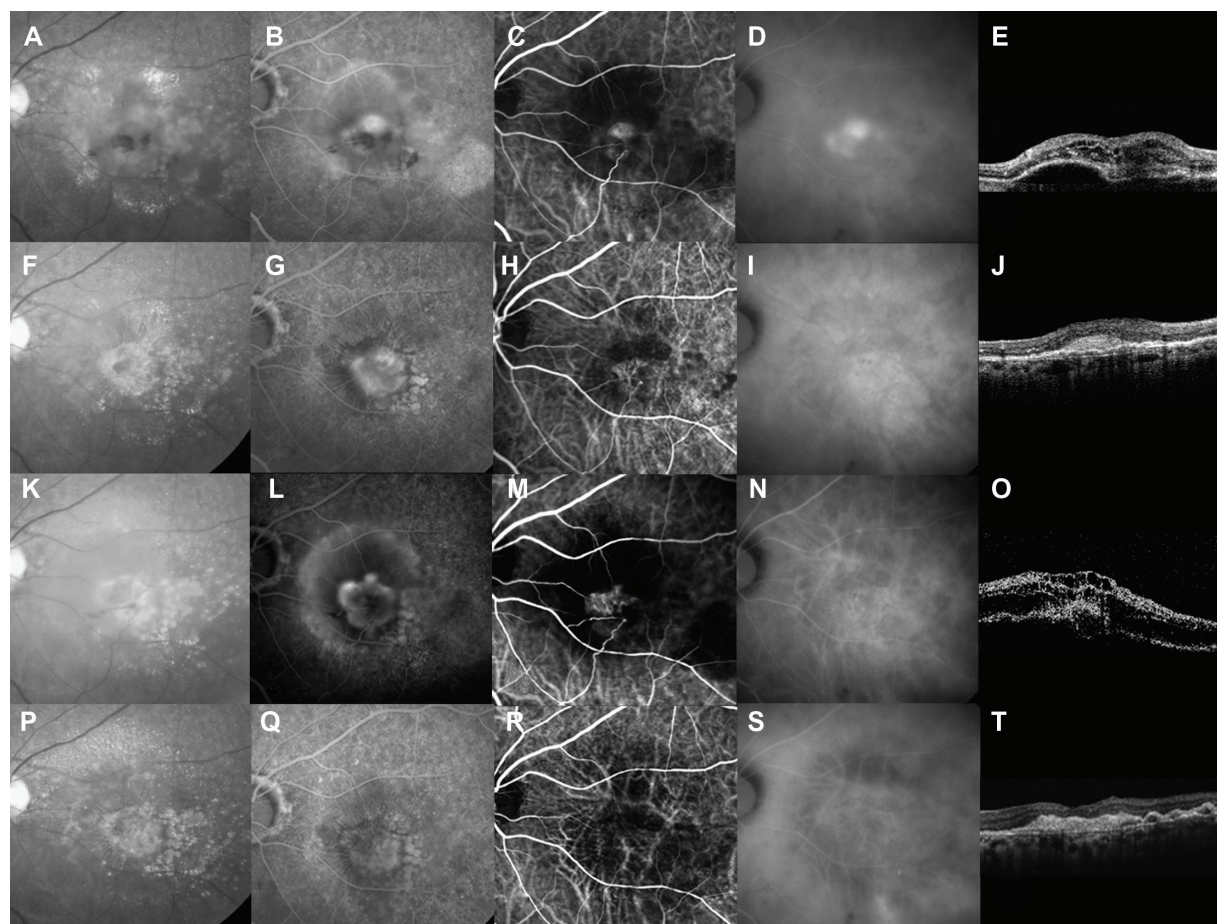


Figure 1 A 64-year-old woman was treated with intravitreal bevacizumab for stage 3 retinal angiomatous proliferation (RAP). At baseline, best-corrected visual acuity (BCVA) was 0.1 decimal visual acuity in the left eye. **(A)** Red-free photograph showing intraretinal and preretinal hemorrhages, drusen, retinal pigment epithelial detachment, and lipid. **(B)** Fluorescein angiography showing minimal classic choroidal neovascularization and intraretinal edema. **(C)** Early-phase indocyanine green angiography showing RAP lesions within the retina and beyond as well as retinal-choroidal anastomosis (RCA). **(D)** Late-phase indocyanine green angiography showing RAP lesions as focal areas of intense hyperfluorescence (hot spots) and staining of fibrin in cystoid spaces. **(E)** Baseline horizontal optical coherence tomography (OCT) image shows cystoid macular edema and a pigment epithelial detachment. **(F)** At month 3, after three consecutive monthly intravitreal bevacizumab injections, no hemorrhages, pigment epithelial detachment, or decreased lipid content are visible on a red-free photograph. BCVA improved from 0.1 to 0.2 decimal visual acuity. **(G)** No leakage or pigment epithelial detachment are seen on fluorescein angiography. **(H and I)** Indocyanine green angiography shows decreased leakage from RAP lesions, but RCA and neovascular complex remain. **(J)** OCT showing disappearance of edema and pigment epithelial detachment. No additional treatment was performed. **(K)** Red-free photograph at month 6 shows recurrence of intraretinal and preretinal hemorrhages, edema, and pigment epithelial detachment. BCVA decreased from 0.2 to 0.1 decimal visual acuity at month 3. **(L)** Fluorescein angiography shows enlargement of leakage and pigment epithelial detachment. **(M)** Early-phase indocyanine green angiography shows enlargement of the neovascular complex and thickening of the RCA. **(N)** No hot spot was seen on late-phase indocyanine green angiography. **(O)** OCT shows severe edema and expansion of pigment epithelial detachment. We retreated with intravitreal bevacizumab plus photodynamic therapy instead of intravitreal bevacizumab. **(P)** Three months after intravitreal bevacizumab plus photodynamic therapy (month 9), a red-free photograph shows disappearance of intraretinal and preretinal hemorrhages, edema, and pigment epithelial detachment. **(Q and S)** Fluorescein and late-phase indocyanine green angiography showing no leakage. **(R)** Early-phase indocyanine green angiography showing complete disappearance of RCA. **(T)** Horizontal OCT image shows flattening of the neurosensory retina. BCVA was 0.2 decimal visual acuity.

of 2.29 and 2.13 lines, respectively. Two (40%) of the five eyes showed an increase in BCVA of three or more lines, and three (60%) eyes had stable visual acuity (defined as a loss of less than three lines of vision) at month 3.

There were no complications, such as inflammation, intraocular pressure > 21 mmHg, severe vision loss, endophthalmitis, progression of cataract, or systemic adverse events.

Discussion

In the current study, intravitreal bevacizumab monotherapy for RAP could not achieve complete occlusion of RRA and RCA.

Recurrence of the RAP lesion was also seen in a high percentage of cases. On the other hand, retreatment with intravitreal bevacizumab plus photodynamic therapy ultimately achieved complete occlusion of the RRA and RCA.

Although the natural history of RAP has been reported to be poor visual results,²² there has been no evidence for treatment of patients with RAP based on the major clinical trials. Most treatments, including conventional laser photocoagulation,²³ transpupillary thermotherapy,⁴ surgical ablation,⁷ and photodynamic therapy alone²⁴ have not been effective for patients with RAP until now.

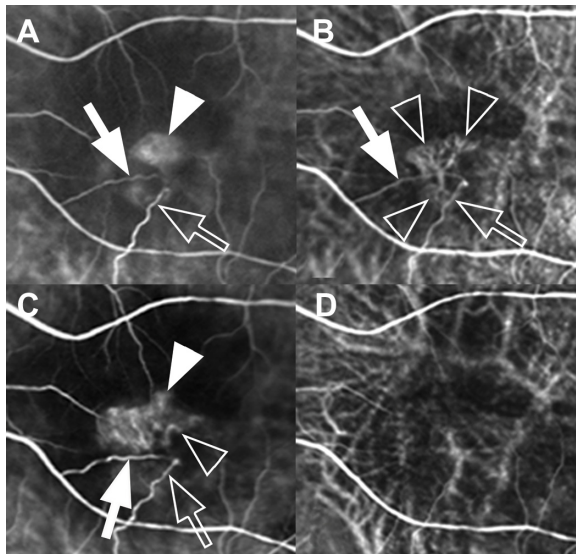


Figure 2 Magnification of early-phase indocyanine green angiography images from Figure 1 at baseline (A), and months 3 (B), 6 (C), and 9 (D). (A–C) This patient with stage 3 retinal angiomatous proliferation had proliferation within the retina (arrowheads) consisting of a preperfusion (arrows) and a draining (outline arrows) retinal vessel communicating with the area of choroidal neovascularization (outline arrowheads). (B and D) Although retinal-choroidal anastomosis (RCA) persisted after three consecutive monthly intravitreal bevacizumab injections, it finally resolved after combined therapy of intravitreal bevacizumab and photodynamic therapy.

Complete occlusion of RRA or RCA is important for reducing RAP lesions because of the high blood supply to these lesions. Surgical lysis of the feeding arterioles and draining venules to eliminate blood flow to RAP lesions can achieve temporary resolution of intraretinal edema and flattening of pigment epithelial detachment,⁶ but recurrence of exudation occurs with recanalization or new development of retinal feeding and draining vessels.⁷ In our study, disappearance of RRA and RCA by indocyanine green angiography could not be achieved in all eyes by month 3. On the other hand, retreatment consisting of intravitreal bevacizumab plus photodynamic therapy ultimately achieved complete occlusion of the RRA and RCA. We have reported in previous studies that intravitreal bevacizumab plus photodynamic therapy and combined intravitreal ranibizumab with photodynamic therapy can achieve complete occlusion of RRA in a high percentage of cases.^{17–19} From these results, a combination of an anti-VEGF agent and photodynamic therapy may be superior to anti-VEGF alone for reducing the high blood supply to RAP lesions.

In the current study, we also performed photodynamic therapy one or 2 days after intravitreal bevacizumab injection, as in our previous studies^{17,18} for the following reasons. Anti-VEGF therapy in patients with RAP can rapidly resolve the intraretinal edema, hemorrhage, and neovascular lesions in clinical treatment.^{18,19} Rapid neovascular complex

suppression in patients with RAP could be achieved after intravitreal anti-VEGF agents.^{18,19} We have hypothesized that verteporfin may accumulate minimally in a suppressed neovascular complex after injection of intravitreal anti-VEGF agents, and may be less effective.^{18,19}

The recommended treatment at present for age-related macular degeneration is ranibizumab, and bevacizumab is used off-label in these patients. Recently, CATT (the randomized Comparison of Age-Related Macular Degeneration Treatments Trials) showed that the effects of bevacizumab and ranibizumab on visual acuity at 24 months were equivalent.²⁵ Based on the results of the current study using bevacizumab monotherapy, we can infer the efficacy of ranibizumab monotherapy.

In animal models, overexpression of VEGF in the photoreceptors of the retina is sufficient to cause intraretinal and subretinal neovascularization,²⁶ which is similar to the neovascular process of RAP. Anti-VEGF monotherapy has been suggested on theoretical grounds. Recently, intravitreal anti-VEGF therapy using ranibizumab or bevacizumab has been reported to be useful for RAP.^{14,15} Gharbiya et al¹⁴ reported the efficacy of three monthly intravitreal bevacizumab injections in 17 eyes with RAP, which showed significant improvement in visual acuity from 39.53 letters on the ETDRS chart (decimal equivalent 0.48) to 47.88 letters (0.71) at month 12. Twelve (70.6%) of the 17 eyes required additional injections during the 12-month follow-up period. Hemeida et al¹⁵ reported 2-year results of anti-VEGF monotherapy using ranibizumab or bevacizumab for RAP. Repeat treatments were required in 75% of eyes and mean visual acuity at months 12, 18, and 24 showed no significant improvement. In addition, they concluded that anti-VEGF monotherapy might not be sufficient to maintain anatomical and functional improvement. In the current study, while the mean change in BCVA at month 3 was improvement of 2.13 lines, three (60%) of the five eyes showed persistent leakage on fluorescein angiography, cystoid macular edema, and pigment epithelial detachment on OCT at month 3. Most patients with anti-VEGF monotherapy need further injections during long-term follow up.

Figures 1 and 2 show an apparent difference in angiographic results between intravitreal bevacizumab monotherapy and intravitreal bevacizumab plus photodynamic therapy. Indocyanine green angiography shows clearly that the RCA remained in spite of the resolving exudative lesions seen on red-free or OCT images. Moreover, the neovascular complex was obviously enlarged when recurrence of exudation was present, which eventually caused a decline in visual acuity.

The poorer ability to achieve complete occlusion of the RRA or RCA using anti-VEGF agent monotherapy could be the main reason why more anti-VEGF injections were needed. On the other hand, the complete disappearance of RRA or RCA in a high percentage of cases after combined treatment using an anti-VEGF agent plus photodynamic therapy could reduce the number of treatments required, which may cause improvement or maintenance of visual acuity in the long term. Although two eyes in the current study showed minimal leakage on fluorescein angiography, cystoid macular edema, or pigment epithelial detachment at month 3, we continued to observe these patients because of their improving visual acuity and withdrawal of consent for retreatment. It might have been better if we had re-treated these patients with intravitreal bevacizumab plus photodynamic therapy, because they had persistent RRA, RCA, and a hot spot, and were therefore at high risk of recurrence. Because of the short follow-up durations involved, there was the potential for recurrence of the RAP lesion with RRA or RCA during further follow-up.

Conclusion

Although intravitreal bevacizumab for RAP was effective in improving visual acuity during short-term follow-up, it could not achieve complete occlusion of RRA and RCA, so there was a risk of recurrence of the RAP lesion and exudates. On the other hand, retreatment consisting of intravitreal bevacizumab plus photodynamic therapy ultimately achieved complete occlusion of RRA and RCA. Because this was a small study with a short follow-up duration, larger and longer-term prospective randomized studies are needed to determine the angiographic efficacy of RRA or RCA after anti-VEGF therapy with or without photodynamic therapy in patients with RAP.

Disclosure

The authors have no proprietary interest in any aspect of this study and received no government funding.

References

- Yannuzzi LA, Negrão S, Iida T, et al. Retinal angiomatous proliferation in age-related macular degeneration. *Retina*. 2001;21:416–434.
- Yannuzzi LA. Degeneration: age-related macular degeneration. In: *The Retinal Atlas*. Philadelphia, PA: Saunders; 2010.
- Hartnett ME, Weiter JJ, Staurengi G, et al. Deep retinal vascular anomalous complexes in advanced age-related macular degeneration. *Ophthalmology*. 1996;103:2042–2053.
- Bottoni F, Massaccesi A, Cigada M, et al. Treatment of retinal angiomatous proliferation in age-related macular degeneration: a series of 104 cases of retinal angiomatous proliferation. *Arch Ophthalmol*. 2005;123:1644–1650.
- Bressler NM. Retinal anastomosis to choroidal neovascularization: a bum rap for a difficult disease. *Arch Ophthalmol*. 2005;123:1741–1743.
- Borrillo JL, Sivalingam A, Martidis A, et al. Surgical ablation of retinal angiomatous proliferation. *Arch Ophthalmol*. 2003;121:558–561.
- Shiragami C, Iida T, Nagayama D, et al. Recurrence after surgical ablation for retinal angiomatous proliferation. *Retina*. 2007;27:198–203.
- Kvanta A, Algvare PV, Berglin L, et al. Subfoveal fibrovascular membranes in age-related macular degeneration express vascular endothelial growth factor. *Invest Ophthalmol Vis Sci*. 1996;37:1929–1934.
- Kliffen M, Sharma HS, Mooy CM, et al. Increased expression of angiogenic growth factors in age-related maculopathy. *Br J Ophthalmol*. 1997;81:154–162.
- Oh H, Takagi H, Takagi C. The potential angiogenic role of macrophages in the formation of choroidal neovascular membranes. *Invest Ophthalmol Vis Sci*. 1999;40:1891–1898.
- Rosenfeld PJ, Brown DM, Heier JS, et al; MARINA Study Group. Ranibizumab for neovascular age-related macular degeneration. *N Engl J Med*. 2006;355:1419–1431.
- Brown DM, Kaiser PK, Michels M, et al; ANCHOR Study Group. Ranibizumab versus verteporfin for neovascular age-related macular degeneration. *N Engl J Med*. 2006;355:1432–1444.
- Mitchell P, Korobelnik JF, Lanzetta P, et al. Ranibizumab (Lucentis) in neovascular age-related macular degeneration: evidence from clinical trials. *Br J Ophthalmol*. 2010;94:2–13.
- Gharbiya M, Allievi F, Recupero V, et al. Intravitreal bevacizumab as primary treatment for retinal angiomatous proliferation: twelve-month results. *Retina*. 2009;29:740–749.
- Hemeida TS, Keane PA, Dustin L, et al. Long-term visual and anatomical results following anti-VEGF monotherapy for retinal angiomatous proliferation. *Br J Ophthalmol*. 2010;94:701–705.
- Joeres S, Heussen FM, Treziak T, et al. Bevacizumab (Avastin) treatment in patients with retinal angiomatous proliferation. *Graefes Arch Clin Exp Ophthalmol*. 2007;245:1597–1602.
- Saito M, Shiragami C, Shiraga F, et al. Combined intravitreal bevacizumab and photodynamic therapy for retinal angiomatous proliferation. *Am J Ophthalmol*. 2008;146:935–941.
- Saito M, Shiragami C, Shiraga F, et al. Comparison of intravitreal triamcinolone acetonide with photodynamic therapy and intravitreal bevacizumab with photodynamic therapy for retinal angiomatous proliferation. *Am J Ophthalmol*. 2010;149:472–481.
- Saito M, Iida T, Kano M. Combined intravitreal ranibizumab and photodynamic therapy for retinal angiomatous proliferation. *Am J Ophthalmol*. 2012;153:504–514.
- Tano Y, Ohji M, Ishibashi T, et al. Re-treatment guideline of ranibizumab (genetical recombination) in the maintenance phase. *Nippon Ganka Gakkai Zasshi*. 2009;113:1098–1103. Japanese.
- Saito M, Iida T, Kano M. Intravitreal ranibizumab for exudative age-related macular degeneration with good baseline visual acuity. *Retina*. 2012;32:1250–1259.
- Viola F, Massaccesi A, Orzalesi N, et al. Retinal angiomatous proliferation: natural history and progression of visual loss. *Retina*. 2009;29:732–739.
- Slakter JS, Yannuzzi LA, Schneider U, et al. Retinal choroidal anastomoses and occult choroidal neovascularization in age-related macular degeneration. *Ophthalmology*. 2000;107:742–753.
- Boscia F, Furino C, Sborgia L, et al. Photodynamic therapy for retinal angiomatous proliferations and pigment epithelium detachment. *Am J Ophthalmol*. 2004;138:1077–1079.
- Martin DF, Maguire MG, Fine SL, et al; Comparison of Age-related Macular Degeneration Treatments Trials (CATT) Research Group. Ranibizumab and bevacizumab for treatment of neovascular age-related macular degeneration: two-year results. *Ophthalmology*. 2012;119:1388–1398.
- Okamoto N, Tobe T, Hackett SF, et al. Transgenic mice with increased expression of vascular endothelial growth factor in the retina: a new model of intraretinal and subretinal neovascularization. *Am J Pathol*. 1997;151:281–291.

Clinical Ophthalmology**Dovepress****Publish your work in this journal**

Clinical Ophthalmology is an international, peer-reviewed journal covering all subspecialties within ophthalmology. Key topics include: Optometry; Visual science; Pharmacology and drug therapy in eye diseases; Basic Sciences; Primary and Secondary eye care; Patient Safety and Quality of Care Improvements. This journal is indexed on

Submit your manuscript here: <http://www.dovepress.com/clinical-ophthalmology-journal>

PubMed Central and CAS, and is the official journal of The Society of Clinical Ophthalmology (SCO). The manuscript management system is completely online and includes a very quick and fair peer-review system, which is all easy to use. Visit <http://www.dovepress.com/testimonials.php> to read real quotes from published authors.