

Novel method of assessing delamination of the anterior lens capsule using spectral-domain optical coherence tomography

Deborah KL Tan¹
Tin Aung¹⁻³
Shamira A Perera^{1,2}

¹Singapore National Eye Centre, Singapore; ²Singapore Eye Research Institute, Singapore; ³National University of Singapore, Yong Loo Lin School of Medicine, Singapore

Background: Delamination of the anterior lens capsule producing a double-ring sign during continuous curvilinear capsulorhexis is commonly associated with true exfoliation syndrome.

Methods: Previous studies have concentrated on light- and transmission-electron microscopic features and correlated this with the histopathology of these anterior capsules. To our knowledge, this is the first report of the use of high-resolution spectral-domain optical coherence tomography to delineate delamination of the anterior lens capsule, incidentally detected during cataract surgery.

Keywords: anterior lens capsule, delamination, curvilinear capsulorhexis, exfoliation syndrome, high-resolution spectral-domain optical coherence tomography

Introduction

Delamination of the anterior lens capsule is a rare disorder whereby the lens capsule is thickened and most often presents as frank rolled-up splits in the superficial outer layer and with an intact deeper inner layer. Case series of splitting of the lens capsule with a double-ring sign seen at the capsular margins of a continuous curvilinear capsulorhexis during cataract surgery have been documented comprehensively in the literature.¹⁻⁷ We compare the novel use of high-resolution spectral-domain optical coherence tomography (SD-OCT) devices to delineate the split. This study was conducted in accordance with the tenets of the Declaration of Helsinki. Ethical approval was obtained from the Institutional Review Board of the Singapore Eye Research Institute.

Case report

A 75-year-old Chinese woman, diagnosed with primary angle-closure glaucoma and who was suspected to have bilateral nuclear sclerotic cataracts, underwent uncomplicated right laser peripheral iridotomy and a routine left phacoemulsification with intraocular lens implantation. She was reviewed regularly after the procedures and later expressed desire for her right cataract to be removed. Prior to her topical right temporal clear corneal phacoemulsification surgery, slit-lamp examination revealed a patent laser peripheral iridotomy and a normal anterior capsule.

Intraoperatively, a 5.5 mm diameter continuous curvilinear capsulorhexis was initiated and completed with Utrata capsulorhexis forceps (Bausch and Lomb, Tampa, FL; Storz Ophthalmics, St Louis, MO). Hydrodissection with a Rycroft cannula (Asico LLC, Westmont, IL) was attempted at multiple sites, but no fluid

Correspondence: Shamira Perera
Singapore National Eye Centre, 11 Third
Hospital Avenue 168751, Singapore
Tel +65 622 772 55
Fax +65 622 633 95
Email shamiraperera@hotmail.com

wave was observed. Nevertheless, a primary chop approach was attempted to cleave the nucleus in half. Only then was it noticed that there appeared to be a second anterior capsule under the first curvilinear capsulorhexis, which now had a large iatrogenic rent in it. In order to avoid radial extension of the rent, subsequent posterior capsule rupture, and a dropped nucleus, several rescue measures were employed. A can-opener capsulotomy was initiated on this deep leaflet to allow dismantling of the nucleus. Upon attaining a clearer view, this was converted to a ragged capsulorhexis.

The remaining nuclear fragments were removed by phacoemulsification, and the residual cortical material was removed by automated irrigation aspiration, avoiding tugging on any deep inner leaflet tags. An SA60AT intraocular lens (Alcon Laboratories Inc, Fort Worth, TX) was implanted in the bag and the absence of radial anterior capsule tears or posterior lens capsule rupture was confirmed. Postoperative recovery was uneventful, with a best-corrected visual acuity of 6/7.5 one month after surgery. The double ring of the capsule edge was visible on slit lamp examination through a dilated pupil (Figures 1A and 1B). A retrospective review of a DVD of her fellow eye cataract surgery revealed no splitting of the anterior capsule.

We obtained consecutive optical coherence tomography (OCT) scans of the patient's right eye under standardized dark room conditions, with a single experienced technician. The right eye was dilated with tropicamide 1% and horizontal meridional scans, centering on the pupil were captured. Spectral domain (SD)-OCT (Cirrus; Carl Zeiss Meditec, Dublin, CA) adapted with a 60-diopter aspheric lens (Volk Optical, Mentor, OH) mounted over the imaging

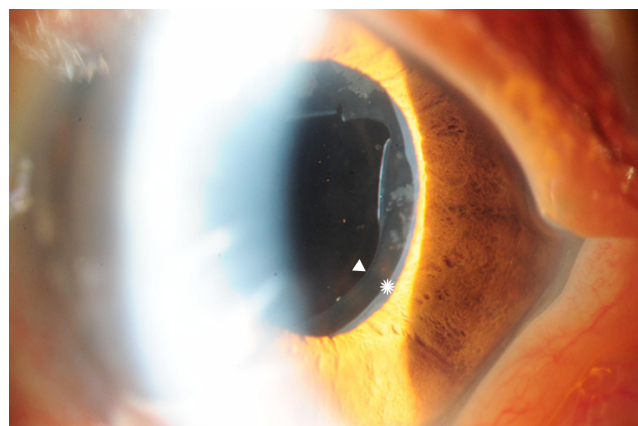


Figure 1A Double-ring sign seen at nasal edge of anterior lens capsule.
Note: Superficial outer (white asterisk) and deep inner (white arrowhead) layers seen most clearly at the nasal inferior edge of the anterior capsule.

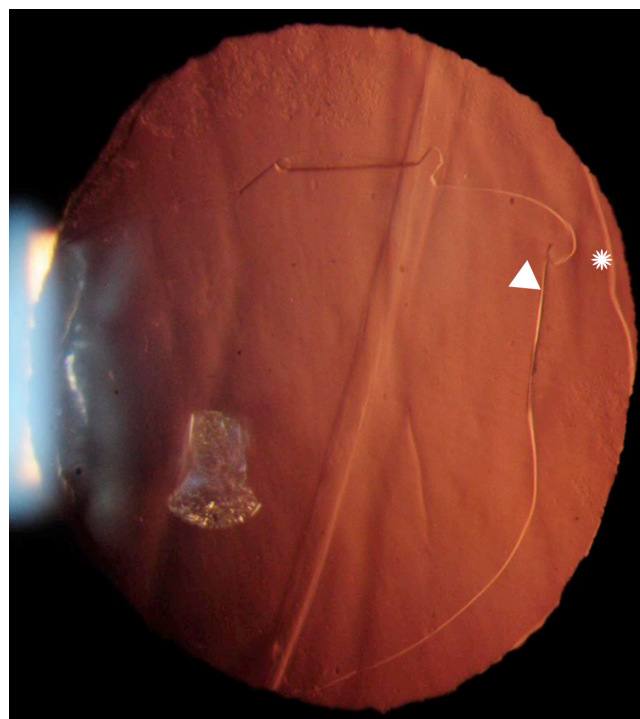


Figure 1B Photograph with transillumination showing the double-ring sign.
Note: White asterisk and arrowhead indicate double-ring sign.

aperture, demonstrated the split anterior lens capsule, which seemed to reconvene a few millimeters more peripherally. Notably it did not extend to the equator (Figure 2). Another SD-OCT device (RTVue; Optovue, Fremont, CA) and the time-domain anterior segment OCT (Visante; Carl Zeiss Meditec) could not clearly capture the superficial outer and deep inner leaflets of the anterior capsule (Figure 3) due to poor image quality or inadequate resolving power, respectively.




Figure 2 Cirrus SD-OCT image showing the superficial outer and deep inner layers of the anterior lens capsule reconvening within the optic zone of the PCIOL.
Note: White asterisk indicates the superficial outer layer of the anterior lens capsule; white arrowhead indicates deep inner layers of the anterior lens capsule.
Abbreviations: SD-OCT, spectral-domain optical coherence tomography; PCIOL, posterior chamber intraocular lens.

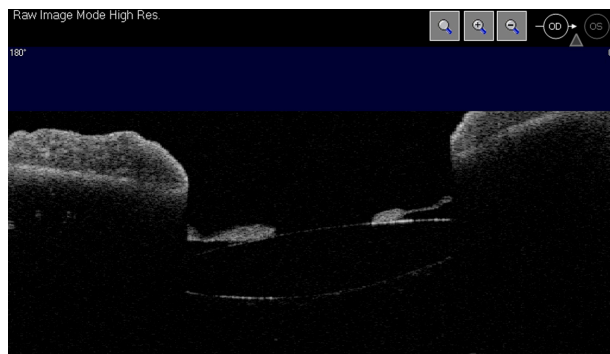


Figure 3 AS-OCT image is unable to show a split capsule in the patient's eye.
Abbreviation: AS-OCT, anterior segment optimal coherence technology.

Discussion

The axial and transverse resolution of the Visante for the anterior segment is 18 μm and 60 μm . This compares to both the superior Cirrus and RTVue with 5 μm and 15 μm respectively for posterior segment imaging. Their equivalent resolution when modified for the anterior segment is unknown. The differences in image quality between the two SD-OCTs are due to a number of factors. Firstly, an RTVue image uses 16 processed and averaged images, whereas the Cirrus uses a single-frame image. Secondly, they each have different proprietary methods of reducing signal-to-noise ratios.

Splitting of the anterior capsule is most commonly associated with true exfoliation syndrome, the cause of which is unknown. Most reported cases are bilateral^{3,4,6} and have been traditionally attributed to infrared radiation (glassblowing), inflammation, and ocular trauma. The theory is that heat from conversion of infrared radiation absorbed by the iris damages the underlying lens epithelium. This explains why exfoliation originates from the retroiridian lens capsule rather than the pupillary zone capsule.

Light microscopic examinations have displayed horizontal, surface-parallel, tangential splits in the middle layer of the outer one-third of the anterior capsule.^{1,2,4} It has been postulated that degenerated lens epithelial cells produce the abnormally thickened, stratified structure observed on electron microscopy.^{2,4} This supposedly weakens the adhesion between layers, causing horizontal, tangential, intracapsular splits to occur spontaneously.²

The splits captured in our image appeared to extend just a few millimeters beyond the approximate 5.5 mm capsulorhexis-rings, and not to the equator. This was despite vigorous attempts at hydrodissection between the leaflets which indicates strong adhesion more peripherally. These splits seem to originate preferentially in the outer one third of the capsule, at the border layer between the more superficial and thinner

zonular lamella, and the thicker capsule proper.¹ Propensity for delamination in this region may be exacerbated by laser peripheral iridotomy, which is usually performed in the peripheral third of the iris. In a similar case report by Abe et al,⁷ the patient had also undergone laser peripheral iridotomy in the same eye with the double-ring sign. As the splits were only present unilaterally in both our patients, we postulate that they were related to the argon-YAG laser peripheral iridotomies.

In cases with suspected or subclinical splits on imaging or frank splits in the anterior capsule, the size of the capsulorhexes should be enlarged beyond where the splitting originates. Alternatively, two concentric capsulorhexes may be torn before reaching the crystalline lens. This would have the added advantage of keeping the anterior capsule in continuous curvilinear capsulorhexis within the border of the intraocular lens optic.

Conclusions

In summary, this novel, high-definition method of assessing the anterior lens capsule using Cirrus SD-OCT may pave the way for more commonplace use of imaging in this realm in the future. In patients with pre-existing risk factors or frank anterior capsule splits in the fellow eye, preoperative Cirrus SD-OCT of the anterior lens capsule can detect subclinical delamination. This will help avoid a partial thickness capsulorhexis and its related surgical complications.

Acknowledgments

No financial support was received for this work.

Disclosures

TA and SAP have received honoraria from Carl Zeiss Meditec.

References

1. Wollensak G, Wollensak J. Double contour of the lens capsule edges after continuous curvilinear capsulorhexis. *Graefes Arch Clin Exp Ophthalmol*. 1997;235(4):204–207.
2. Ataka S, Kohno T, Kurita K, Wada S, Takahashi Y, Shiraki K. Histopathological study of the anterior lens capsule with a double-ring sign. *Graefes Arch Clin Exp Ophthalmol*. 2004;242(3):245–249.
3. Cashwell LF Jr, Holleman IL, Weaver RG, van Rens GH. Idiopathic true exfoliation of the lens capsule. *Ophthalmology*. 1989;96(3):348–351.
4. Karp CL, Fazio JR, Culbertson WW, Green WR. True exfoliation of the lens capsule. *Arch Ophthalmol*. 1999;117:1078–1080.
5. Braude LS, Edward DP. Partial splitting of the anterior lens capsule giving a 'double-ring' sign. *Arch Ophthalmol*. 1995;113(6):705–706.
6. Kulkarni AR, Al-Ibrahim J, Haider S, Elsherbiny S, Scott R. Phacoemulsification in true exfoliation of the lens capsule: a case series. *Eye*. 2007;21(6):835–837.
7. Abe T, Hirata H, Hayasaka S. Double-ring and double-layer sign of the anterior lens capsule during cataract surgery. *Jpn J Ophthalmol*. 2001;45(6):657–658.

Clinical Ophthalmology**Dovepress****Publish your work in this journal**

Clinical Ophthalmology is an international, peer-reviewed journal covering all subspecialties within ophthalmology. Key topics include: Optometry; Visual science; Pharmacology and drug therapy in eye diseases; Basic Sciences; Primary and Secondary eye care; Patient Safety and Quality of Care Improvements. This journal is indexed on

Submit your manuscript here: <http://www.dovepress.com/clinical-ophthalmology-journal>

PubMed Central and CAS, and is the official journal of The Society of Clinical Ophthalmology (SCO). The manuscript management system is completely online and includes a very quick and fair peer-review system, which is all easy to use. Visit <http://www.dovepress.com/testimonials.php> to read real quotes from published authors.